
MR Imaging in a Case of Postvaccination Myelitis

Lisa M. Tartaglino, Terry Heiman-Patterson, David P. Friedman, and Adam E. Flanders

Summary: We describe a case of acute transverse myelitis after the administration of the recombinant form of hepatitis B vaccine. Abnormal enhancement on MR imaging accompanied residual neurologic deficit.

Index terms: Myelitis; Drugs, reaction

Acute transverse myelitis is an inflammatory disorder of the spinal cord associated with many disease processes. The pathogenesis is unclear, but the probable mechanism involves an autoimmune phenomenon (1). Myelitis has rarely been reported secondary to vaccinations, including rabies (2), smallpox (3), influenza (4), rubella (5), and the plasma-derived form of hepatitis B (6). We present a case of acute transverse myelitis, which seems secondary to the administration of the recombinant form of hepatitis B vaccine. The magnetic resonance (MR) findings are described and correlated with the residual neurologic deficit.

Case Report

A 40-year-old male health care worker presented with a 6-week history of progressive lower-extremity numbness and difficulty walking. Symptoms began 2 weeks after receiving the first dose of the recombinant form of hepatitis B vaccine. After administration of the second dose, 1 month later, the sensory disturbance ascended to the nipple level, and the patient had difficulty walking. Physical examination revealed markedly impaired proprioception and vibration sense, minimal weakness, hyporeflexia in the lower extremities, and a T-4 sensory level.

MR was performed at admission on a 1.5-T magnet. T1-weighted (500/11/4 [repetition time/echo time/excitations]) and T2-weighted (2000/30,80/2) spin-echo pulse sequences revealed a swollen edematous cord extending from C-3 to T-9. On T1-weighted images there was diffuse hypointense signal relative to the spinal cord, whereas on T2-weighted images there was diffuse increased signal in the same regions. Postgadolinium images showed exten-

sive enhancement isolated to the posterior columns from C-6 to T-8 (Fig 1A-D). His residual deficit consists of moderate posterior column dysfunction corresponding to the area of gadolinium enhancement.

Discussion

Neurologic complications after vaccination are well known but rare. They include seizures, Guillain-Barré syndrome, peripheral neuropathy, cranial nerve palsies, transverse myelitis, and encephalopathy (2, 3, 4, 6). In this case of transverse myelitis, although pathologic proof is not possible, the striking temporal relationship between symptoms and the two doses of hepatitis B vaccine strongly suggests that the vaccine was the cause.

The MR findings in postvaccination transverse myelitis have not been described but are probably similar to those changes seen secondary to transverse myelitis of other causes. MR findings described in acute transverse myelitis include cord expansion (7), increased signal on T2-weighted images (7, 8), and an enhancement pattern that can be normal, diffuse, peripheral, or slightly nodular (8). T1-weighted images are usually of normal or slightly increased signal intensity, possibly secondary to petechial hemorrhages, although decreased signal has been described (8). In our case, diffuse hypointense signal on T1-weighted images and diffuse hyperintense signal on T2-weighted images was seen throughout the cord from C-3 to T-9, as well as diffuse cord swelling. The abnormal enhancement was localized to the posterior columns, and this corresponded to his predominant and persistent deficit. A previous report also showed a relationship between location of enhancement and persistent deficit (9). In another instance, progressive decrease in en-

Received January 15, 1993; accepted after revision May 18.

From the Departments of Radiology (L.M.T., D.P.F., A.E.F.) and Neurology (T.H.-P.), Jefferson Medical College and Thomas Jefferson University Hospital, Philadelphia, Pa.

Address reprint requests to L. M. Tartaglino, Department of Radiology, Jefferson Medical College and Thomas Jefferson University Hospital, 10th and Sansom Streets, Room 1072, Main Building, Philadelphia, PA 19107.


AJNR 16:581-582, Mar 1995 0195-6108/95/1603-0581 © American Society of Neuroradiology

Fig 1. A, Sagittal T1-weighted contrast-enhanced image shows a swollen cord with homogeneous enhancement confined to the posterior aspect of the spinal cord beginning at the level of C-5 to C-6. More caudal images (not shown) showed abnormal enhancement extending to the level of T-8.

B, Axial T1-weighted image before contrast administration at the level of T-3 confirms the swollen edematous cord.

C, Axial T1-weighted contrast-enhanced image at the same level as B demonstrates that the posterior enhancement appears isolated to the posterior columns (arrow).

D, Sagittal T2-weighted image reveals hyperintense signal extending from the level of C-3 to C-4 inferiorly. This abnormal signal extends beyond the area of enhancement and is consistent with edema.



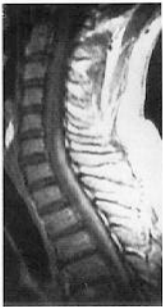hancement corresponded to clinical improvement (8). A larger series would be required to determine whether enhancement characteristics or temporal changes are predictive of residual deficit. It is possible that the MR appearance may have been different in our patient had he been imaged more acutely. It is not known whether posterior column enhancement and/or white matter tract involvement is a characteristic of postvaccination myelitis or a unique finding in this patient.

Currently, the recombinant form of hepatitis B vaccine may be given to people at high risk for exposure, as well as to certain people who have been acutely exposed. Hepatitis B vaccine has obvious benefits outweighing the possible rare complications. However, although associated severe neurologic complications are extremely rare, they may be underreported, because there is usually a delay in symptom occurrence, and an idiopathic or postviral cause of symptoms would be difficult to disprove. The administration of the recombinant form of hepatitis B vaccine usually consists of multiple doses. Although it is impossible to identify those who may eventually develop neurologic com-

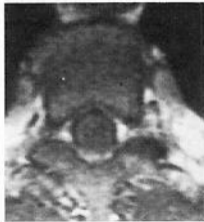plications, it is important to identify early signs of an untoward reaction. If, as in our patient, symptoms occur after the initial dose, administration of further doses should be carefully considered.

References

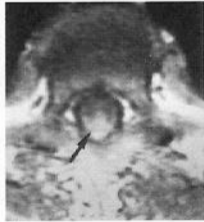1. Abramsky O, Teitelbaum D. The autoimmune features of acute transverse myelopathy. *Ann Neurol* 1977;2:36-40
2. Appelbaum E, Greenberg M, Nelson J. Neurological complications following antirabies vaccination. *JAMA* 1953;151:188-191
3. Spillane JD, Wells CEC. The neurology of jennerian vaccination. *Brain* 1964;87:1-48
4. Poser CM. Neurological complications of swine influenza vaccination. *Acta Neurol Scand* 1982;66:413-431
5. Holt S, Hudgins D, Krishnan KR, Critchley EMR. Diffuse myelitis associated with rubella vaccination. *Br Med J* 1976;2:1037-1038
6. Shaw FE, Graham DJ, Guess HA, et al. Postmarketing surveillance for neurologic adverse events reported after hepatitis B vaccination. *Am J Epidemiol* 1988;127:337-352
7. Barakos JA, Mark EW, Dillon WP, Norman D. MR imaging of acute transverse myelitis and AIDS myelopathy. *J Comput Assist Tomogr* 1990;14:45-50
8. Gero B, Sze G, Sharif H. MR imaging of intradural inflammatory diseases of the spine. *AJNR Am J Neuroradiol* 1991;12:1009-1019
9. Sanders KA, Khandji AG, Mohr JP. Gadolinium-MRI in acute transverse myelopathy. *Neurology* 1990;40:1614-1616



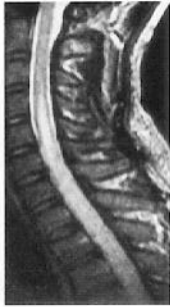A



B



C



D