
Serial Positron Emission Tomography with Fludeoxyglucose F 18 in Creutzfeldt-Jakob Disease

Toshihide Ogawa, Atsushi Inugami, Hideaki Fujita, Jun Hatazawa, Eku Shimosegawa, Iwao Kanno, Toshio Okudera, Kazuo Uemura, and Ken Nagata

Summary: We serially examined a patient with Creutzfeldt-Jakob disease using fludeoxyglucose F 18 and positron emission tomography. Marked cerebral hypometabolism reflected clinical deterioration in the early stages of Creutzfeldt-Jakob disease when no parenchymal abnormalities were present on MR imaging.

Index terms: Dementia; Positron emission tomography

Creutzfeldt-Jakob disease is a fatal and transmissible disease with no effective therapy (1). Therefore, it is important to make an early diagnosis for preventing person-to-person transmission. Computed tomography (CT) and magnetic resonance (MR) imaging have not shown any specific findings for Creutzfeldt-Jakob disease (2–8). We serially examined a patient with histologically verified Creutzfeldt-Jakob disease by fludeoxyglucose F 18 (FDG) and positron emission tomography (PET). These findings are compared with those present on CT and MR imaging at similar stages of the disease.

Case Report

This 59-year-old woman had a 3-week history of progressive numbness of the right extremities. When admitted to our hospital in early September 1990, she was alert and well oriented and free of neurologic deficit except for deep sensory disturbance of the right extremities. CT scan of the brain was normal. Soon after admission, a disturbance in proprioception in the right extremities developed. In early October, she exhibited a rapid mental deterioration and disturbance in general performance including motor aphasia, dementia, and spasticity. The first electroencephalo-

gram (EEG), obtained 1 month after admission, revealed a marked slowing of the background activity mainly in the left cerebral hemisphere.

CT scan obtained in October 1990 showed mild brain atrophy (Fig 1A). MR imaging obtained 3 days after the CT scan also revealed mild brain atrophy (Fig 1B). FDG PET obtained 1 day after the MR study showed left cerebral hypometabolism (Fig 1C). The cerebral metabolic rate for glucose was assessed by the FDG method of Phelps et al (9). Cerebral metabolic rate for glucose was calculated using fixed rate constants of healthy volunteers and a lumped constant of 0.52 (10). Cerebral metabolic rate for glucose of the left cerebral cortices was decreased to 52% of the normal value (11) (Table). The reduction of cerebral metabolic rate for glucose in the right cerebral cortices was 65%. Cerebral metabolic rate for glucose measurement of cerebellum, brain stem, basal ganglia, and white matter were only slightly decreased. Follow-up EEG recordings showed periodic synchronous discharge suggestive of Creutzfeldt-Jakob disease.

In early November 1990 quadriplegia and myoclonic jerks developed. The follow-up FDG PET (Fig 1D) obtained in January 1991 showed a remarkable decrease of cerebral metabolic rate for glucose in the whole brain without showing the asymmetry observed in the first FDG PET. Cerebral metabolic rate for glucose of cerebral cortices and subcortical gray matter were decreased to about 30% of normal values (Table). CT scan obtained on the same day as the FDG PET showed marked progress of diffuse brain atrophy (Fig 1E).

The patient died of respiratory disturbance in April 1991. At autopsy, pronounced, diffuse atrophy of the cerebral cortex and subcortical gray matter and marked ventricular dilatation were observed. In addition to severe cortical neuronal loss and astrocytic hyperplasia and hypertrophy, spongiform changes were evident in the deeper layers of the cerebral cortex, especially in the occipital lobes.

Received June 2, 1993; accepted after revision December 31.

Presented at the 31st Annual Meeting of the American Society of Neuroradiology, Vancouver, British Columbia, Canada.

From the Departments of Radiology and Nuclear Medicine (T.O., A.I., H.F., J.H., E.S., I.K., T.O., K.U.) and Neurology (K.N.), Research Institute of Brain and Blood Vessels-Akita, Akita city, Japan.

Address reprint requests to Toshihide Ogawa, MD, Department of Radiology and Nuclear Medicine, Research Institute of Brain and Blood Vessels-Akita, 6-10, Senshu-Kubota-machi, Akita city, Akita, Japan.

AJNR 16:978-981, Apr 1995 0195-6108/95/1604-0978 © American Society of Neuroradiology

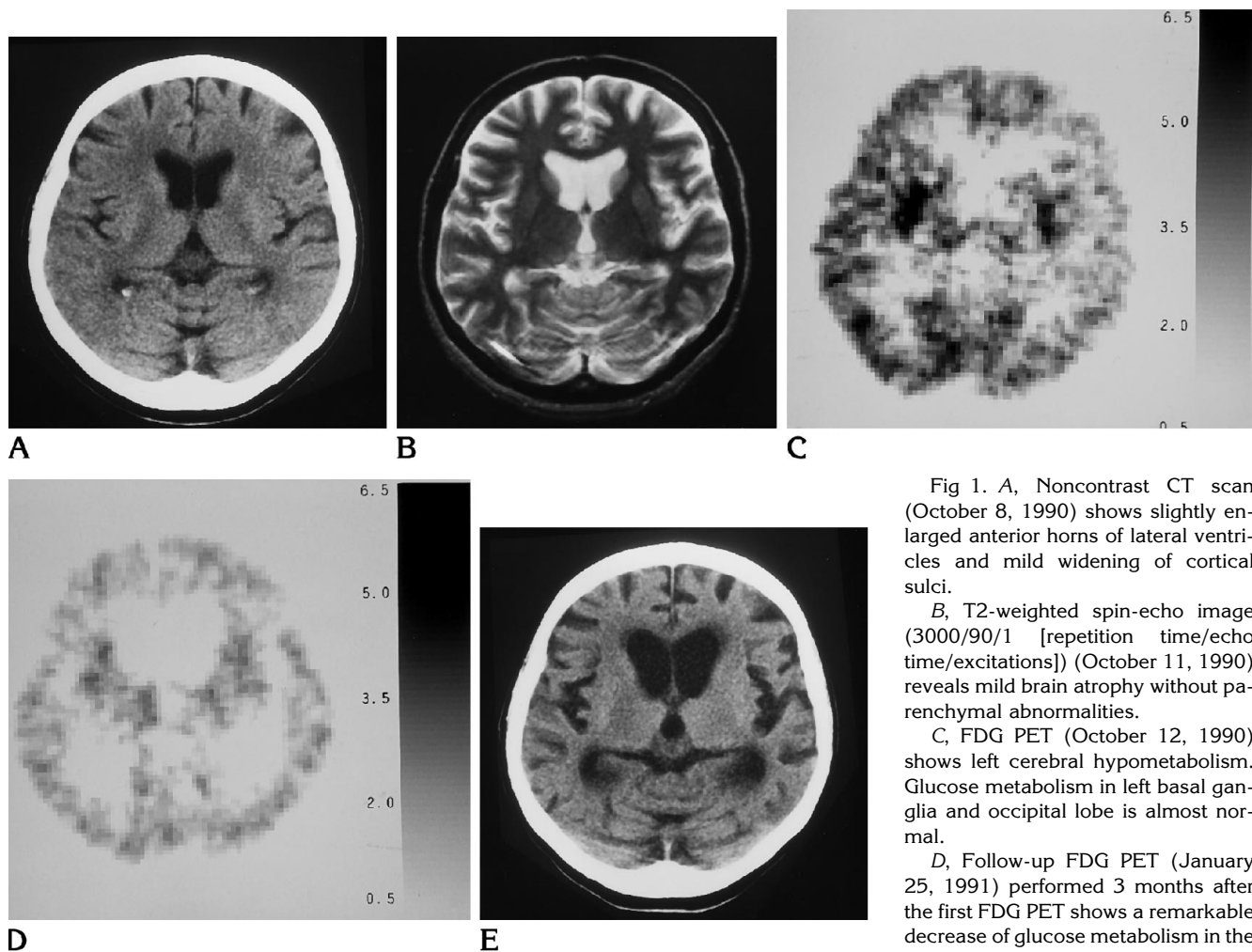


Fig 1. A, Noncontrast CT scan (October 8, 1990) shows slightly enlarged anterior horns of lateral ventricles and mild widening of cortical sulci.

B, T2-weighted spin-echo image (3000/90/1 [repetition time/echo time/excitations]) (October 11, 1990) reveals mild brain atrophy without parenchymal abnormalities.

C, FDG PET (October 12, 1990) shows left cerebral hypometabolism. Glucose metabolism in left basal ganglia and occipital lobe is almost normal.

D, Follow-up FDG PET (January 25, 1991) performed 3 months after the first FDG PET shows a remarkable decrease of glucose metabolism in the whole brain.

E, Follow-up noncontrast CT scan performed on the same day as the FDG PET (D) shows marked progression of ventricular enlargement and diffuse widening of cortical sulci compared with that seen in A.

Discussion

The definite diagnosis of Creutzfeldt-Jakob disease is based on histopathologic findings. In general, Creutzfeldt-Jakob disease is diagnosed clinically from its symptoms and course showing a rapidly progressive dementia associated with upper motor neuron dysfunction and myoclonus (1). Characteristic EEG changes, such as periodic synchronous discharge, help make the diagnosis despite nonspecific findings for this disease (1). Neuroimaging studies have provided supporting information for the diagnosis. Although Falcone et al reported a case that showed focal abnormalities on CT scan (8), CT scan usually did not show any abnormalities except for brain atrophy (3-5). Therefore, CT scan has been used to exclude focal lesions as a cause of the patient's symptoms.

There are several reports that MR imaging was more sensitive than CT scan in detecting cortical atrophy and pathologic changes (6-8). Some reports did not show any abnormalities in the cerebral cortex except for brain atrophy in patients with Creutzfeldt-Jakob disease on MR imaging in the early stages of the disease (7, 12). In our patient, only mild brain atrophy was observed in the early stage of Creutzfeldt-Jakob disease. Others reported that T2-weighted MR images displayed focal abnormal hyperintensity in the cerebral cortices and subcortical gray matter (6, 8). However, most of the abnormalities on MR were seen in the late stages of Creutzfeldt-Jakob disease. Falcone et al reported that symmetric hyperintensity of both occipital lobes without cerebral atrophy was observed on T2-weighted image in the early stage

Cerebral metabolic rate for glucose (CMRGlu) changes in each region on serial FDG PET studies

Regions	First PET CMRGlu, mg/100 mL/min		Second PET CMRGlu, mg/100 mL/min		Normal CMRGlu (9), (mg/100 mL/min)
	Right Hemisphere	Left Hemisphere	Right Hemisphere	Left Hemisphere	
Frontal	3.9 (61)	3.0 (47)	1.8 (28)	1.9 (30)	6.4
Temporal	4.2 (66)	3.3 (52)	1.9 (30)	1.8 (28)	6.4
Parietal	3.3 (51)	2.4 (37)	2.1 (32)	2.2 (34)	6.5
Occipital	5.7 (79)	4.8 (67)	2.3 (32)	2.5 (35)	7.2
Basal ganglia	5.7 (90)	4.7 (75)	2.6 (41)	2.5 (40)	6.3
Thalamus	4.1 (68)	3.7 (62)	2.6 (43)	2.3 (38)	6.0
Oval center	2.4 (75)	2.0 (63)	1.5 (47)	1.3 (41)	3.2
Cerebellum	3.5 (69)	3.6 (71)	2.7 (53)	2.6 (51)	5.1
Brain stem	3.4 (100)		2.2 (65)		3.4
Mean cortex	4.3 (65)	3.4 (52)	2.0 (30)	2.1 (32)	6.6

Note.—Numbers in parentheses indicate percent of normal value in each region.

(8). On the basis of the histopathologic findings, they stated that the hyperintense changes in the cortical gray matter probably reflected areas of gliosis and microvacuolation rather than areas of edema and inflammatory cell infiltration.

A few reports refer to cerebral blood flow and metabolism in Creutzfeldt-Jakob disease (12–14). Friedland et al reported that temporal lobe hypometabolism with hemispheric asymmetry was observed on FDG PET, although CT and MR imaging were negative (13). Shishido et al quantitatively evaluated glucose metabolism in a patient with Creutzfeldt-Jakob disease using FDG PET. They observed a decrease of glucose metabolism in cerebral cortices to about 45% of the normal value when CT scan revealed minimal brain atrophy (14). Glucose metabolism in the corpus striatum, cerebellum, brain stem, and white matter was preserved in the early stages.

In our study, left cerebral hypometabolism reflected the patient's neurologic findings. This left cerebral hypometabolism is based on the varied pathologic presentations. Cerebral metabolic rate for glucose in white matter was preserved in the early stage of this disease. Because gray matter is most affected microscopically, preservation of glucose metabolism in the white matter corresponds to the pathologic changes. Shih et al reported a case of Creutzfeldt-Jakob disease studied by [^{123}I]HIPDM brain imaging (12). They observed decreased perfusion in the left frontal and left temporoparietal cortices. Functional studies such as PET and single-photon emission CT provide biophysiological information such as blood flow and metabolism. However, one must remember that diffuse hypoperfusion and hypo-

metabolism may be overlooked if a quantitative measurement is not taken.

In Creutzfeldt-Jakob disease, the hypometabolism on FDG PET can be easily interpreted as a reflection of severe cortical neuronal loss on pathologic specimens. The most important differential diagnosis of hypometabolic regions on FDG PET is Alzheimer disease. It initially was shown that temporoparietal hypometabolism with no significant interhemispheric metabolic differences was characteristic for Alzheimer disease (15). Although temporoparietal hypometabolism is the most common metabolic pattern in Alzheimer disease, it has been shown later that brain metabolic patterns in patients with Alzheimer disease are heterogeneous, belonging to at least four distinct metabolic groups that correspond to different patterns of cognitive and behavioral abnormalities (16). Therefore, it is difficult to differentiate Creutzfeldt-Jakob disease from Alzheimer disease by FDG PET (13). However, we believe that in a patient with a rapidly progressive dementia, hypometabolism on FDG PET compatible with a clinical deterioration should suggest the diagnosis of Creutzfeldt-Jakob disease.

In conclusion, this case illustrates the fact that in Creutzfeldt-Jakob disease, FDG PET may enable detection of physiologic abnormalities before the appearance of morphological abnormalities demonstrated by CT and MR imaging.

References

1. Brown P, Cathala F, Castaigne P, Gajdusek DC. Creutzfeldt-Jakob disease: clinical analysis of a consecutive series of 230 neuropathologically verified cases. *Ann Neurol* 1986;20:597–602

2. Gálvez S, Cartier L. Computed tomography findings in 15 cases of Creutzfeldt-Jakob disease with histological verification. *J Neurol Neurosurg Psychiatry* 1984;47:1244-1246
3. Westphal KP, Schachenmayr W. Computed tomography during Creutzfeldt-Jakob disease. *Neuroradiology* 1985;27:362-364
4. Schlenska GK, Walter GF. Serial computed tomography findings in Creutzfeldt-Jakob disease. *Neuroradiology* 1989;31:303-306
5. Kovanen J, Erkinjuntti T, Iivanainen M, et al. Cerebral MR and CT imaging in Creutzfeldt-Jakob disease. *J Comput Assist Tomogr* 1985;9:125-128
6. Gertz HJ, Henkes H, Cervos-Navarro J. Creutzfeldt-Jakob disease: correlation of MRI and neuropathologic findings. *Neurology* 1988;38:1481-1482
7. Uchino A, Yoshinaga M, Shiokawa O, Hata H, Ohno M. Serial MR imaging in Creutzfeldt-Jakob disease. *Neuroradiology* 1991;33:364-367
8. Falcone S, Quencer RM, Bowen B, Bruce JH, Naidich TP. Creutzfeldt-Jakob disease: focal symmetrical cortical involvement demonstrated by MR imaging. *AJNR Am J Neuroradiol* 1991;13:403-406
9. Phelps ME, Huang SC, Hoffman EJ, Selin C, Sokoloff L, Kuhl DE. Tomographic measurement of local cerebral glucose metabolic rate in humans with (F-18)2-fluoro-2-deoxy-D-glucose: validation of method. *Ann Neurol* 1979;6:371-388
10. Reivich M, Alavi A, Wolf A, et al. Glucose metabolic rate kinetic model parameter determination in humans: the lumped constants and rate constants for [¹⁸F]fluorodeoxyglucose and [¹¹C]deoxyglucose. *J Cereb Blood Flow Metab* 1985;5:179-192
11. Sasaki H, Kanno I, Murakami M, Shishido F, Uemura K. Tomographic mapping of kinetic rate constants in the fluorodeoxyglucose model using dynamic positron emission tomography. *J Cereb Blood Flow Metab* 1986;6:447-454
12. Shih WJ, Markesbery WR, Clark DB, et al. Iodine-123 HIPDM brain imaging findings in subacute spongiform encephalopathy (Creutzfeldt-Jakob disease). *J Nucl Med* 1987;28:1484-1487
13. Friedland RP, Prusiner SB, Jagust WJ, Budinger TF, Davis RL. Bitemporal hypometabolism in Creutzfeldt-Jakob disease measured by positron emission tomography with [¹⁸F]-2-fluorodeoxyglucose. *J Comput Assist Tomogr* 1984;8:978-981
14. Shishido F, Uemura K, Inugami A, et al. Brain glucose metabolism in a patient with Creutzfeldt-Jakob disease measured by positron emission tomography. *Jpn J Nucl Med* 1990;27:649-654
15. Friedland RP, Budinger TF, Ganz E, et al. Regional cerebral metabolic alterations in dementia of the Alzheimer type: positron emission tomography with [¹⁸F]fluorodeoxyglucose. *J Comput Assist Tomogr* 1983;7:590-597
16. Rapoport SI. Positron emission tomography in Alzheimer's disease in relation to disease pathogenesis: a critical review. *Cerebrovascular and Brain Metabolism Reviews* 1991;3:297-335