
Sciatic Endometriosis: MR Evaluation

Jean-Philippe Cottier, Philippe Descamps, Catherine B. Sonier, and Philippe Rosset

Summary: We report a case of sciatic nerve involvement with a hemorrhagic lesion of endometriosis, as demonstrated by MR.

Index terms: Nerves, sciatic; Pelvis; Spine, magnetic resonance

Endometriosis is a rare cause of sciatica. Since the case of endometriosis-induced sciatica reported by Schlicke in 1946 (1), 18 other histologically proved observations have been reported. In 4 of them (2–5) computed tomography (CT) of the pelvis revealed a lesion on the sciatic nerve.

Case Report

A 39-year-old woman (gravida 1, para 1) was referred for episodic pain in her back and left leg associated with difficulties in walking. Clinical history revealed cyclic sciatica that had evolved for longer than 3 years. Pain began on the first day of menstruation and continued for the 5 or 6 days of menstruation and recurred during the following cycle after a pain-free period.

On examination, she walked with left steppage gait. There was paralysis of the peroneal muscles of the left leg associated with hypesthesia in the L-5 area. Achilles reflex of the left foot was not present. Electromyography confirmed damage to the peroneal nerve, with slight damage to the tibial nerve. Sciatica was suspected, and pelvic MR revealed a distinct mass of approximately 2 cm in diameter in the left sciatic notch (Fig 1).

The lesion was situated in the lower part of the piriform muscle, in contact with the sciatic nerve in the gluteal area. The lesion was hyperintense on the T1- and T2-weighted images, partially surrounded by a thin hypointense zone (Fig 1 A, B). The lesion did not enhance after gadolinium injection (Fig 1 C).

Because of the nerve symptoms and the topography of the lesion, our preoperative diagnosis was an atypical neurogenic tumor with a cystic or hemorrhagic content. Surgery revealed a purplish mass, which was situated within the piriform muscle, and extended below and outside in contact with the sciatic nerve. The whole region was inflamed. Section of the tumor released a chocolate color fluid.

Preliminary examination indicated the diagnosis of endometriosis. The cyst was excised, and neurolysis of the sciatic nerve was performed. Pathology examination (Fig 2) revealed areas of typical endometrial glands surrounded by stroma and bordered by vessels with occasional foci of hemosiderin-laden macrophages typical of endometriosis.

Discussion

Endometriosis is defined by the presence of ectopic islets of endometrial tissue. It is a very common gynecologic disease affecting between 1% and 5% of women of reproductive age (6), but its true frequency is difficult to estimate because in many cases there is no parallel between anatomic lesions and clinical features. The location of endometrial nodes at the root of a nerve or in the nerve itself is one of the rarest topographic variations of this condition. The existence of a peritoneal diverticulum permitting endometrial tissue to migrate to the sciatic nerve from the site of genital endometriosis or after retrograde menstruation through the fallopian tubes has been suggested (7), but this "pocket sign" rarely is observed during pelvic examination. Hematologic migration after vascular damage such as a slight injury or surgery also could be the cause, especially in patients without other sites of endometriosis. Because endometriosis is hormone-dependent, the hemorrhage penetrates neighboring tissues during each menstrual cycle and triggers a considerable inflammatory reaction. The sciatica is cyclical and occurs during menstrual periods sometimes beginning 1 to 2 days before or after the first day of a period. The pain is intense and progressive, with a pain-free interval that gradually shortens until, after a few years, it becomes permanent. Although in one case (9), pain disappeared during pregnancy (which is classic of all endometriosis symptoms), in all

Received June 9, 1994; accepted after revision November 14.

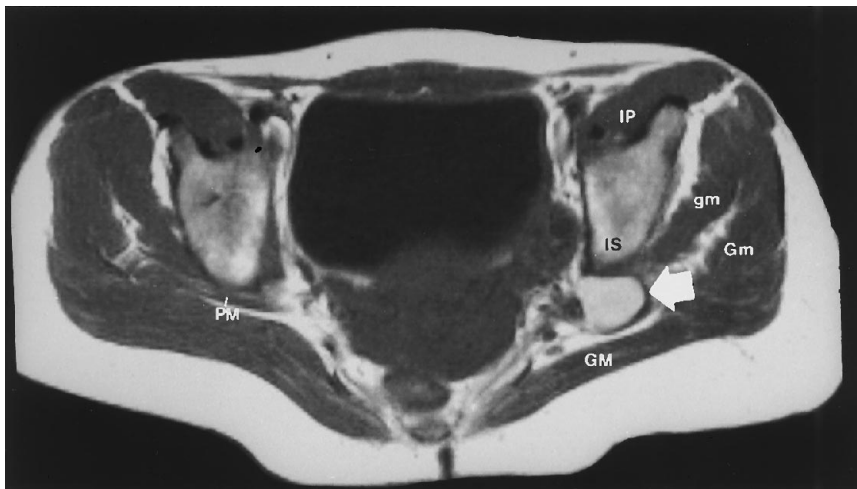From the Departments of Neuroradiology (J.P.C., C.B.S.), Obstetrics and Gynecology (P.D.), and Orthopedics (P.R.), University Hospital, Tours, France.

Address reprint requests to J. P. Cottier, service de neuroradiologie, (Pr J LAFFONT) Hopital bretonneau, 2 boulevard Tonnellé, 37044 Tours, France.

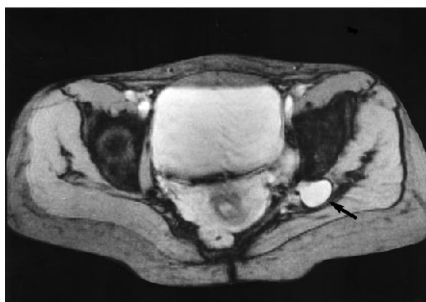Fig 1. A, Axial T1-weighted image (540/10/2 [repetition time/echo time/excitations], 240×256 matrix) shows a hyperintense lesion (arrow) in the left sciatic notch, partially surrounded by a thin hypointense zone (which represents granular tissue composed of macrophages filled with hemosiderin and determined on pathologic analysis). PM indicates piriformis muscle; GM, gluteus maximus muscle; Gm, gluteus medius muscle; gm, gluteus minimus muscle; IP, ilio-psoas muscle; and IS, ischial spine.

B, On the gradient-echo axial T2-weighted image (400/18/15, 4° fly angle, 240×256 matrix), the lesion (arrow) is hyperintense and is surrounded by a thin hypointense zone.

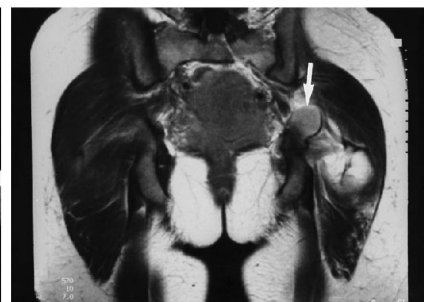C, Coronal T1-weighted image after gadolinium administration (540/10/2, 240×256 matrix) does not display enhancement of the lesion (arrow).



A



B



C

other published cases, it had no effect on the sciatic pain (2). There is a clear predominance of sciatic pain on the right side (8).

It has been suggested that the sigmoid impedes the implantation of endometriosis nodes on the left sciatic nerve. Sensorimotor deficit can appear. Such progressive sensory motor deficit is sometimes the only manifestation of sciatic nerve involvement.

In different pelvic locations, endometriosis presents different appearances on CT scan: cystic, solid, or mixed. There have been some reports of CT scans of endometriosis-induced sciatica (2-5). The sensitivity and specificity of this technique in the diagnosis of endometriosis in usual pelvic locations (ovaries and uterus) are estimated to be around 70% (10, 11). These cystic lesions typically are surrounded by an hypointense rim on T1- and T2-weighted images related to their fibrous capsule (12). Classically, the interior of the cyst is hyperintense in T1- and T2-weighted images because of the presence of paramagnetic methemoglobin. There can be other types of signal (10, 11), and the intensity of the signal is a function of the

quantity and age of the hemorrhage on the one hand and of the proportion of endometrial cells and stroma on the other hand. In our case, the lesion presented hyperintensity on both sequences and no enhancement related to its hematic content and a peripheral hypointensity, which was linked to the presence of granular tissue composed of macrophages filled with hemosiderin.

In view of the nerve symptoms and the topography of the lesion, the principal differential diagnosis is benign neurogenic tumor. On MR (13) neurinoma and neurofibroma are hypointense on T1-weighted images and heterogeneously hyperintense on T2-weighted images (with a central zone of low intensity for neurofibromas). These tumors enhance after gadolinium injection. In the few observations of cystic neurinomas, the signal was never hyperintense on the T1 sequence (14).

The cyclic rhythm of pain in our patient associated with the signal from the lesion (hyperintensity on T1- and T2-weighted images as in the signal and the absence of enhancement af-

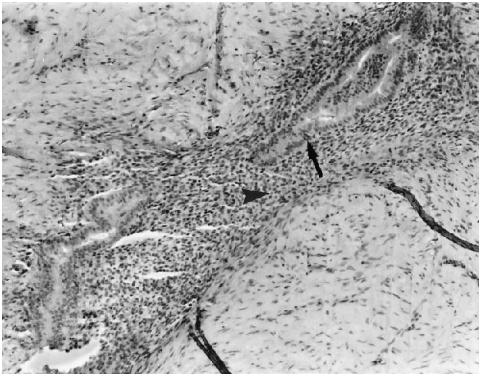


Fig 2. Photomicrograph (hematoxylin and eosin, $\times 100$) shows typical endometrial gland (arrow) surrounded by stroma (arrowhead).

ter gadolinium injection) should suggest a diagnosis of endometriosis.

Acknowledgments

We express an appreciation to Pr D. Sirinelli for his help and to Mrs D. Raine for her English lecture.

References

- Schlicke CP. Ectopic endometrial tissue in the thigh. *JAMA* 1946; 132:445
- Salazar-Gruoso E, Roos R. Sciatic endometriosis: a treatable sensorimotor mononeuropathy. *Neurology* 1986;36:1360–1363
- Hibbard J, Schreiber JR. Footdrop due to sciatic nerve endometriosis. *Am J Obstet Gynecol* 1984;149:800–801
- Fishman EK, Scatarige JC, Satsouk FA, Rosenhein NB, Siegelman SS. Computed tomography of endometriosis. *J Comput Assist Tomogr* 1983;7:257–264
- Richards BJ, Gillet WR, Polloc KM. Reversal of footdrop in sciatic nerve endometriosis. *J Neurol Neurosurg Psychiatry* 1991;54: 935–940
- Barbieri RL. Endometriosis 1990: Current treatment approaches. *Drugs* 1990;39(4):502–510
- Hedd HB, Welch JS, Mussey E, et al. Cyclic sciatica: report of a case with introduction of a new surgical sign. *JAMA* 1962;180: 521
- Torkelson SJ, Lee RA, Hildahl DB. Endometriosis of the sciatic nerve: a report of two cases and a review of the literature. *Obstet Gynecol* 1988;71:473–477
- Dagnelie J. Lombo-sciatalgie et endocrinologie: contribution à l'étude des endométriomes hétérotopiques. *Ann d'endocrinol* 1947;8:26–31
- Arrive L, Hricak H, Martin MC. Pelvic endometriosis: MR imaging. *Radiology* 1989;171:687–692
- Zawin M, McCarthy S, Scoutt L, Comite F. Endometriosis: appearance and detection et MR Imaging. *Radiology* 1989;171:693–696
- Nishimura K, Togashi K, Itohk, Fujisawa I, Noma S, Kawamura Y, et al. Endometrial cysts of the ovary: MR Imaging. *Radiology* 1987;162:315–318
- Suh JS, Abenozza P, Galloway HR, Everson LI, Griffiths HJ. Peripheral (extracranial) nerve tumors: correlation of MR imaging and histological findings. *Radiology* 1992;183:341–346
- Cerofolini E, Landi A, DeSantis G, Maiorana A, Canossi G, Romagnoli R. MR of benign peripheral nerve sheath tumors. *J Comput Assist Tomogr* 1991;15:593–597