
Primary Rhabdomyosarcoma of the Scalp

Stephen D. Foxx, Wendy R. K. Smoker, Nitya R. Ghatak, and Mark J. Kransdorf

Summary: We describe intracranial spread of primary scalp rhabdomyosarcoma in a 15-year-old boy who presented with signs of increased intracranial pressure.

Index terms: Myosarcoma; Scalp

One third of rhabdomyosarcomas in children arise in the head and neck. We present a case of primary scalp rhabdomyosarcoma that infiltrated the calvaria and spread intracranially.

Case Report

A 15-year-old black boy was seen at an outside hospital after 4 days of severe headache, nausea, and vomiting. Medical history and physical examination were unremarkable. A head computed tomographic (CT) scan (not available for our review) was interpreted as normal, and the patient was discharged. The patient returned 3 days later with no improvement in symptoms. Findings on head CT (filmed only with soft-tissue windows) were, again, interpreted as normal at the outside institution (Fig 1). Lumbar puncture revealed an opening pressure of 360 mm H₂O (normal, 100 to 200 mm H₂O), with 2 red blood cells and 2 white blood cells per cubic millimeter and 30 mg/dl of protein. Because of the high protein count and persistent symptoms, magnetic resonance imaging was performed (Fig 2) and showed a large intracranial and extracranial soft-tissue mass in the high parietal region producing inferior displacement of the cerebral hemispheres and caudal herniation of the cerebellar tonsils through the foramen magnum. Diffuse infiltration of the calvarial marrow was also present.

Fine-needle aspiration of the lesion was inadequate for pathologic diagnosis, and open biopsy of the lesion was performed. The tumor was composed of cells with irregular, polylobulated nuclei and a high nuclear-to-cytoplasmic ratio. DNA flow cytometry demonstrated two G₀G₁ peaks, indicating an aneuploid cell population. Immunoperoxidase staining of the tumor cells was positive for actin and desmin but negative for cytokeratin, neuron-specific enolase, and lymphoid markers. These findings, together

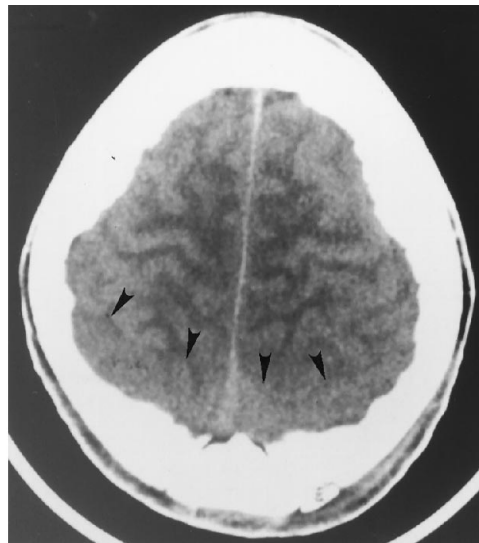


Fig 1. Axial unenhanced CT scan at the level of the upper cerebral hemispheres. The large intracranial component of the scalp mass is very difficult to appreciate in the axial plane (*arrowheads*). The increased thickness of the posterior scalp tissues was overlooked initially.

with the histopathology of a small round-cell tumor, led to the diagnosis of rhabdomyosarcoma, embryonal type.

Subsequent chest and abdominal CT examinations were normal, except for mild enlargement of the pancreatic head, presumably because of high-dose steroid therapy. Results of bone marrow aspirate and biopsy were normal. Bone scanning showed markedly pronounced uptake of radiotracer in the skull.

The patient was classified as having stage IV, group 4 rhabdomyosarcoma and was registered in the Intergroup Rhabdomyosarcoma Study #4. He was begun on a chemotherapy protocol consisting of vincristine, melphalan, and dexamethazone and underwent whole-brain and cervical spine irradiation to a total of 44.4 Gy. He also received reduced-field radiation of 7.2 Gy to the right and left brain fields. Despite aggressive treatment (including reinitiation of chemotherapy), the patient died 6 months after initial presentation.

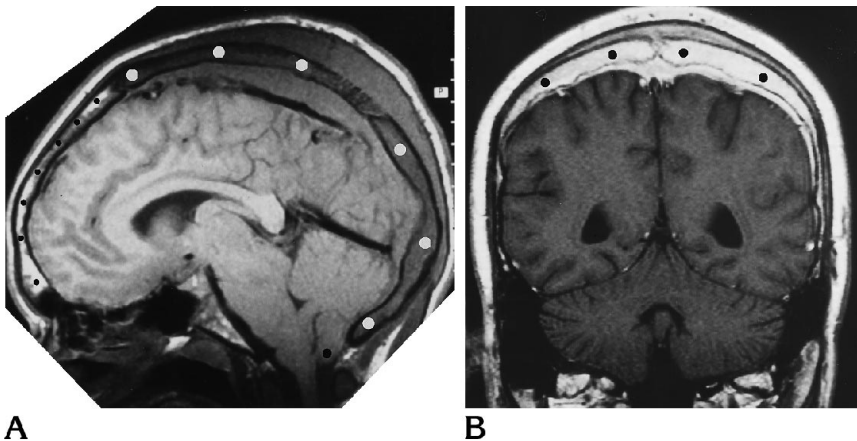
Received February 10, 1994; accepted after revision July 27.

From the Departments of Radiology (S.D.F., W.R.K.S.) and Pathology (N.R.G.), Medical College of Virginia, Richmond, and the Department of Radiology, St Mary's Hospital, Richmond, Va (M.J.K.).

Address reprint requests to Wendy R. K. Smoker, MD, Department of Radiology, Medical College of Virginia, Box 980615, MCV Station, Richmond, VA 23298.

Fig 2. A, Sagittal T1-weighted magnetic resonance image (600/20/2 [repetition time/echo time/excitations]) shows a large intracranial and extracranial soft-tissue mass, with infiltration of the calvarial marrow (white dots) from the posterior frontal region to the foramen magnum. Normal high signal intensity of noninfiltrated marrow (small black dots) in the anterior aspect of the frontal bone is present. There is marked compression on the parietal and occipital lobes with kinking and inferior displacement of the brain stem. Cerebellar tonsillar herniation is evident (large black dot).

B, Coronal T1-weighted magnetic resonance image (600/20) after contrast administration shows diffuse enhancement of the large, infiltrating soft-tissue mass (dots) and the meninges secondary to parameningeal spread of tumor.



Necropsy revealed tumor infiltrating the pancreas, both testicles, and the right sixth and eighth ribs. A soft-tissue mass within the oral cavity was found to represent tumor metastases, and there was enlargement and infiltration of some retroperitoneal lymph nodes. Tumor was also found in bone marrow taken from a lumbar vertebral body.

Although gross meningeal involvement was present, there was no evidence of skull or scalp infiltration by tumor. Histologic sections confirmed widespread involvement of the leptomeninges by metastatic rhabdomyosarcoma with small, round to oval cells arranged in a pattern of noncohesive nests and separated by thin fibrous septa. The nests had a pseudoglandular appearance, resembling alveoli, with central empty spaces, and this pattern led to a final classification of rhabdomyosarcoma, alveolar type.

Discussion

Rhabdomyosarcoma, a malignant tumor of mesenchymal origin, is the most common soft-tissue sarcoma in infants and children, representing 13% of all pediatric malignant neoplasms (1). Its incidence is approximately four new cases per million in children under age 15 (about 250 new cases each year in the United States) (2). The median age of presentation in two large series was about 7 years (3). Two peaks in age of onset are seen: one from 2 to 6 years and a second from 14 to 18 years (1, 4). About one half of patients are less than 5 years old and 70% less than 10 (5). The peak in teenage years is largely caused by paratesticular rhabdomyosarcoma (4). There is a 3:1 ratio of white children to black children, and approximately 60% of cases arise in males (3).

Four distinct histologic types are identified, all arising from primitive rhabdomyoblasts: *em-*

bryonal, the most malignant and most common type found in the head and neck; *botryoides*, a subset of the embryonal type, which always arises beneath a mucous membrane and grows as a polypoid mass; *pleomorphic*, rare in children and occurring mainly in the trunk and extremities; and *alveolar*, which grows in nests resembling pulmonary alveoli.

Forty percent of rhabdomyosarcomas arise in the head and neck, although they can arise in any part of the body (1). Interestingly, most rhabdomyosarcomas do *not* occur in muscle, but arise in sites where muscle is not usually located (1, 2). The most common sites of origin within the head are the orbit, nasopharynx, paranasal sinuses, middle ear, and external auditory canal. For therapeutic reasons, it is important to differentiate between a primary orbital location, a parameningeal location (defined as tumor close enough to the meninges to permit intracranial spread), and other sites. Because of the aggressiveness of the tumor, distant metastases and spread to contiguous bony structures are quite common. In the head and neck, these tumors often will cause extensive local bone destruction as the soft-tissue mass expands and infiltrates. It is, therefore, important that the CT scans be filmed at both narrow and wide window settings. Unfortunately, only narrow windows were available on hard copy for our review when the patient was transferred to our institution.

Parameningeal lesions tend to present late, as in this case, because of their location. Patients often have vague symptoms such as

headaches, weakness, or other signs of increased intracranial pressure. Seventy-six percent of parameningeal tumors eventually show direct extension into the central nervous system (6), and all parameningeal tumors will be associated with signs of an intracranial mass after invasion of the calvaria. The median survival after intracranial extension is 5 to 9 months (7).

Primary rhabdomyosarcoma of the scalp is rare. Although it is certainly possible that the scalp lesion identified in our patient represented a metastatic lesion, an exhaustive search for a primary tumor was negative. Latchaw (8) presented a case of metastatic rhabdomyosarcoma to the scalp with imaging characteristics very similar to our case, including infiltration of the skull and spread into the intracranial compartment.

The cause of this tumor is unknown, but there have been a few reported instances of associations with neurofibromatosis (1), fetal alcohol syndrome, basal cell nevus syndrome, and congenital abnormalities of the central nervous system (4). There is an increased prevalence of other malignant tumors in family members of children presenting with rhabdomyosarcoma (5), although most children with this malignant neoplasm have no identifiable associated disorder.

Treatment of these tumors can be surgical and/or radiotherapeutic or medical. Before 1972, long-term survival of head and neck rhabdomyosarcoma was rare, with survival rates as low as 10% to 34% (9). In 1972, the Intergroup Rhabdomyosarcoma Study introduced multimodality therapy in which surgery, multidrug chemotherapy, and radiotherapy were com-

bined (10). Prognosis improved significantly thereafter and has continued to improve in recent years because of more aggressive therapeutic regimens (3, 5, 9). However, in children with meningeal spread, mortality rates remain very high, and in some series are 100% (11).

References

1. Cunningham MJ, Myers EN, Bluestone CD. Malignant tumors of the head and neck in children: a twenty year review. *Int J Pediatr Otorhinolaryngol* 1987;13:279-292
2. Raney RB, Hays DM, Tefft M, et al. Rhabdomyosarcoma and the undifferentiated sarcomas. In: Pizzo PA, Poplack DG, eds. *Principles and Practice of Pediatric Oncology*. Philadelphia: Lippincott, 1989:635-658
3. Maurer HM, Beltangady M, Gehan EA, et al. The Intergroup Rhabdomyosarcoma Study-I: a final report. *Cancer* 1988;61:209-220
4. Dehner LP. *Pediatric Surgical Pathology*. 2nd ed. Baltimore: Williams & Wilkins, 1987:208-215
5. Maurer HM, Donaldson M, Gehan EA, et al. Rhabdomyosarcoma in childhood and adolescence. *Curr Probl Cancer* 1978;2:3-36
6. Shimada H, Newton WA Jr, Soule EH, et al. Pathology of fatal rhabdomyosarcoma: report from Intergroup Rhabdomyosarcoma Study (IRS-I and IRS-II). *Cancer* 1987;59:459-465
7. Tefft M, Fernandez C, Donaldson M, Newton W, Moon TE. Incidence of meningeal involvement by rhabdomyosarcoma of the head and neck in children: a report of the Intergroup Rhabdomyosarcoma Study. *Cancer* 1978;42:253-258
8. Latchaw RE. Extraaxial masses of the head. In: *Categorical Course on Imaging of Cancers*. Reston, Va: American College of Radiology, 1992:137-145
9. Flamant F, Hill C. The improvement in survival associated with combined chemotherapy in childhood rhabdomyosarcoma. *Cancer* 1984;53:2417-2421
10. Maurer HM. The Intergroup Rhabdomyosarcoma Study (NIH): objectives and clinical staging classification. *J Pediatr Surg* 1975; 10:977-978
11. Coene IMJH, Schowenburg PF, Voûte PA, Marion J, Burgers V, Hilgers FJM. Rhabdomyosarcoma of the head and neck in children. *Clin Otolaryngol* 1992;17:291-296