

Electrocorticographic Evaluation of Iobitridol, a Nonionic Contrast Medium, during Selective Cerebral Arteriography in Rabbits

Suzanne Trocherie, Faouzia Alaoui, Jean-Marc Idée, Robin Santus, and Louis Court

PURPOSE: To study the effects of iobitridol, a nonionic contrast medium, on the electrocorticography and the blood-brain barrier structure in rabbits. **METHODS:** Iobitridol was compared with isoosmolar mannitol and isotonic saline after selective injection (2.5 mL per rabbit in 30 seconds) into the internal carotid artery in the rabbit (six per group). The electrocorticograms (two frontooccipital leads) were then subjected to spectral analysis (fast Fourier transform). Evans blue dye served as a marker of blood-brain barrier damage. **RESULTS:** No blood-brain barrier damage was found, regardless of the treatment administered. Selective catheterization induced an increase in slow waves (0 to 4 Hz). Analyzed both spectrally (distribution of frequency bands, position of the maximum peak with respect to the distribution, and cerebral electric power) and conventionally, iobitridol did not modify the electrocorticograph parameters in the animals. This also applied to the mannitol and saline solutions. **CONCLUSION:** No chemotoxic effects of iobitridol were found.

Index terms: Animal studies; Brain, effects of drugs on; Cerebral angiography, contrast media; Contrast media, nonionic

AJNR Am J Neuroradiol 16:1637–1642, September 1995

The majority of the neurologic complications associated with cerebral angiography are not caused by the contrast medium but by the procedure (catheterization) itself (1). Nevertheless, the intracarotid injection of contrast medium can cause blood-brain barrier damage, thus allowing contrast medium to come into contact with the cerebral parenchyma. Although the part played by hyperosmolality in the cause of this phenomenon is clear when high-osmolality contrast media are concerned, other parameters such as chemotoxicity could also be involved. The aim of this study was to evaluate the possible electroencephalographic effects of iobitridol, a nonionic, low-osmolality contrast medium, when injected into the carotid artery of rabbits under conditions (volume and osmolal-

ity) more severe than encountered clinically. Moreover, it seemed of interest to investigate possible contrast medium-induced damage of the blood-brain barrier with the Evans blue extravasation technique. Comparison with an isoosmolar mannitol control and isotonic saline should allow any non-osmolality-dependent neurotoxicity to be demonstrated.

Materials and Methods

This study was conducted in 18 male New Zealand rabbits (Lantages, Sainte Savine, France) with a mean body weight (\pm SEM) of 2.7 ± 1.0 kg. The order of passage of the animals and the treatments received were randomized. Twenty-four hours before the start of the study, the rabbits were anesthetized with thiopental sodium injected at a dose of 20 mg/kg into a marginal ear vein, and the electrodes were implanted. The vertex of the skull was exposed and cleaned of periosteum. Each rabbit had four surface electrodes (Antogyr screw posts) implanted on either side of the median and transverse sutures so as to have two frontooccipital leads in a bipolar assembly.

On the day of the experiment proper, the rabbits were anesthetized (4% halothane for induction, then 2%); the right common carotid artery and its branches were surgically exposed; the external carotid artery was ligated; and a catheter (Steriflex G19, Vygon, Ecouen, France, outer

Received December 7, 1994; accepted after revision April 12, 1995.

From Commissariat à l'Energie Atomique, Fontenay-aux-Roses, France (S.T., F.A., L.C.); and Laboratoire Guerbet, Aulnay-sous-Bois, France (J.-M.I., R.S.).

Partial support for this project was provided by Laboratoire Guerbet.

Address reprint requests to Dr Suzanne Trocherie, Commissariat à l'Energie Atomique, DSV, DPTE/SSA, BP 6, 92265 Fontenay-aux-Roses Cedex, France.

AJNR 16:1637–1642, Sep 1995 0195-6108/95/1608–1637

© American Society of Neuroradiology

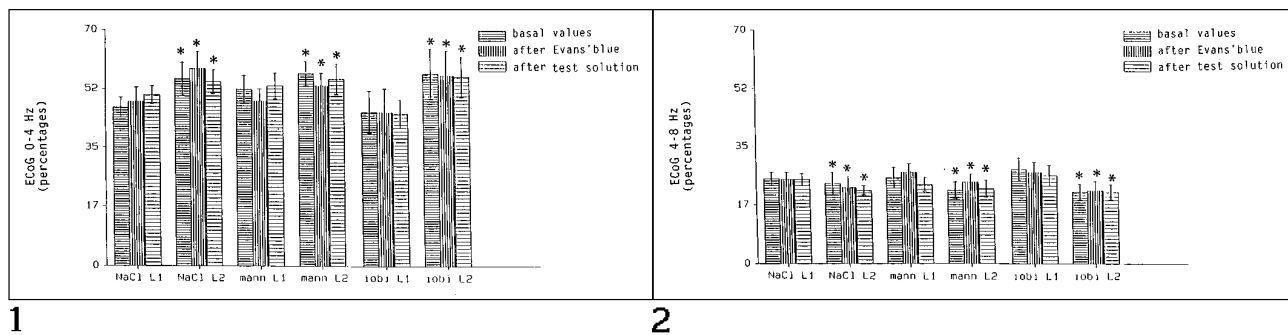


Fig 1. Percentages of delta waves on leads 1 (L1, left) and 2 (L2, right, catheterized side) before and after injection of Evans blue and the test solution. Asterisk indicates $P < .05$ versus the equivalent period on the other lead; NaCl, isotonic saline; mann, hypertonic mannitol; and iobi, iobitridol.

Fig 2. Percentages of theta waves on leads 1 (L1, left) and 2 (L2, right, catheterized side) before and after injection of Evans blue and the test solution. Asterisk indicates $P < .05$ versus the equivalent period on the other lead; NaCl, isotonic saline; mann, hypertonic mannitol; and iobi, iobitridol.

diameter 1 mm) was inserted via the common trunk of the artery at the internal carotid artery. The rabbits were then tracheotomized, curarized (gallamine triethiodide, 3 mg/kg intravenously) and placed on assisted ventilation (Bird Mark 8 respirator, SEBAC, Pantin, France). To avoid reactions caused by pain on recovery, the surgical field was impregnated with 2% lidocaine.

Each group contained six rabbits. The allocation of the animals to the groups and the order of the injections were randomized. Each animal received one injection only. The following solutions were injected per group: iobitridol (5[3 hydroxy-2-(hydroxymethyl)-propionamido]-*N-N'*-dimethyl-*N-N'*-bis-(2,3-dihydroxypropyl)-2,4,6-triiodoisophthalamide) (Xenetix, Laboratoire Guerbet, Aulnay-sous-Bois, France) containing 350 mg/mL of iodine (osmolality, 915 mOsm/kg); isoosmolar mannitol (906 mOsm/kg); and saline isotonic to the plasma. The osmolality of the iobitridol and mannitol solutions were measured by tonometry (Wascor 5500 osmometer, Logan, Utah). Rabbits were given an injection of Evans blue that was allowed to equilibrate for 10 minutes and then were injected with either iobitridol, mannitol, or saline.

The electrocorticograms were recorded for a total of 75 minutes. Recording was divided into three distinct periods: (a) the first 15 minutes, representing the control phase, without injection, (b) injection of the Evans blue (filtered 2.5% solution, 2 mL intravenously in a marginal ear vein) and the 10 minutes after this injection, and (c) manual injection of the test solution (2.5 mL in 30 seconds, according to the technique used by Wilson et al [2]) and the 50 minutes after the injection. The tracings recorded during the above three periods were analyzed visually by spectral analysis.

The electrocorticograms were recorded continuously on a Gould ES 1000 polygraph (Gould Electronique France, Ballainvilliers, France) and on a TEAC (Tokyo, Japan) R-71 stereo tape cassette recorder and were visible on a Gould V 1000 monitor. The amplitude of the electrocorticograph was 50 μ V/cm. The electrocorticographic data were processed using the fast Fourier transform

method on an Intertechnich IN 1200 computer (Siemens, Erlangen, Germany) (200-Hz sampling frequency, 12 bits plus sign amplitude encoding, epochs of 5.12 seconds' duration).

At the end of the experiment, the rabbits were killed with an intravenous overdose of thiopental sodium. The brains were carefully removed, and any blood-brain barrier damage was graded according to the following scale: 0, no passage of dye; 1, moderate passage of dye (localized areas situated in the cerebral parenchyma and/or in the basal ganglia); and 2, major and uniform passage of Evans blue into the above-mentioned areas of the brain.

The effects of the test solutions over time were compared using the Mann-Whitney U test after a Kruskal-Wallis analysis. The effects of ligating the carotid artery were evaluated by comparing the initial electrocorticogram (before injection) for the right hemisphere of the brain (injected side) to the left hemisphere using the Student's t test for all the frequency bands. The level of significance was set at 5%.

Results

No extravasation of Evans blue was observed in any of the brains examined, regardless of the treatment administered. According to this method, no detectable blood-brain barrier damage had occurred.

Visual analysis of the electrocorticograms evidenced no morphologic changes. Spectral analysis of the first control period and that after injection of Evans blue showed, for the slow waves, a statistically significant difference between the right and left frontooccipital leads. The percentage of delta waves (0 to 4 Hz) was higher on the right side (catheterized side) than on the left ($P < .05$) (Fig 1). Conversely, the percentage of theta waves (4 to 8 Hz) was lower

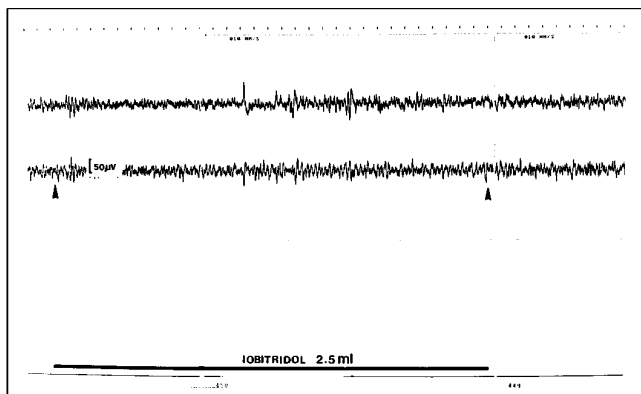


Fig 3. Sample tracing of the two frontooccipital leads during the injection of iobitridol into the right carotid artery (lead 2, indicated by arrowheads).

in the injected hemisphere ($P < .05$) for any given period (Fig 2). Despite certain individual variances, no significant difference was observed between the two leads for the other frequencies (8 to 12 Hz to 30 to 40 Hz). No significant difference was observed between the first control period and that after the injection of Evans blue.

Conventional analysis of the electrocorticograms evidenced no abnormalities (ie, paroxysm-type tracings) (Fig 3). The tracings were regular and consisted mainly of slow activity at 4 to 5 Hz of wide amplitude. The injection of Evans blue did not significantly alter the plot from the first control period for any of the groups observed. No significant change in the electrocorticograms was evidenced for any of the parameters chosen after the injection of iobitridol, mannitol, or isotonic saline into the carotid artery (Figs 4 and 5). During injection, four rabbits had transient changes in the distribution

of the frequencies within the spectrum: three of these changes occurred during the second control period (after injection of Evans blue), two in the saline group and one in the iobitridol group, and one change after injection of iobitridol. The changes observed were a transient 10% to 20% increase (between 2 and 20 seconds) in the slow activity content (0 to 4 Hz).

Discussion

The neurotoxicity of contrast media administered intravenously for the imaging of vessels in the head and neck is a topical problem (3–5). Junck and Marshall (1) report nonnegligible rates of neurotoxic effects after arteriography (aortic arch and carotid or vertebral arteries) with a high-osmolality contrast medium; these were: convulsions (0.2% to 0.4%), transient cortical blindness (0.3% to 1%); and focal deficits, that is, hemiparesis, aphasia, and sensory deficits (0.5% to 12%). Cases of transient global amnesia have also been reported (4). Attribution of these effects to the contrast media alone is misguided, because this does not take into account the role played by atheromatous or air embolisms or arterial dissection. The electroencephalographic changes associated with the injection of a contrast medium during cerebral arteriography are either a decrease in voltage (6) or the appearance of paroxysm-type tracings, which are not related to the occurrence of epileptic seizures (7). However, other studies have evidenced no electroencephalographic changes (8).

Numerous studies have dealt with the role of contrast media osmolality in the cause of these neurologic problems: the intracarotid adminis-

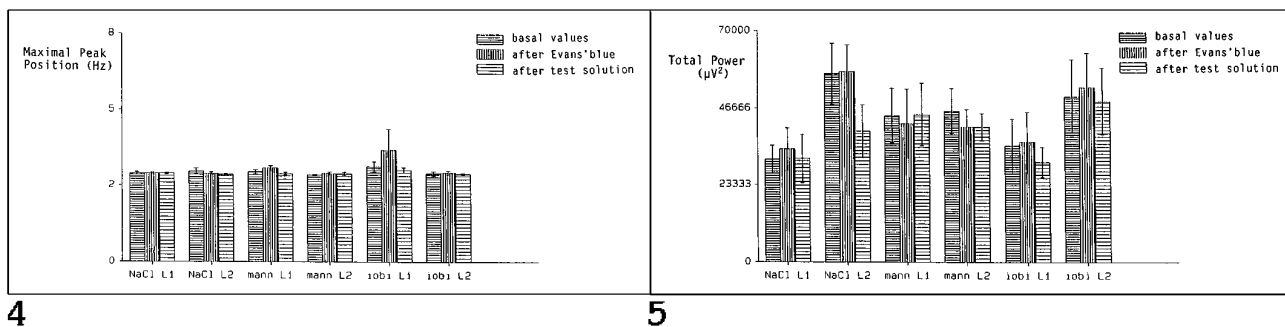


Fig 4. Maximal peak position on leads 1 (L1, left) and 2 (L2, right, injected) at the different experimentation times. NaCl indicates isotonic saline; mann, hypertonic mannitol; and iobi, iobitridol.

Fig 5. Total power of the electrocorticograph on leads 1 (L1, left) and 2 (L2, right, injected) at the different experimentation times. NaCl indicates isotonic saline; mann, hypertonic mannitol; and iobi, iobitridol.

tration of high-osmolality contrast media such as diatrizoate in animals is often associated with blood-brain barrier disruption (9, 10) and electroencephalographic changes (increased slow-wave activity) (11). For certain authors, this phenomenon occurs when tight junctions in the interendothelial cleft open in response to hyperosmolar insults (12). Other authors have noted that, unlike other types of insult, with contrast media there is no detectable change in the distribution of negative surface charge or Ca^{++} -adenosine triphosphatase activity on the luminal plasma membranes of endothelial cells of blood-brain barrier vessels (13). This suggests that the blood-brain barrier-disruptive effects of contrast media are not mediated through these important endothelial cell components, unlike other types of insult such as acute hypertension. Furthermore, from the findings of animal studies, arterial hypertension could be a risk factor for blood-brain barrier damage, particularly where high-osmolality contrast media are concerned (5).

Compared with high-osmolality contrast media, the new low-osmolality contrast media (ioxaglate and nonionic media) have greatly reduced the incidence of hemodynamic and neurologic adverse reactions (5, 14–16). However, osmolality alone cannot explain the transendothelial passage of contrast media molecules: Caillé and Allard (3) suggest that all contrast media, even those that are isoosmolar to plasma, can cross the blood-brain barrier. This has been confirmed by several studies showing that iodixanol and iotrolan, both of which are isotonic to plasma, induce significantly more blood-brain barrier damage than isotonic saline (2, 5). This theory of chemotoxicity has been studied in detail more recently by Wilson et al (2), who, on a model similar to our own, demonstrated that contrast media-related damage to the blood-brain barrier is osmolality independent and at least partially unrelated to the hydrophilicity of the molecule. Osmolality might only have a deleterious effect from a given level (700 mOsm/kg). In 1974, Oldendorf (17) showed that the lipophilicity of a molecule is predictive of its ability to cross the blood-brain barrier. Viscosity also seems to encourage the passage of contrast media across the blood-brain barrier (18), which could explain the poor results obtained by Wilson et al for iotrolan and iodixanol (2). Furthermore, in this study, all the contrast media tested caused more blood-brain

barrier damage than isoosmolar mannitol (2). This is why we have compared iobitridol and isoosmolar mannitol here.

Our experimental model calls for the recording of the electrocorticograph in the rabbit. This animal is often used for electroencephalographic studies because of its clinical relevance and its ease of use (19, 20). Moreover, the pattern of major cerebral vessels of the rabbit is the same as in humans (5).

Because the electrodes are implanted directly into the dura mater, the absence of a cranium means that the potentials recorded are much less filtered than in surface electroencephalography (21). The slow waves, whose increase in clinical terms is indicative of the degree of sedation, are situated between 0 and 4 to 7 Hz. The maximum peak represents the frequency band of the spectrum for which the percentage of energy is the highest. It changes depending on the awareness of the subject.

Our protocol maintained the animals in a constant state of light, controlled anesthesia, and this is reflected in the steady increase in delta activity (0 to 4 Hz) at the expense of theta activity (4 to 8 Hz). The maximum peak with respect to the distribution of the frequency bands is always situated between 3 and 3.5 to 3.7 Hz (Figs 4 and 5). Awareness is therefore reduced (the peak is situated in the delta activity) and does not change during the experiment. This is an important point, because it indicates that the state of awareness of the rabbits does not vary.

Our protocol stipulated the administration of contrast media with a high iodine concentration (350 mg/mL) and by extension a greater osmolality than that in clinical practice. This was a deliberate choice and was intended to create the best conditions for the evaluation of the neurotoxic potential of this nonionic contrast medium. The volumes of the test solutions administered were chosen on the basis of the results obtained by Wilson et al (2). These authors showed that the same volume (2.5 mL) of nonionic contrast media (whether hyperosmolar to plasma, such as iohexol and ioversol, or isotonic, such as iodixanol and iotrolan) induced the extravasation of technetium-99m pertechnetate, and therefore blood-brain barrier damage. The osmolality of these contrast media (maximum iodine concentration of 320 mg/mL) was lower than that of the iobitridol tested here. Finally, Whisson et al (22) have moni-

tored the infusion pressure produced by this regimen and have shown that it does not exceed the pressure threshold beyond which blood-brain barrier disruption has been shown to occur (22). Evans blue is a gross marker of blood-brain barrier damage classically cited in the literature (10, 23). Unlike the subarachnoid route (24, 25), the intracarotid route has rarely been used for electroencephalographic studies.

Andrews et al (20) observed that temporary occlusion of the middle cerebral artery in rabbits caused the electroencephalographic tracing to disappear from 5 minutes after the start of the experiment. In particular, they report that computerized electroencephalographic analysis also enhances the sensitivity of the electroencephalogram to changes caused by cerebral ischemia. Our results confirm their findings, because the difference between the two frontooccipital leads before injection was detected by spectral analysis only and not by visual evaluation. This phenomenon is probably related to the selective catheterization of the right internal carotid artery and to its subsequent hypoperfusion. It should be noted that catheterization never caused paroxysm-type electroencephalographic tracings.

Whisson et al (22) studied the effects of the intracarotid injection of various contrast media on facial electromyograms in the anesthetized rabbit. Unlike the other contrast media, whether high-osmolality contrast media, nonionic contrast media (iohexol and iopromide), or a plasma-isotonic ionic dimer (iotrolan), all of which caused a phenomenon of arousal or cortical irritation, these authors noted no irritative changes in the electroencephalogram after the injection of saline or mannitol (650 mOsm/kg). Our protocol used the same doses. Like theirs, our control tracings were characterized by the predominance of slow waves. Our results comply with theirs, in that no electroencephalographic changes were observed after the administration of hypertonic mannitol. However, under our conditions, the contrast medium (iobitridol) did not modify the electrocorticograph.

Iobitridol in no way changed the total energy, the position of the maximum peak, or the distribution of the different bands of the electroencephalogram in the 50 minutes after injection. Unlike the data reported for other contrast media (2, 22), this study evidenced no chemotoxic effect for iobitridol. The iobitridol molecule does not deform when in contact with lipophilic

membranes and therefore cannot form hydrophobic bonds with them. This concept of molecular deformability is recent and casts doubts on preconceived notions about molecule-protein interactions (26). The decrease in the number of contrast media and biological membrane hydrophobic bonds should reduce the risk of adverse reactions.

This study did not reveal any findings to suggest neurotoxic effects of iobitridol after selective intracarotid injection in the rabbit, under severe conditions (dose and osmolality). Moreover, unlike other authors studying other nonionic contrast media on similar models (2, 22), we did not find that the iodinated contrast medium studied here had chemotoxic potential.

Acknowledgments

We express special gratitude to Sara Newbery, Andrew Macauley, and Dominique Debize-Henderson for the English translation and to Huguette Lamoulie for her help in the preparation of the manuscript.

References

1. Junck L, Marshall WH. Neurotoxicity of radiological contrast agents. *Ann Neurol* 1983;13:469-484
2. Wilson AJ, Evill CA, Sage MR. Effects of nonionic contrast media on the blood-brain barrier: osmolality versus chemotoxicity. *Invest Radiol* 1991;26:1091-1094
3. Caillé JM, Allard M. Neurotoxicity of hydrosoluble iodine contrast media. *Invest Radiol* 1988;23:S210-S212
4. Bardy AP, Hough DM, Lo R, et al. Transient global amnesia after cerebral angiography with iohexol. *Can Assoc Radiol J* 1993;44:450-452
5. Sage MR, Wilson AJ. The blood-brain barrier: an important concept in neuroimaging. *AJNR Am J Neuroradiol* 1994;15:601-622
6. Lundervold A, Engeset A. Polygraphic recordings during cerebral angiography. *Acta Radiol* 1966;5:368-380
7. Skälpe IO, Lundervold A, Tjorstad K. Cerebral angiography with nonionic (metrizamide) and ionic (meglumine metrizoate) water-soluble contrast media. *Neuroradiology* 1977;14:15-19
8. Nakstad P, Sortland O, Aeserud O, Lundervold A. Cerebral angiography with the nonionic contrast medium iohexol and meglumine-Ca-metrizoate. *Neuroradiology* 1982;23:199-202
9. Harnish PP, Krutchen A, Mukherji M. Intravascular contrast media and the blood-brain barrier: testing the new nonionic agent ioxilan. *Invest Radiol* 1989;24:34-36
10. Wilcox J, Evill CA, Sage MR. Effects of intracarotid ionic and nonionic contrast material on the blood-brain barrier in a rabbit model. *Neuroradiology* 1986;28:271-274
11. Cahn J, Borzeix MG, Cahn R. Etude expérimentale comparée de la tolérance du système nerveux central à l'administration d'ioipamidol, de métrizamide, d'ioxitalamate, d'ioxaglate et d'ioarmate. *Ann Radiol* 1983;28:774-778
12. Burns ZM, Dobben GD, Kruckeberg TW, Gaetano PK. Blood-brain barrier: morphology, physiology, and effects of contrast media. In: Carney AL, Anderson EM, eds. *Advances in Neurology, Diagnosis and Treatment of Brain Ischemia*. New York: Raven Press, 1981; 30:159-165

13. Wilson AJ, Sage MR. Cytochemical studies on contrast medium-induced blood-brain barrier damage. *Invest Radiol* 1994;29: S105-S107
14. Ahlgren P. Iohexol compared to Urografin meglumine in cerebral angiography: a randomized, double-blind cross-over study. *Neuroradiology* 1982;23:195-198
15. Nilsson PE, Aspelin P, Elmquist D. Aorticervical angiography with high and low osmolality ionic contrast media: a clinical investigation of metrizoate and ioxaglate. *Acta Radiol* 1985;26: 731-738
16. Katayama H, Sumie H. Diagnostic efficacy and safety of two low osmolar contrast media in cerebral angiography. *Eur Radiol* 1994;4:185-189
17. Oldendorf WH. Lipid solubility and drug penetration of the blood-brain barrier. *Proc Soc Exp Biol Med* 1974;147:813-816
18. Wilcox J, Sage MR. Is viscosity involved in the production of blood-brain barrier disruption by intracarotid contrast media? *Neuroradiology* 1984;26:511-513
19. Petsche H, Pockberger H, Rappelsberger P. On the search for the source of the electroencephalogram. *Neuroscience* 1984;11:1-27
20. Andrews BT, Weinstein PR, Faden AI. Computerized cortical surface electroencephalography after temporary middle cerebral artery occlusion in rabbits. *Neurosurgery* 1988;22:681-686
21. Delay J, Verdeaux G. *Electroencéphalographie Clinique*. Paris: Masson, 1969
22. Whisson CC, Evill CA, Sage MR, Wilson AJ. Muscular and CNS effects of carotid artery administration of contrast media in rabbits. *AJNR Am J Neuroradiol* 1990;11:143-148
23. Zagzag D, Goldenberg M, Brem S. Angiogenesis and blood-brain barrier breakdown modulate CT contrast enhancement: an experimental study in a rabbit brain-tumor model. *AJNR Am J Neuroradiol* 1989;10:529-534
24. Gonsette RE, Brucher JM. Neurotoxicity of novel water-soluble contrast media for intrathecal application. *Invest Radiol* 1980;15: S254-S259
25. Sovak M, Ranganathan R, Johnson M. Spectral analysis of lapine EEG: neurotoxicologic evaluation of new nonionic contrast media. *Invest Radiol* 1980;15:452-456
26. Jorgensen WL. Rusting of the lock and key model for protein-ligand binding. *Science* 1991;254:954-955