

Benign Osteoblastoma of the Temporal Bone

Motoomi Ohkawa, Naomi Fujiwara, Masatada Tanabe, Hitoshi Takashima, Katashi Satoh, Yasutane Mori, Yasumasa Honjo, and Seigo Nagao

Summary: We report a case of benign osteoblastoma arising in the temporal bone of a 28-year-old woman. Plain radiography showed a mass with an amorphous calcified matrix and a thin radiolucent marginal zone. CT and MR imaging were useful in delineating the extent of the tumor, and angiography showed its hypervascularity. Preoperative transarterial embolization was effective in reducing bleeding during surgery.

Index terms: Bones, neoplasms; Temporal bone, neoplasms

Benign osteoblastoma is a rare primary bone tumor that commonly affects the vertebral column or the long tubular bones of the lower extremities (1–3). Its occurrence in the temporal bone is extremely rare (4–12). We report a case of benign osteoblastoma arising in the temporal bone with particular reference to its radiologic manifestations and to the effectiveness of preoperative transcatheter arterial embolization.

Case Report

A 28-year-old woman had had a dull ache in the retroauricular area for 1 year. Physical examination revealed tenderness in the retroauricular area, but no evidence of cranial nerve involvement. Laboratory data showed no hematological, biochemical, or tumor marker abnormalities. Occipital neuralgia was diagnosed and treated, but the symptoms did not improve and localized swelling and tenderness appeared. The patient underwent radiologic examination for a suspected underlying organic lesion.

Plain radiography in the Schüller projection showed a large mass with an amorphous calcified matrix and a thin radiolucent marginal zone posterior and superior to the external auditory canal (Fig 1A). Axial and coronal computed tomographic (CT) scans showed a well-demarcated bulging osteolytic lesion with massive internal calcification and a barely visible inner cortex (Fig 1B). The patient was admitted to our hospital for surgical treatment of the temporal bone tumor. At magnetic resonance (MR) imaging, axial T1-weighted images showed the lesion to be mostly hypointense with isointense areas at the periphery and in some inner parts of the lesion (Fig 1C). T2-weighted im-

ages also showed most of the lesion to be hypointense, with some areas of high intensity at the periphery (Fig 1D). T1-weighted images obtained after intravenous administration of gadopentetate dimeglumine, 0.1 mmol/kg, showed strong enhancement mainly in the peripheral part of the lesion and in the dura mater on the upper axial section (Fig 1E and F). The latter had the appearance of a dural tail. Angiography of the left external carotid artery showed the tumor to have markedly increased fine vessels and to be supplied by the occipital artery, the posterior auricular artery, and the posterior branch of the middle meningeal artery (Fig 1G). There was no supply from the left internal carotid and vertebral arteries. In the venous phase, there was occlusion of the left transverse sinus.

On the basis of the radiologic findings, the tumor was judged to be a benign osteoblastoma. Although removal of the tumor was proposed, the fact that it was fed from multiple branches of the external carotid artery suggested a risk of bleeding during surgery. Therefore, preoperative transcatheter embolization was performed the day before surgery. Angiography after embolization showed complete obliteration of the feeding artery and of tumor staining (Fig 1H).

At surgery, although the tumor was adherent to the dura mater, it was easily and completely removed. Intraoperative bleeding was less than 300 mL and did not necessitate blood transfusion.

Postoperative histologic findings (Fig 1I) showed areas containing a florid proliferation of osteoblasts and marked vascularity in the tumoral stroma. The osteoblasts had a polygonal, immature structure with a high nucleocytoplasmic ratio, producing an eosinophilic osteoid. The histologic diagnosis of the tumor was benign osteoblastoma. The patient was well without any sign of recurrence 3 years after surgery.

Discussion

Benign osteoblastoma is an uncommon bone tumor that was reported under the present designation separately by Jaffe (13) and Lichtenstein (4) in 1956. It accounts for about 1% of all primary bone tumors, and usually occurs in ad-

Received February 5, 1996; accepted after revision May 28.

From the Departments of Radiology (M.O., N.F., M.T., H.T., K.S., Y.M.) and Neurosurgery (Y.H., S.N.), Kagawa Medical School, Kagawa, Japan.

Address reprint requests to Motoomi Ohkawa, MD, 1750-1 Ikenobe, Miki-cho, Kita-gun, Kagawa 761-07, Japan.

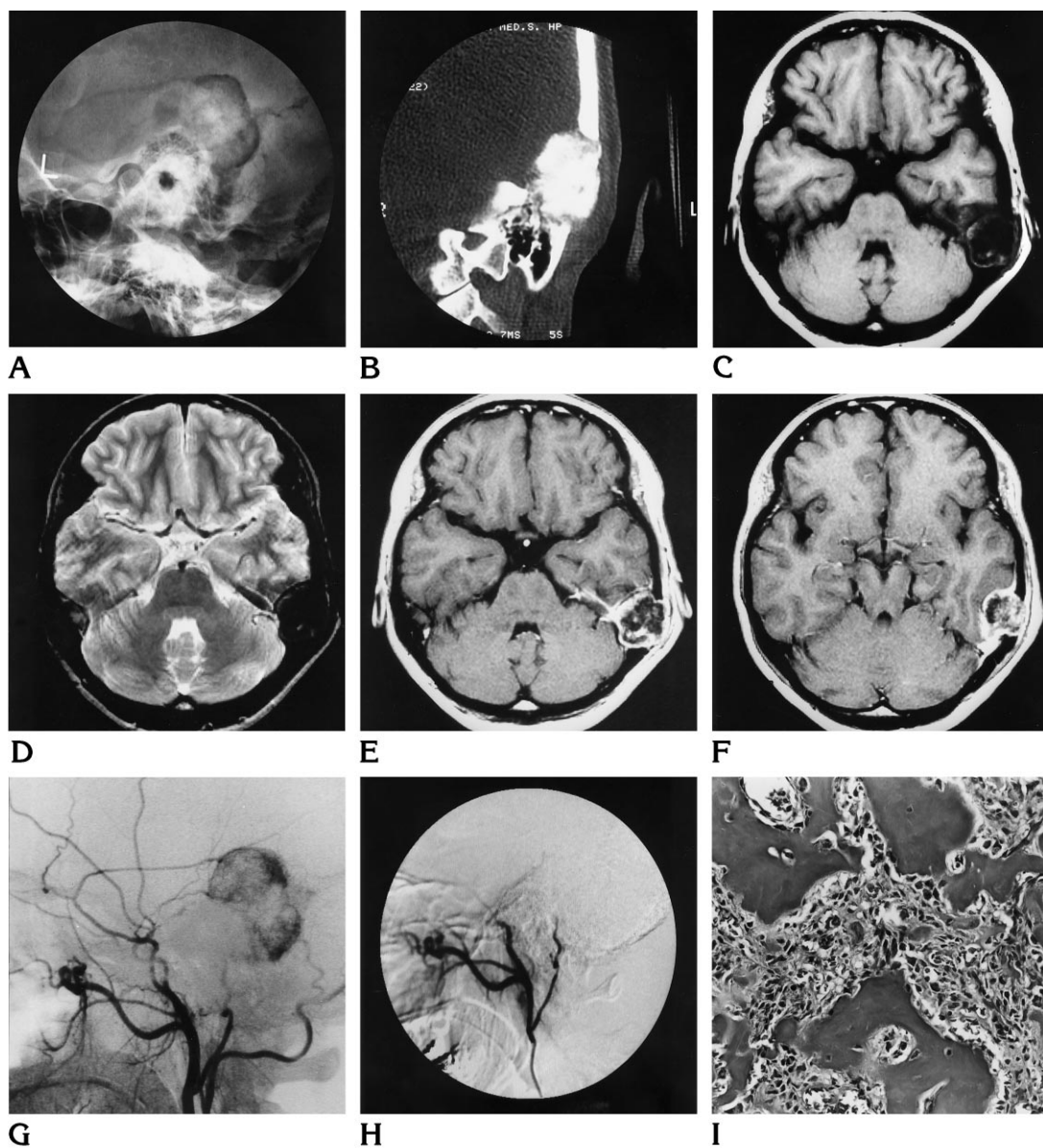


Fig 1. A 28-year-old woman with benign osteoblastoma of the temporal bone.

A, Computed radiograph of left temporal bone in the Schüller projection shows a large mass with amorphous calcification in the central portion and a thin radiolucent zone.

B, Coronal CT scan shows extensive calcification and bulging toward the intracranial side. Tumoral new bone is well seen; there is no shell calcification.

C, T1-weighted MR image shows isointense lesion with rather extensive low-signal area, suggestive of calcification.

D, T2-weighted MR image shows high intensity in the peripheral part with a central low-signal area.

E and *F*, Contrast-enhanced T1-weighted MR images show peripheral enhancement of the lesion. In the upper axial image, meningeal enhancement (dural tail sign) is also noted.

G, Left external angiogram before embolization shows neovascularity supplied by posterior branch of middle meningeal artery, occipital artery, and posterior auricular artery. There is no irregularity in the vascular caliber of the supplying arteries.

H, Left external angiogram after embolization shows obliteration of tumor vascularity and tumor blush.

I, Light micrograph of resected specimen shows polygonal, immature mesenchymal tumor cells with a high nucleocytoplasmic ratio, producing an eosinophilic osteoid (hematoxylin-eosin, original magnification $\times 66$).

olescents and young adults, with some male preponderance (1, 2).

Clinical symptoms are not specific, and patients usually report pain or painful swelling. The most frequent location of benign osteoblastoma is in the spine, followed by the long tubular bones of the lower extremities (1–3). Its occurrence in the temporal bone is very unusual (4–12). The plain radiographic findings of benign osteoblastoma have been reported as a well-demarcated osteolytic lesion with or without calcification of varying degrees (4, 5, 14). Similarly, radiography in our case also showed the tumor as a well-demarcated osteolytic lesion with rather extensive calcification, which is thought to be a typical finding of benign osteoblastoma.

Previous authors (14) have reported that CT gave better or additional information compared with plain radiography, such as precise tumor origin, intraosseous extent, and growth into the soft tissues. In our case, CT was also effective in depicting tumor extent and calcification.

Although reports of MR imaging findings are few, they describe low and intermediate signal intensity on T1-weighted images and high signal intensity on T2-weighted images (14). The signal intensities were not as specific as those found in other bone tumors. In our case, the T1-weighted images obtained after intravenous administration of contrast material showed dural enhancement, which suggests dural invasion or at least adherence to the dura (15).

Some investigators have reported the angiographic findings of bone tumors. However, it is difficult to determine the histologic nature of these tumor by angiography (14, 16–18), a fact that we also noted. Nevertheless, angiography gave us important information in the preoperative assessment of our patient; for example, that the lesion was supplied by branches of the external carotid artery; the middle meningeal artery; the posterior auricular artery; and the meningeal branches of the occipital artery. Accordingly, we performed embolization with gelatin sponge particles the day before the operation. The efficacy of preoperative embolization for meningioma has been reported previ-

ously (19, 20); and because the osteoblastoma in our patient also had rich vascularity, embolization was considered appropriate.

References

1. Dahlin DC. *Bone Tumors: General Aspect and Data on 8542 Cases*. 4th ed. Springfield, Ill: Charles C Thomas; 1986:86–98
2. McLeod R, Dahlin DC, Beabout JW. The spectrum of osteoblastoma. *AJR Am J Roentgenol* 1976;126:321–335
3. Mrash BW, Bontiglio M, Brandy LP, Enneking WF. Benign osteoblastoma: range of manifestations. *J Bone Joint Surg Am* 1975; 57:1–9
4. Lichtenstein L. Benign osteoblastoma: a category of osteoid and bone-forming tumors other than classical osteoid which may be mistaken for giant-cell tumor or osteogenic sarcoma. *Cancer* 1956;9:1044–1052
5. Lichtenstein L, Sawyer WR. Benign osteoblastoma: further observations and report of twenty additional cases. *J Bone Joint Surg Am* 1964;46:755–765
6. Ronis ML, Obando M, Bucko MI, Liebman EP. Benign osteoblastoma of the temporal bone. *Laryngoscope* 1974;84:857–863
7. Glasscock ME, Miller GW, Drake FD, Kanok MM. Surgery of the skull base. *Laryngoscope* 1978;88:905–923
8. Potter C, Conner GH, Sharkey FE. Benign osteoblastoma of the temporal bone. *Am J Otol* 1983;4:318–322
9. Gellad FE, Hafiz MA, Blanchard CL. Osteoblastoma of the temporal bone: CT findings. *J Comput Assist Tomogr* 1985;9:577–579
10. Miyazaki S, Tsubokawa T, Katayama Y, et al. Benign osteoblastoma of the temporal bone of an infant. *Surg Neurol* 1987;27:277–283
11. Adler M, Hnatuk L, Mock D, Freeman JL. Aggressive osteoblastoma of the temporal bone: a case report. *J Otolaryngol* 1990;19: 307–310
12. Singer JM, Deutsch GP. The successful use of radiotherapy for osteoblastoma. *Clin Oncol (R Coll Radiol)* 1993;5:124–125
13. Jaffe HL. Benign osteoblastoma. *Bull Hosp Jt Dis* 1956;17:141–151
14. Kroon HM, Schuurmans J. Osteoblastoma: clinical and radiologic findings in 98 new cases. *Radiology* 1990;175:783–790
15. Bourekas EC, Wildenhain P, Lewin JS, et al. Dural tail sign revisited. *AJNR Am J Neuroradiol* 1995;16:1514–1516
16. Hudson TM, Enneking WF, Hawkins IF Jr. The value of angiography in planning surgical treatment of bone tumors. *Radiology* 1981;138:283–292
17. Strickland B. The value of arteriography in the diagnosis of bone tumors. *Br J Radiol* 1959;32:705–713
18. Yaghmai I, Shamsa AZ, Shariat S, Afshari R. Value of arteriography in the diagnosis of benign and malignant bone lesions. *Cancer* 1971;27:1134–1147
19. Manelfe C, Lasjaunias P, Rusalleda J. Preoperative embolization of meningiomas. *AJNR Am J Neuroradiol* 1986;7:963–972
20. Dean BL, Flom RA, Wallace RC, et al. Efficacy of endovascular treatment of meningiomas: evaluation with matched samples. *AJNR Am J Neuroradiol* 1994;15:1675–1680