

Enlarged Cochlear Aqueduct

Suresh K. Mukherji, Henry C. Baggett, Jay Alley, and Vincent H. Carrasco

Summary: Enlargement of the cochlear aqueduct is a controversial topic, with experienced investigators doubting its existence because of a lack of published cases. We describe the CT appearance of an enlarged cochlear aqueduct in a patient with advanced congenital inner ear anomalies and congenital hearing loss. The intent of this article is to present the CT appearance of a presumably enlarged cochlear aqueduct and to underscore the need to examine this structure in patients with congenital hearing loss.

The cochlear aqueduct is a bony canal that connects the subarachnoid space to the basal turn of the cochlea. Enlargement of the cochlear aqueduct has been suggested as a cause of sensorineural hearing loss and perilymph fistula (1). However, because of its rarity, previous investigators have suggested that this malformation may not exist (2, 3). The intent of this report is to document the computed tomographic (CT) appearance of an enlarged canal in the expected location of the cochlear aqueduct. This malformation may be present in patients with congenital hearing loss and other inner ear abnormalities.

Case Report

An 18-month-old boy was referred to our institution for evaluation of severe bilateral hearing loss. The prenatal and birth history were unremarkable. The hearing loss was identified at 15 months of age, at which time he was fitted with Phonak (Naperville, Ill) PP-CL-P hearing aids binaurally. However, the boy's mother reported no improvement in his responsiveness with the hearing aids. Other than delays in speech and language acquisition, the patient developed normally.

Physical examination revealed normal tympanic membranes. The remainder of the neurologic examination was unremarkable. Audiologic examination disclosed a profound sensorineural loss, with greater than 90-dB hearing loss on the left and no response on the right. Aided testing showed only minimal response binaurally. The patient was severely deficient in speech perception and production.

Temporal bone CT with contiguous axial and coronal 1-mm-thick sections (field of view, 9.6 cm) showed severe inner ear dysplasias bilaterally, including malformation of the common cavity with dysplasia of the semicircular canals (Fig 1). The right common cavity was separated from the internal auditory canal (IAC) by a thin bony plate; the left common cavity opened widely into the IAC. The vestibular aqueducts were not enlarged on either side. A bony canal that courses along the expected location of the left cochlear aqueduct was dilated and was clearly visible throughout its course, from the medial to the lateral orifice (Fig 1). The diameter of the lateral orifice and midotic capsular portion of the left cochlear aqueduct was 1.2

mm. The right cochlear aqueduct was slightly irregular but not definitely enlarged.

On the basis of clinical and audiologic examination, the patient was considered to be a suitable candidate for cochlear implantation. Typically, the ear with the greatest hearing loss is implanted to prevent conflicting signals between the implant and normal auditory signal transmission. At 2 years of age, the patient received a Clarion (Simi Valley, Calif) eight-channel cochlear implant in the right ear. No perilymphatic fistula developed during cochleotomy for insertion of the electrode. The patient did well postoperatively and early evaluation indicated that the implant was stimulating well. Three months after implantation, the patient had a 50-dB hearing threshold and conditioned responses to stimulation.

Discussion

The cochlear aqueduct is the narrow bony canal that surrounds the perilymphatic (periotic) duct. The perilymphatic duct connects the scala tympani with the subarachnoid space. The cochlear aqueduct runs a downward oblique course between the cochlea and the subarachnoid space. CT has allowed the course of the cochlear aqueduct to be divided into four segments (2). The *lateral orifice* is the narrow opening of the bony aqueduct into the basal turn of the cochlea. It is located along the anteroinferior edge of the scala tympani immediately anterior to the crest of the attachment of the round window (4). The lateral orifice opens into the *otic capsule* segment, which courses medially through the labyrinthine bone. The otic capsule segment becomes continuous with the *petrous apex* segment, medially. The petrous apex segment courses through bone, which may be either pneumatized or filled with marrow. The petrous apex segment opens into the subarachnoid space adjacent to the pars nervosa of the jugular foramen via the funnel-shaped medial orifice (2).

Enlargement of the cochlear aqueduct is a controversial topic, with experienced investigators suggesting that this developmental anomaly is perhaps a "nonexistent malformation" (2). Evaluation of the normal CT appearance of the cochlear aqueduct on high-resolution studies (1.5-mm-thick sections) performed by Jackler and Hwang (2) showed that the diameter of the cochlear aqueduct is inconsistent and dependent on the specific segment being studied. This is consistent with results obtained by previous investigators (4). The otic capsule, petrous apex, and lateral orifice portions of the cochlear aqueduct were not visualized by Jackler and Hwang in a high percentage of their patients (44%, 23%, and 64%, respectively) (2). The complete course of the cochlear aqueduct was only seen throughout its entirety

Received October 19, 1996; accepted after revision February 14, 1997.

From the Departments of Radiology (S.K.M., H.C.B., J.A.) and Surgery (V.H.C.), University of North Carolina School of Medicine, Chapel Hill.

Address reprint requests to Suresh K. Mukherji, MD, Department of Radiology, 3324 Infirmary CB #7510, University of North Carolina School of Medicine, Chapel Hill, NC 27599.

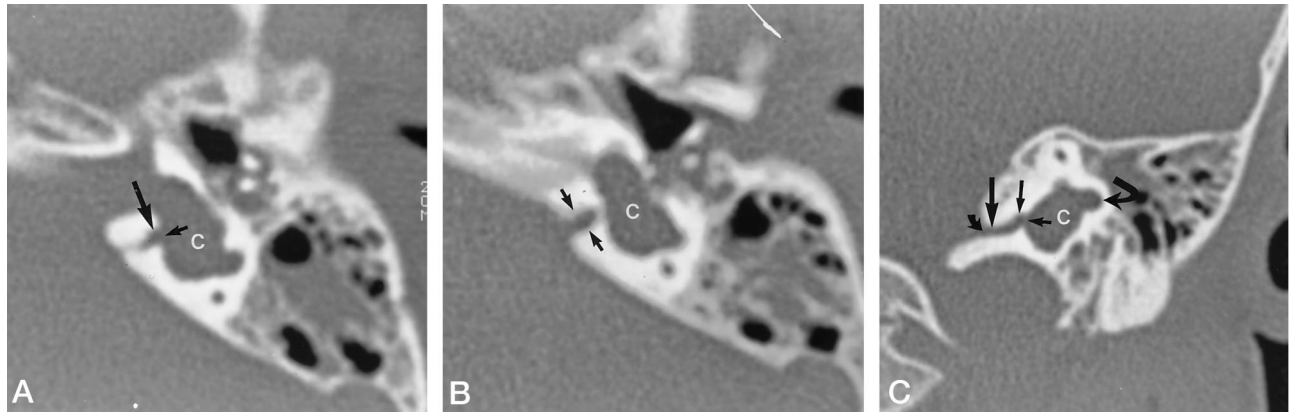


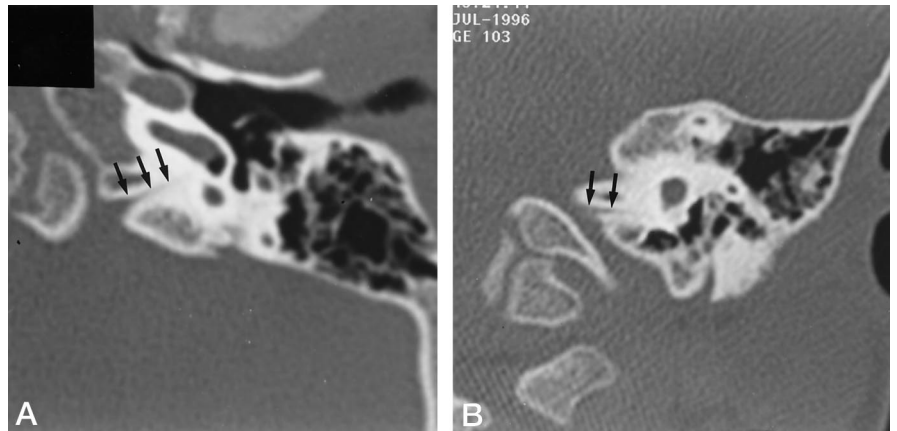
FIG 1. CT findings of enlarged cochlear aqueduct in an 18-month-old boy.

A, Axial scan obtained through the temporal bone shows dilatation of the lateral orifice (*small arrow*) and otic segment (*large arrow*) of the cochlear aqueduct. Note the associated common cavity malformation (C) of the inner ear. On otoscopic examination, the soft-tissue attenuation surrounding the ossicles was thought to represent fluid in the middle ear cavity rather than cholesteatoma.

B, Axial scan obtained 1 mm inferior to A shows the dilated duct is continuous with the funnel-shaped medial orifice (*arrows*) that opens into the region of the jugular foramen. The jugular foramen and the pars nervosa were not malformed (not shown) (C indicates common cavity malformation). Compare Figure 1A and B with the normal appearance of the cochlear aqueduct on the axial scan shown in Figure 2A.

C, Coronal scan shows diffuse dilatation throughout the course of the cochlear aqueduct (*smallest straight arrow* indicates lateral orifice; *medium-sized straight arrow*, otic segment; *large straight arrow*, petrous apex segment; *small curved arrow*, medial orifice; and *large curved arrow*, dysplastic semicircular canal). The diameter of the cochlear aqueduct at the midotic segment measures 1.2 mm. Compare this with the normal appearance of the cochlear aqueduct on the coronal study shown in Figure 2B.

FIG 2. CT appearance of normal cochlear aqueduct. Axial (A) and coronal (B) scans show the normal appearance of the cochlear aqueduct (*arrows*) in a 20-month-old patient examined for cholesteatoma of the contralateral ear (not shown). Note the gradual widening of the cochlear aqueduct on the axial scan as the duct courses medially.



in 31% of the patients studied (2). This inability to see portions of the cochlear aqueduct is most likely due to its small diameter, which, on anatomic studies, has been reported to be between 0.1 and 0.2 mm at its midportion (2, 5, 6). The most visible portion of the cochlear aqueduct is the medial orifice, which was identified in 97% of patients and has a mean diameter of 4.5 mm (range, 0 to 11 mm) (2). These findings led the authors to dispute previous claims of an enlarged cochlear aqueduct based on a wide medial aperture (2). They believed that prior claims of an enlarged cochlear aqueduct based solely on widening of the medial aperture could be accounted for by this normal variability, and justifiably concluded that the entity of an "enlarged cochlear aqueduct" must be questioned, as they were unable to identify a "single published image" of an enlarged cochlear aqueduct that could be considered normal by their measurements (2).

The appearance of the cochlear aqueduct in our patient is different from the appearance reported previously (2). The complete course of the cochlear aqueduct was visible from the lateral orifice to the medial aperture. The diameter, obtained at the midportion, was 1.2 mm, which is

significantly larger than measurements based on anatomical studies (0.1 to 0.2 mm) (5, 6). To corroborate our observations, we measured the diameter of the midotic segment of the cochlear aqueduct in 50 temporal bones imaged by using 1-mm-thick contiguous axial CT sections. These patients (n = 27) were being examined for signs and symptoms other than congenital or sensorineural hearing loss. The midotic segment was seen in 33 (66%) of the 50 temporal bones. When visible, the midotic portion of the cochlear aqueduct was seen on CT scans as a very thin lucent line that courses from the basal turn of the cochlea to the funnel-shaped medial orifice (Fig 2). The average mean diameter of the midotic segment of the visualized aqueducts was 0.56 ± 0.26 mm. These findings lend support to our supposition that the cochlear aqueduct in our patient was enlarged.

Despite the lack of pathologic correlation, we believe that the dilated canal illustrated in our case is due to an enlarged cochlear aqueduct. We think the appearance can be explained by a developmental arrest in the embryogenesis of the primitive cochlear aqueduct and its embryonic contents (6). In the 16- to 18-week fetus, the primitive

cochlear aqueduct contains the periotic duct, the inferior cochlear vein, and the tympanomeningeal fissure (Hyrtl's fissure). At 20 weeks' gestation, progressive ossification of the otic capsule leads to separation of the inferior cochlear vein from the primitive cochlear aqueduct. This results in the formation of a separate parallel bony canal for the inferior cochlear vein (Cotugno's canal, or first accessory canal) (6, 7). The bony covering of Cotugno's canal forms the medial border of the cochlear aqueduct. Progressive otic capsule ossification also leads to concurrent obliteration of Hyrtl's fissure and formation of the lateral wall of the cochlear aqueduct (6, 7). This partitioning of the primitive cochlear aqueduct corresponds with a sixfold reduction in its diameter between the 16th and 26th weeks of gestation (6). An arrest in development prior to partitioning of the cochlear aqueduct would prevent normal regression in size and result in an abnormally enlarged structure that contains its embryonic contents. This rationale is supported by the associated common cavity malformation, which results from anomalous development of the otic capsule prior to the 23rd week of gestation (8).

The association between an enlarged cochlear aqueduct and inner ear malformation has been questioned because of the separate embryological origins of the cochlear aqueduct and membranous labyrinth (9). The membranous labyrinth is derived from the otic vesicle. The perilymphatic duct initially appears as an outpouching of the subarachnoid space and is considered an extension of the subarachnoid space (2). The cochlear aqueduct forms in the mesoderm surrounding the perilymphatic duct and gradually ossifies during embryogenesis. Because of the lack of a common embryologic progenitor for both the membranous labyrinth and the perilymphatic duct, some investigators have suggested that there is no association between congenital inner ear dysplasias and malformations of the cochlear aqueduct (2, 9). This observation appears well supported by the abundance of reported cases of congenital inner ear dysplasias and the rarity of similar malformations of the cochlear aqueduct. In our case, however, the enlarged cochlear aqueduct was associated with a severe complex congenital inner ear dysplasia (Fig 1).

The cochlear aqueduct provides a conduit between the posterior fossa and the inner ear, thereby permitting transmission of perilymphatic fluid, which originates partly from cerebrospinal fluid into the inner ear (10, 11). In the adult, the perilymphatic duct is filled with a loose mesh of connective tissue that, although permeable to fluid, limits the patency of the cochlear aqueduct (2). The narrow diameter of the cochlear aqueduct is thought to buffer the inner ear from the wide pressure variations present within the posterior fossa subarachnoid spaces (1, 4, 12). A patent cochlear aqueduct has been suggested as a potential pathway that may allow transmission of bacterial infection between the subarachnoid space and perilymph contained within the inner ear (12, 13). After a subarachnoid hemorrhage, red blood cells may also traverse the cochlear aqueduct to reach the basal turn of the cochlea (14, 15). Cerebrospinal fluid otorrhea as a complication of stapedectomy (stapes gusher) has been suggested to be the result of increased inner ear pressures caused by an enlarged and overly patent cochlear aqueduct (1). However, owing to the lack of conclusive imaging findings showing enlargement of the cochlear aqueduct, its role as a route for perilymph fistula formation has been discounted (2, 16). The pathogenesis of perilymph

fistulas is thought to result from a direct communication between the subarachnoid space and inner ear caused by a defect in the bony partition of the fundus of the IAC (2, 16). We think it likely that the left ear of our patient would be at high risk for developing a perilymph fistula after cochlear implantation because of the presence of both an enlarged cochlear aqueduct and a defect in the bony partition of the fundus of the IAC.

In summary, we described congenital enlargement of a canal in the expected location of the cochlear aqueduct associated with a severe inner ear malformation. Our findings suggest that, contrary to previous reports, enlargement of the cochlear aqueduct is a distinct entity that may be detected by high-resolution CT (1.0-mm-thick sections). Additionally, an enlarged cochlear aqueduct may be associated with inner ear malformations, and evaluation of the cochlear aqueduct should be considered part of the routine imaging examination in patients with congenital sensorineural hearing loss. However, isolated enlargement of the cochlear aqueduct has still not been documented by imaging, nor has it been implicated as an actual cause of perilymph/cerebrospinal fluid fistula.

References

1. Farrior JB, Endicott JN. **Congenital mixed deafness: cerebrospinal fluid otorrhea: ablation of the aqueduct of the cochlea.** *Laryngoscope* 1971;81:684-699
2. Jackler RK, Hwang PH. **Enlargement of the cochlear aqueduct: fact or fiction?** *Otolaryngol Head Neck Surg* 1993;109:14-25
3. Swartz JD, Harnsberger HR. **The otic capsule and otodystrophies.** In: *Imaging of the Temporal Bone*. 2nd ed. New York, NY: Thieme; 1992:192-247
4. Bhimani S, Virapongse C, Sarwar M. **High-resolution computed tomographic appearance of normal cochlear aqueduct.** *AJNR Am J Neuroradiol* 1984;5:715-720
5. Muren C, Wilbrand H. **Anatomic variations of the human cochlear aqueduct.** *Acta Radiol Diagn* 1986;27:11-18
6. Spector GJ, Lee D, Carr C, et al. **Later stages of development of the periotic duct and its adjacent area in the human fetus.** *Laryngoscope* 1980;5:1-31
7. Rask-Anderson H, Stahle J, Wilbrand H. **Human cochlear aqueduct and its accessory canals.** *Ann Otol Rhinol Laryngol* 1977;86:1-16
8. Kenna MA. **Embryology and developmental anatomy of the ear.** In: Bluestone CD, Stool SE, Scheetz MD, eds. *Pediatric Otolaryngology*. Philadelphia, Pa: Saunders;1990;1:77-87
9. Schuknecht HF, Reisser C. **The morphologic basis for perilymphatic gushers and oozers.** *Adv Otorhinolaryngol* 1988;39:1-12
10. Park TS, Hoffman HJ, Humphreys RP, et al. **Spontaneous cerebrospinal fluid otorrhea in association with a congenital defect of the cochlear aqueduct and Mondini dysplasia.** *Neurosurgery* 1982;11:356-362
11. Carlborg BI, Farmer JC. **Transmission of cerebrospinal fluid pressure via the cochlear aqueduct and endolymphatic sac.** *Am J Otolaryngol* 1983;4:273-282
12. Yangita N, Futatsugi Y, Nishimura S, Handoh M, Yoki H. **Defense mechanism of the cochlear aqueduct against infection: a morphological study in the guinea pig.** *ORL J Otorhinolaryngol Relat Spec* 1984;46:294-301
13. Bhatt S, Halpin C, Hsu W, et al. **Hearing loss and pneumococcal meningitis: an animal model.** *Laryngoscope* 1991;101:1285-1292
14. Holden HB, Schuknecht HF. **Distribution pattern of blood in the inner ear following spontaneous subarachnoid hemorrhage.** *J Laryngol Otol* 1968;82:321-329
15. Perlman HB, Lindsay JR. **Relation of the internal ear spaces to the meninges.** *Arch Otolaryngol* 1939;29:12-18
16. Phelps PD. **Congenital cerebrospinal fluid fistula of the petrous temporal bone.** *Clin Otolaryngol* 1986;11:79-82