

Case Report

Coexistent Holoprosencephaly and Chiari II Malformation

Nancy Rollins, Jeanne Joglar, and Jeffery Perlman

Summary: Chiari II malformations and holoprosencephaly have been considered to be brain malformations that differ with respect to teratogenic insult, embryologic mechanism, and morphology. We herein describe coexistent Chiari II malformation and holoprosencephaly that occurred in a viable infant. A review of the literature regarding Chiari II malformations and holoprosencephaly suggests that a disturbance to the mesenchyme in early embryologic life may be the cause of both malformations.

Meningomyelocele and the almost invariable coexistent Chiari II malformation constitute one of the most common severe CNS malformations. Holoprosencephaly is a less common but equally complex CNS malformation. According to the embryologic literature, Chiari II malformation and holoprosencephaly differ with respect to timing of the teratogenic insult and the proposed developmental aberration (1, 2). We herein report a live-born infant with a lumbar myelomeningocele and Chiari II malformation associated with holoprosencephaly. To the best of our knowledge, this is the first reported occurrence in a viable infant.

Case Report

A Hispanic female patient was born at term to a 19-year-old G1P0 mother by uncomplicated vaginal delivery. The parents were not consanguineous. The mother reported no problems during pregnancy, although there was no prenatal care on record. The mother was mildly retarded and had a midline nasal furrow. The infant's birth weight was 2830 g. The infant had spontaneous respiration and was stable with Apgar scores of 8 and 8 at 1 and 5 minutes, respectively, after birth. An open-lumbar myelomeningocele was noted at birth along with flaccid lower extremities, diminished anal wink, a shallow sloping forehead, and otherwise normal facies. The head circumference was 32 cm (15th percentile). Cranial sonography showed dilation of the lateral ventricles and temporal horns, thalamic fusion, and incomplete separation of the frontal cortex. The myelomeningocele was closed on day 1 of life, and a ventriculoperitoneal shunt for progressive hydrocephalus was placed on day 5 of life. The patient fed poorly but had no

episodes of hypothalamic or pituitary dysfunction. Intermittent episodes of apnea prompted MR imaging at 3 weeks of age.

MR imaging was performed without sedation on a 1.5-T unit using T1-weighted spin-echo sequences in the sagittal and axial planes and a T2-weighted axial fast spin-echo sequence. Sagittal images showed cerebellar hypoplasia with caudal herniation of the cerebellum down to the posterior arch of C3, an attenuated caudally displaced fourth ventricle, and a beaked tectal plate, consistent with a Chiari II malformation (Fig 1A). The supraoptic recess, anterior third ventricle, lamina terminalis, and anterior commissure were present, although the anterior commissure projected into the third ventricle and appeared duplicated. Axial images showed fusion of the posterior frontal cortex and white matter, septal and callosal agenesis, absent interhemispheric falx, and dorsal thalamic fusion, consistent with holoprosencephaly (Fig 1B), most likely of the lobar type. There were no anomalous midline cysts. Despite counseling regarding the infant's poor prognosis, the mother requested further treatment for the child's intermittent apneic episodes. Therefore, suboccipital decompression and upper cervical laminectomy were performed with placement of a dural patch at 4 weeks of age. The apnea improved postoperatively, and the patient was discharged home at 6 weeks of age. The subsequent clinical course was marked by microcephaly, seizures, global developmental delay, and intermittent apnea. Repeat MR imaging performed at 13 months of age with the patient under general anesthesia (Fig 1C) showed the abnormalities observed on the initial MR images as well as diffuse cortical dysplasia, absent olfactory sulci with hypoplasia of the olfactory nerves, and hypoplastic hippocampi. The results of the chromosomal analysis were normal.

Discussion

This is the first reported case of a Chiari II malformation and holoprosencephaly in a liveborn infant. These malformations have been reported to coexist in nonviable products of gestation. Osaka et al (3) studied 92 human embryos or fetuses with myeloschisis that were products of spontaneous or therapeutic abortions. Myeloschisis was defined as eversion and overgrowth of the unfused neural plate. Eighteen of the 92 embryos or fetuses with myeloschisis had holoprosencephaly. The diagnosis of holoprosencephaly was based on characteristic facial anomalies, including cyclopia, proboscis, and hypotelorism associated with disturbed diverticulation of the prosencephalon. The prosencephalic defects were not further characterized. The embryos with myeloschisis showed a higher incidence of holoprosencephaly than did the fetuses with myeloschisis, suggesting that the malformations were incompatible with later fetal development. None of the embryos with myeloschisis showed evidence of hydrocephalous or a Chiari II malformation, indi-

Received February 24, 1999; accepted after revision June 17.

From the Departments of Radiology (N.R., J.J.) and Pediatrics (J.P.), Children's Medical Center and the University of Texas Southwestern Medical School, Dallas, TX.

Address reprint requests to Nancy Rollins, MD, Department of Radiology, Children's Medical Center, 1935 Motor Street, Dallas, TX 75235.

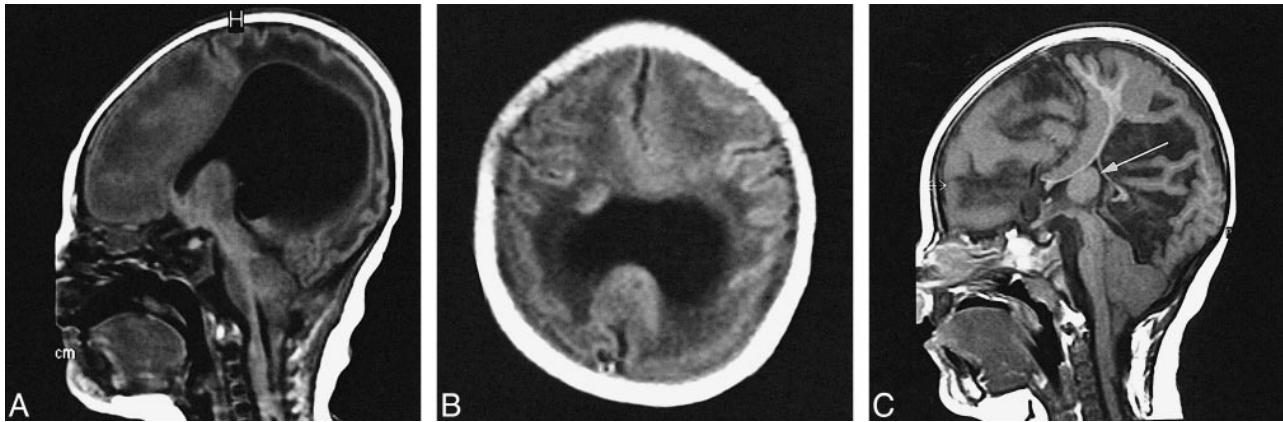


FIG 1. MR images from a case of coexistent Chiari II malformation and holoprosencephaly that occurred in a viable infant.

A, Stigmata of the Chiari II malformation. Sagittal T1-weighted MR image shows elongated caudally displaced effaced fourth ventricle and caudal herniation of the cerebellum.

B, Manifestations of holoprosencephaly. Axial T1-weighted MR image shows absent interhemispheric falx and partial fusion of frontal cortex and white matter.

C, Follow-up image obtained at 13 months of age. Sagittal T1-weighted MR image shows poor myelination and extensive polymicrogyria along the mesial surfaces of the cerebral hemispheres. Arrow indicates the large massa intermedia.

ating that the developmental aberrations that result in Chiari II malformation occur later in embryologic development or in early fetal life (3). The severity of these coexistent malformations is usually incompatible with life and presumably accounts for the rarity with which these malformations are reported to occur together. Other cases of holoprosencephaly associated with spinal anomalies include a liveborn term male infant with caudal regression, renal and cardiac anomalies, and lobar holoprosencephaly and a stillborn female infant with a lumbar meningocele, cebocephaly, and lobar holoprosencephaly (4, 5).

Morphologic abnormalities common to holoprosencephaly and Chiari II malformation include dysplasias of cytoarchitecture, dysgenetic or absent corpus callosum and midline structures, and hydrocephalus of variable severity (2, 6). These abnormalities are nonspecific and occur in association with numerous syndromic and nonsyndromic cerebral malformations. The most intriguing similarity between the two entities is the thickened massa intermedia common in cases of Chiari II malformation and the dorsal thalamic fusion usually present in the variants of holoprosencephaly. Yakovlev (7) commented that holoprosencephaly is characterized by ventral and anterior thalami, which are bilateral and separate, whereas the medial dorsal, centrum medium, and midline nuclei form an undivided median mass. This undivided median mass presumably represents the thickened massa intermedia common in cases of Chiari II malformation. The mass intermedia may be so thickened in patients with Chiari II malformations that the caudal thalami appear virtually fused. Frank atresia of the third ventricle has been associated with myelodysplasia and Chiari II malformations. Gilbert et al (6) reported that four of 25 autopsied patients with myelomeningocele had atresia of the third ventricle, although no mention was made of incomplete

separation of the cerebral hemisphere or other stigmata of holoprosencephaly.

The most commonly accepted unifying theory for the embryologic aberration causing Chiari II malformation was proposed by McClone and Knepper (1), who concluded that the intracranial abnormalities found in patients with myelomeningoceles and Chiari II malformations are the result of incomplete closure of the neural tube and the resultant mechanical derangements. Failure of neural tube closure is thought to prevent the transient closure of the central canal that is essential for distension of the primitive ventricular system, and lack of mechanical support for the developing cerebrum results in cerebral dysgenesis. McClone and Knepper (1) suggested that the small third ventricle frequently observed in patients with Chiari II malformations results from failure of overall ventricular distension during embryologic life; the thalami remain approximated in contact to form a large massa intermedia. Embryologic studies, however, indicate the thalami are derived from thickened lateral walls of the original caudal prosencephalic vesicle and therefore form as paired structures that undergo secondary fusion, united by a bridge across the median plane, forming the massa intermedia (8). The hypothesis presented by McClone and Knepper (1) about failure of closure of the central canal does not account for the diverse concomitant malformations of cytoarchitecture and midline structures that are common in cases of Chiari II malformation nor does it account for the numerous associated visceral malformations. In their work regarding the delayed *Spotch* mouse embryo with sacral neural tube defects, McClone and Knepper (1) observed differences in the time and type of expression of several glycoproteins on the cell surfaces and within the extracellular matrix and concluded that defective neurulation was the result of an aberration in carbohydrate appearance or expression. The con-

comitant cerebral and cranial malformations that constitute Chiari II malformation may also arise from this defective glycosylation of cells, which is presumably not limited to the site of defective neurulation and tube closure but is found in cells throughout the embryo.

There is less unanimity of opinion regarding the cause of holoprosencephaly than there is regarding the cause of Chiari II malformation. The teratogenic insult or the expression of defective genetic encoding, which results in holoprosencephaly, occurs by the fourth week after conception (9). According to Probst (2), holoprosencephaly is the result of severe median prosencephalic dysgenesis under the organizing influence of prechordal mesoderm, whereas Muller and O'Rahilly (9) concluded that an early defect in the mesencephalic neural crest may be the genesis of holoprosencephaly. Leech and Shuman (10) suggested that aprosencephaly, holoprosencephaly, septo-optic dysplasia, and agenesis of the corpus callosum constitute a spectrum of anomalies caused by maldevelopment of the prosencephalon but stated that holoprosencephaly cannot represent a failure of evagination of the telencephalic vesicles or failure of cleavage of the prosencephalon or both. Barkovich and Quint (11) suggested that lack of formation of the interhemispheric fissure is the pivotal anomaly in holoprosencephaly and that it results from the paucity of mesenchyme that normally invests the deepening interhemispheric groove separating the developing cerebral hemispheres.

The extreme variability in clinical presentation of holoprosencephaly is notable, and the anatomic abnormalities considered diagnostic of holoprosencephaly vary according to the series of specimens studied (2, 7, 9–11). Muller and O'Rahilly (9) stated that an undivided telencephalon is the hallmark of the prosencephalic defects, whereas fusion of the thalami is an inconstant finding. Probst (2) concluded that the prosencephalic defects were invariably associated with some degree of thalamic fusion. Dorsal thalamic fusion, however, is known to occur in the absence of fusion of the frontal lobes, and frontal lobe fusion may occur without dorsal thalamic fusion. Yakovlev (7) noted profound disorganization of the mesodermal and ectodermal tissue derivatives of the rostral median zone of the prosencephalic plate. The most extreme disorganization was within the frontal lobes (that portion of the brain most intimately related in development to the prosencephalic plate), whereas the dorsal and caudal portions of the cerebral mantle were often relatively normal. This regional selectivity of failure of midline cleavage may explain the apparent preservation of dorsal midline commissural fibers reported in some cases of holoprosencephaly (12). An unusual variant of lobar holoprosencephaly characterized by preservation of portions of the commissural fibers of the corpus callosum and fusion of the middle portions of the cerebral hemi-

spheres, with and without thalamic fusion, has been described by Barkovich and Quint (11).

The role of mesenchyme in the pathogenesis of Chiari II malformation has not been addressed in the literature. Mesenchyme is an unorganized mass of pluripotential cells in a gelatinous matrix, which derives from the prechordal plate, primitive streak, and neural crest (8). Mesenchyme appears before closure of the neural folds; proliferation of paraxial mesenchyme causes elevation of neural folds, which precedes closure of the neural tube approximately 22 days after conception (8). The importance of the supportive role of mesenchyme in the initial phase of neurulation in the rat has been stressed by embryologists who note that mesenchymal deficiency may prevent further neurulation (13). Mesenchyme proliferates around the brain stem and surrounds the telencephalon filling the interhemispheric fissure and will eventually provide support for the interhemispheric falx and commissural fibers that connect the cerebral hemispheres across the midline. Between 37 and 41 days, the entire brain is surrounded by mesenchyme (8). Mesenchymal condensations in the basal areas of the developing brain are the precursors of the future chondrocranium (8). Mesenchyme invests the roof of the fourth ventricle and gives rise to the tentorium, meninges, and cranial nerve ganglia. Ultimately, mesenchyme will ensheath the neural tube along its entire course. Differentiation and specialization of mesenchyme, when it arrives at its final destination, depends on cellular neighbors, whereas mesenchyme also induces and controls differentiation of adjacent cells. Thus, the expression of the normal developmental potential of the neuroectoderm is critically dependent on the ontogenic integrity of the supporting mesenchyme. Support for this concept is illustrated in studies in which destruction of cerebellar meningeal cells with hydroxydopamine in hamsters prevents normal lamination and folia formation in the cerebellum and disorganization of medullary fibers (14). Chiari II malformation is characterized by mesodermal dysplasia and premature condensation of the basilar skull anlagen, small and dysplastic lower cranial nerve ganglia, deficient tentorium cerebelli, hypoplastic and dysmorphic cerebellum, and thickened basal meninges (6). These anomalies all are attributable to defective or deficient mesenchyme, which presumably deprived the skull base, hindbrain, and rhombencephalon of normal inductive effects.

Investigators have chosen to stress the morphologic differences in complex CNS malformations and to devise a classification based on differences rather than similarities; hence the classic teaching that holoprosencephaly and Chiari II malformation differ in mechanism, timing, and morphology. Just as Barkovich and Quint (11) suggested that anomalies of mesenchyme account for the holoprosencephalies, defective or deficient mesenchyme may also account for Chiari II malformation.

References

1. McLone DG, Knepper PA. **The cause of Chiari II malformation: a unified theory.** *Pediatr Neurosci* 1989;15:1-12
2. Probst FP. **The Proencephalies: Morphology, Neuroradiological Appearances and Differential Diagnosis.** Baltimore: Williams & Wilkins; 1979
3. Osaka J, Tanimura T, Hirayama A, et al. **Myelomeningocele before birth.** *J Neurosurg* 1978;49:711-724
4. Harlow CL, Partington MD, Thieme GA. **Lumbosacral agenesis: clinical characteristics, imaging, and embryogenesis.** *Pediatr Neurosurg* 1995;23:140-147
5. Chen CP, Shih SL, Liu FF, et al. **Cebocephaly, alobar holoprosencephaly, spina bifida, and sirenomelia in a stillbirth.** *J Med Genet* 1997;34:252-255
6. Gilbert JN, Jones KL, Rorke LB, et al. **Central nervous system anomalies associated with meningomyelocele, hydrocephalus, and the arnold-chiari malformation: reappraisal of theories regarding the pathogenesis of posterior neural tube closure defects.** *Neurosurgery* 1986;18:559-563
7. Yakovlev PI. **Pathoarchitectonic studies of cerebral malformations. III. Arrhincephalies.** *J Neuropathol Exp Neurol* 1959;18:22-55
8. Hamilton, Boyd, and Mossman's human embryology: **prenatal development of form and holoprosencephaly.** *AJNR Am J Neuroradiol* 1993;14:4431-4409
9. Muller F, O'Rahilly R. **Mediobasal prosencephalic defects, including holoprosencephaly and cyclopia, in relation to the development of the human forebrain.** *Am J Anat* 1989;185:391-414
10. Leech RW, Shuman RM. **Holoprosencephaly and related midline cerebral anomalies: a review.** *J Child Neurol* 1986;1:3-18
11. Barkovich AJ, Quint DJ. **Middle interhemispheric fusion: an unusual variant of holoprosencephaly.** *AJNR Am J Neuroradiol* 1993;14:431-440
12. Barkovich AJ. **Atypical callosal agenesis: analysis of MR findings in six cases and their relationship to holoprosencephaly.** *AJNR Am J Neuroradiol* 1990;11:333-340
13. O' Rahilly R, Muller F. **The meninges in human development.** *J Neuropathol Exp Neurol* 1986;45:588-608
14. Doeberitz C, Sievers J, Salder M, et al. **Destruction of meningeal cells over the newborn hamster cerebellum with 6-hydroxydopamine prevents foliation and lamination in the rostral cerebellum.** *Neuroscience* 1986;17:409-426