

Superselective Continuous Arterial Infusion Chemotherapy through the Superficial Temporal Artery for Oral Cavity Tumors

Tatsuhiko Nakasato, Kenichi Katoh, Miyuki Sone, Shigeru Ehara, Yoshiharu Tamakawa, Hideki Hoshi, and Saburoh Sekiyama

BACKGROUND AND PURPOSE: High-dose intraarterial chemotherapy with repeated one-shot infusion may be useful for treating head and neck tumors. We evaluated the efficacy of superselective continuous arterial infusion chemotherapy administered via a coaxial catheter system and compared the results with those of subselective catheterization for treatment of oral cavity tumors.

METHODS: Forty-nine consecutive patients with tumors of the oral cavity (clinical stage I, 12 cases; stage II, 19 cases; stage III, six cases; stage IV, 12 cases) were treated by arterial infusion chemotherapy. After a guiding catheter was advanced into the superficial temporal artery, superselective catheterization was performed using a coaxial system microcatheter. Superselective catheterization was accomplished in 34 cases, and was unsuccessful in 15, owing to difficulties in performing catheterization or to multiple feeding arteries. In the latter cases, the tip of the catheter was placed near the origin of the feeding arteries (subselective catheterization).

RESULTS: Thirty (88%) of 34 patients had a complete response to superselective arterial infusion chemotherapy and two (6%) had a partial response. Twelve (80%) of 15 patients had a complete response to subselective arterial infusion chemotherapy and three (20%) had a partial response. Local recurrence was more frequent after subselective treatment (13%) than after superselective (6%) treatment.

CONCLUSION: Superselective continuous arterial infusion chemotherapy may be suitable for local control of oral cavity tumors, with a low rate of recurrence.

Intraarterial infusion chemotherapy has the advantage of delivering a high concentration of chemotherapeutic agents into the tumor bed with fewer systemic toxic effects than seen with systemic chemotherapy. Intraarterial chemotherapy delivered into the external carotid artery (ECA) is an established procedure (1–3). Current improvements in catheter design, including introduction of the coaxial system, have enabled the performance of retrograde selective catheterization into the main tumor feeders arising from the ECA, such as the superficial temporal artery (STA). Continuous infusion chemotherapy by use of a selective technique

is considered an ideal method for treating malignant neoplasms of the head and neck (4). However, superselective catheterization is occasionally made difficult by complex anatomy or multiple feeding arteries. The purpose of this study was to assess the efficacy of superselective continuous arterial infusion chemotherapy using a coaxial catheter system and to compare its efficacy with that of the subselective technique.

Methods

Between January 1991 and November 1998, 49 consecutive patients (29 men and 20 women; 23–83 years old; mean age, 60 years) with oral cavity carcinomas (tongue, 27; gingiva, 11; buccal mucosa, five; floor of mouth, two; oropharynx, four) were treated by arterial infusion chemotherapy. Indications for treatment included histologically established carcinoma and no distant metastasis. All the tumors were squamous cell carcinomas. The classification systems of the Union International Contre le Cancer, 1987, and the Japan Society for Head and Neck Cancer, 1991, were used for clinical staging, and no differences were noted. Twelve patients had stage I carcinoma, 19 had stage II, six had stage III, and 12 had stage IV. Exten-

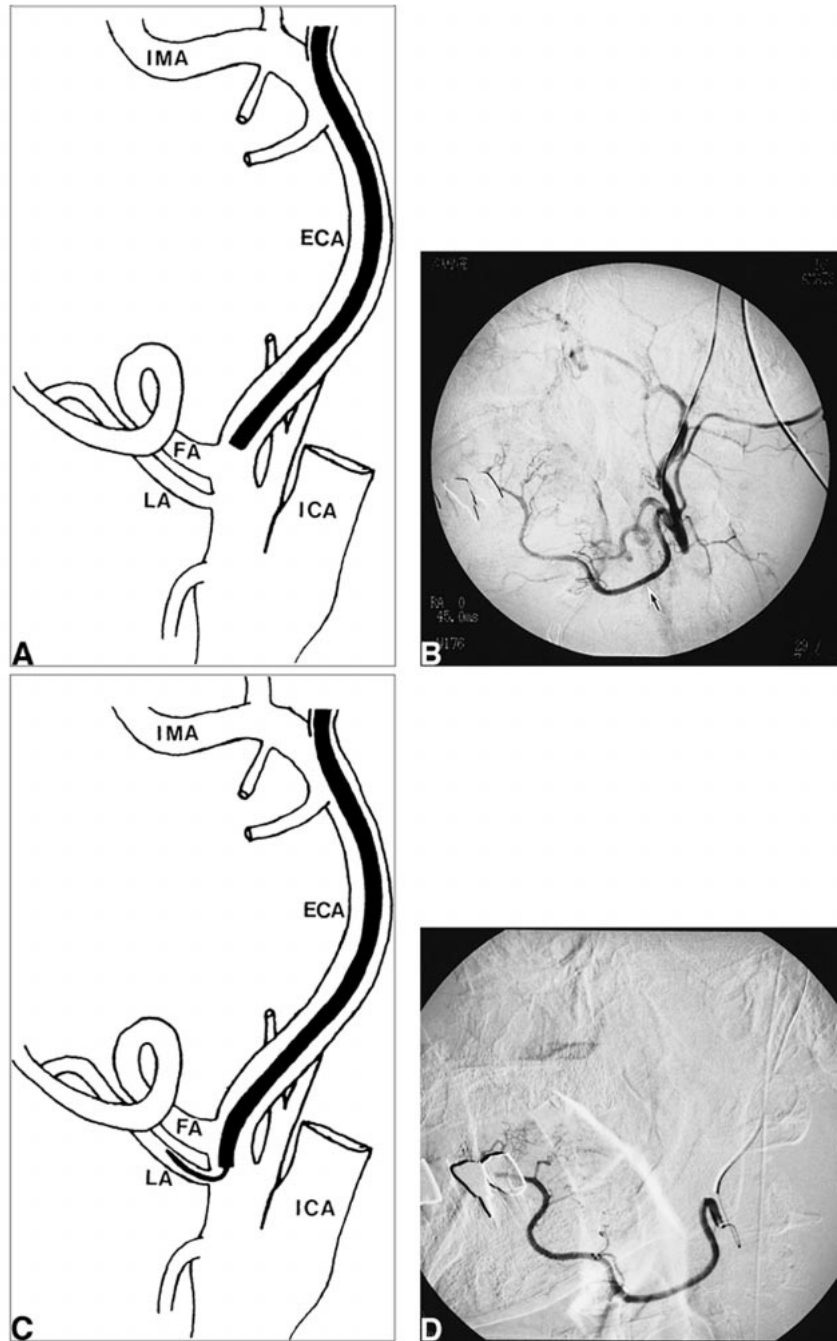
Received January 21, 2000; accepted after revision May 10.

From the Department of Radiology, Iwate Medical University School of Medicine (T.N., K.K., M.S., S.E., Y.T.); and the Department of Oral Surgery II, Iwate Medical University School of Dentistry (H.H., S.S.), Morioka, Japan.

Address reprint requests to Tatsuhiko Nakasato, MD, Department of Radiology, Iwate Medical University School of Medicine, 19–1 Uchimarui, Morioka 020–8505, Japan.

FIG 1. Superselective catheterization in a 62-year-old man with tongue cancer (T1N0M0).

A–D, The guiding catheter was placed near the origin of the target vessel by using a guidewire (A). A vascular mapping study was done of the ECA (arrow, LA; B), after which a coaxial microcatheter was advanced through the guiding catheter into the feeding artery (C), and superselective lingual arteriography was performed (D). ICA, internal carotid artery; ECA, stem of external carotid artery; LA, lingual artery; FA, facial artery; IMA, internal maxillary artery.



sion of the lesion into the surrounding tissue and cervical node was evaluated by CT, MR imaging, and sonography.

After inducing local anesthesia of the temporal region, a guiding catheter (UK-II catheter 16G, Unitica, Hyogo, Japan) was advanced into the STA, after which a main feeding artery was selectively catheterized using a coaxial system containing a 2.5F microcatheter (Fastracker-18, Target Therapeutics, Boston Scientific; Galway, Ireland) and a 0.014-inch Transend wire (Boston Scientific, Watertown, MA) or a 0.016-inch torquable guidewire (Radifocus guidewire M, GT wire angle, or double-angle type; Terumo, Tokyo, Japan) (Fig 1). For catheterization of the STA under fluoroscopic guidance, a 0.035-inch guidewire (Radifocus, angle type) was used to prevent angiospasm or dissection. Systemic heparinization was not performed during catheterization.

Superselective catheterization by microcatheter was confirmed with digital subtraction angiography after infusion of

contrast material and was found to be successful in 34 cases and unsuccessful in 15 (Table 1). In such cases, the tip of the microcatheter was placed near the origin of the feeding arteries (subselective catheterization). Unsuccessful catheterization was attributed to anatomic variations and to multiple feeding arteries.

No significant angiospasm or dissection occurred in any patient during manipulation of the guiding catheter or microcatheter. Selective catheterization was also confirmed by injection of a small amount of contrast medium and indigo carmine. After confirming the catheter position, bleomycin (5 mg/day for 6 days), methotrexate (20 or 50 mg/day for 2 days), and cisplatin (10 mg/day for 5 days) were infused continuously for one or two courses. Radiation therapy (40–60 Gy) was also administered during intraarterial chemotherapy (Fig 2). Patients were able to ambulate during arterial infusion owing to the attachment of an infusion pump to the microcatheter (Fig

TABLE 1: Patient Data

Primary Site	No. (%) of Cases	No. (%)		
		TNM (M0)		
		Tumor	Node	Stage
Tongue	27 (55)	T1 = 14 (29)	N0 = 42 (86)	I = 12 (24)
Gingiva	11 (23)	T2 = 20 (41)	N1 = 4 (8)	II = 19 (40)
Buccal mucosa	5 (10)	T3 = 5 (10)	N2b = 2 (4)	III = 6 (12)
Oral floor	2 (4)	T4 = 10 (20)	N2c = 1 (2)	IV = 12 (24)
Oropharynx	4 (8)

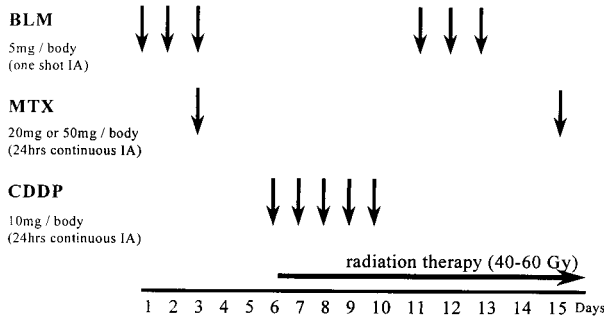


Fig 2. Protocols of chemotherapy and radiation therapy. *BLM*, bleomycin; *MTX*, methotrexate; *CDDP*, cisplatin.

3). Although such treatment may be performed on an outpatient basis, we treated our patients in the hospital, in accordance with our current clinical practice guidelines.

The position of the catheter and the patency of the vessel were checked by injection of indigo carmine on the first day of each course of chemotherapy. The skin and the catheter were sterilized every day and the catheter was filled with 2000 U of heparin to prevent coagulation. No additional antiplatelet medications were given.

Treatment results were assessed according to World Health Organization criteria. Results were classified as 1) complete response (disappearance of all tumor masses for at least 1 month); 2) partial response (a decrease of 50% or more in the product of the largest diameter and the perpendicular diameter of the measurable tumor for at least 1 month); 3) no change (a decrease of less than 50% or an increase of less than 25% in the diameter product of the lesion); or 4) progressive disease (an increase of more than 25% in the diameter product or de-

velopment of a new lesion). The Kaplan-Meier method was used to estimate survival rates.

Results

Among the 34 patients who had superselective arterial infusion chemotherapy, 30 (88%) had a complete response and two (6%) had a partial response, including four patients with a T3 tumor and six with a T4 tumor (Fig 4). Among the 15 patients who had subselective arterial infusion chemotherapy, 12 (80%) had a complete response and three (20%) had a partial response. Local recurrence was more frequent among those who were treated with the subselective technique: two (13%) from this group had a complete response versus two (6%) from the group who underwent the superselective procedure. After therapy, total dissection of the neck was performed in four patients who had a complete response and in three who had a partial response. Nodal metastases were observed in six patients who had a complete response (four from the superselective group and two from the subselective group).

The cumulative 5-year survival rate was 82% and 87% among those who had superselective and subselective therapy, respectively (no statistical significance by Wilcoxon test) (Table 2 and Fig 5).

A high complete response rate was observed among patients with stage I, II, and III tumors in

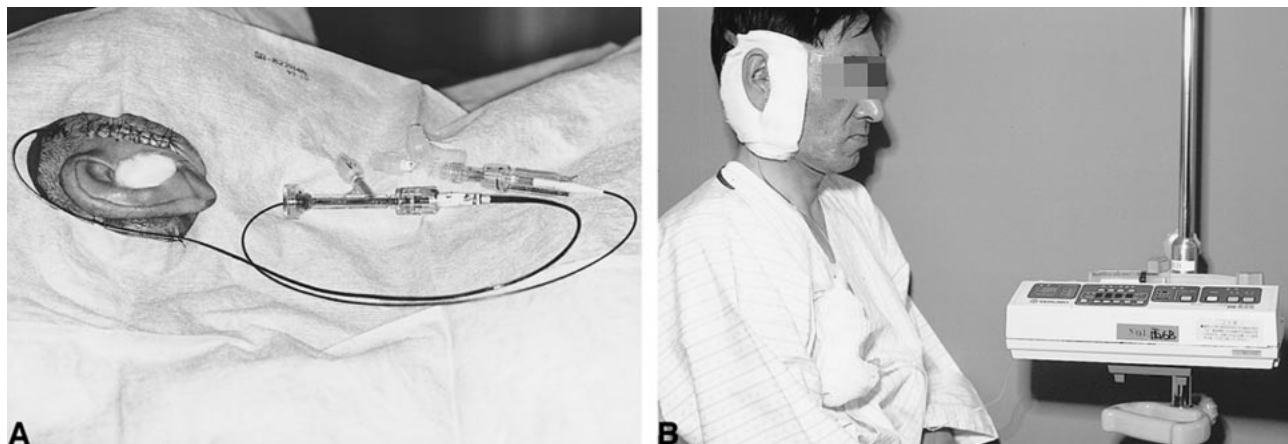


Fig 3. A and B, Photographs show infusion apparatus attached to catheter system (A) and a patient with a catheter placed by means of a coaxial system (B).

FIG 4. 64-year-old man with gingival cancer (T2N0M0, stage II). The tumor in the lower gingiva of the molar region disappeared after treatment.

A, Before treatment.

B, After two courses of chemotherapy with superselective catheterization and radiation therapy (40 Gy).

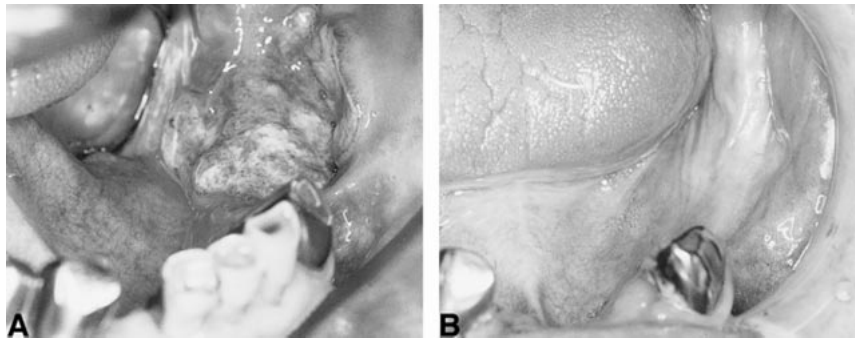


TABLE 2: Results of superselective and subselective arterial infusion chemotherapy

	Superselective, No. (%)	Subselective, No. (%)
Complete response	30 (88)	12 (80)
Partial response	2 (6)	3 (20)
No change	1 (3)	...
Progressive disease	1 (3)	...
Local recurrence	2 (6)	2 (13)
Nodal metastasis	4 (12)	2 (13)
5-year survival	82%	87%*
T3 plus T4	30%	34%

* Not statistically significant.

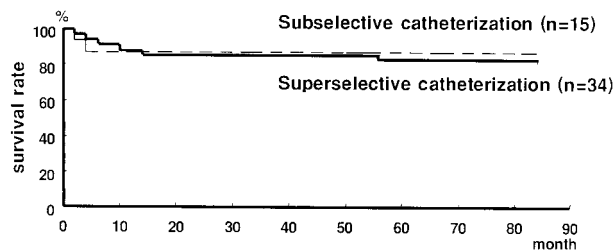


FIG 5. Overall survival rate of patients with cancer of the oral cavity.

TABLE 3: Staging of patients with complete response to arterial infusion chemotherapy

Stage	Superselective (n = 30 of 34)	Subselective (n = 12 of 15)
I	8/9 (89)	3/3 (100)
II	13/13 (100)	5/6 (83)
III	5/5 (100)	1/1 (100)
IV	4/7 (57)	3/5 (60)

both the superselective and subselective groups (Table 3). For patients with tongue cancer ($n = 27$), the complete response rate was 95% after the superselective technique, including three (25%) with T3 tumors and two with T4 tumors. After the subselective technique, the complete response rate was 57% among those with tongue cancer, including one patient (14%) with a T4 tumor (Table 4 and Fig 6). The cumulative 5-year survival rate for patients with tongue cancer was 80% in the super-

TABLE 4: Results of superselective and subselective arterial infusion chemotherapy in patients with tongue cancer

	Superselective, No. (%)	Subselective, No. (%)
Complete response	19 (95)	4 (57)
Partial response	1 (5)	3 (43)
5-year survival	80%	88%*
T3 plus T4	5 (25)	1 (14)

* Not statistically significant.

selective group and 88% in the subselective group (no statistical difference) (Fig 7).

No major neurologic or systemic complications were noted, except in three patients in whom pulmonary fibrosis developed. Minor side effects, such as nausea, vomiting, and reactive mucositis, were controlled by medication. The position of the catheter was confirmed by injection of indigo carmine, and repositioning was performed immediately under fluoroscopic guidance in one case.

Discussion

Recent advancements in coaxial microcatheter systems using various types of wires (ie, reshaped or double-angle type) have made them suitable for superselective catheterization of tortuous vessels; however, selective catheterization may still be difficult in cases of a sharply angled feeding artery (Fig 8). Sometimes, anatomic variations, such as a lingual artery with the appearance of a linguofacial trunk, seen in approximately 17% to 18% of patients (5, 6), also create difficulties in performing superselective catheterization. A good knowledge of vascular anatomy is important for determining which artery to catheterize, particularly in patients with gingival cancer.

The labial side of the lower gingiva, from the anterior to the premolar region, is supplied by the inferior labial artery, the submental artery from the facial artery, and the sublingual arteries from the lingual artery. The submental artery has some anastomoses with the sublingual system, with the middle mental branch, and with the inferior labial artery. The molar region of the gingiva is supplied by the buccal artery and by a direct branch of the facial artery. On the lingual side of the lower gin-

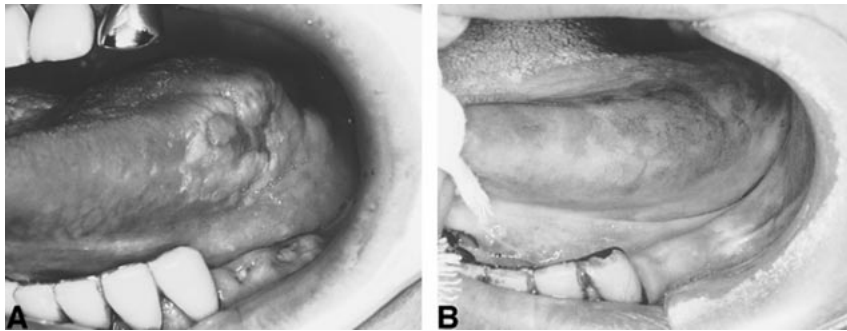


FIG 6. 72-year-old woman with tongue cancer (T1N1M0, stage III). The tumor in the lateral aspect of tongue was not detected after treatment.
 A, Before treatment.
 B, After two courses of chemotherapy with superselective catheterization and radiation therapy (60 Gy).

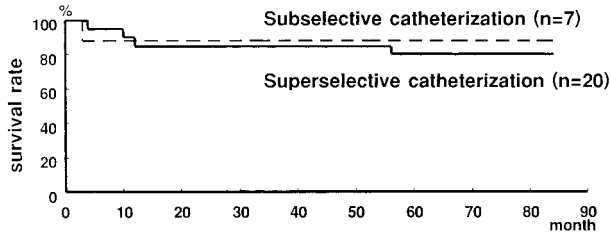


FIG 7. Overall survival rate of patients with tongue cancer.

giva, the sublingual artery is the main feeder. These feeders and their anastomoses create a variety of vascular networks between the lingual and the facial arterial system. Therefore, confirmation of the exact feeding artery by injection of a small amount of indigo carmine is important.

In recent years, intravenous chemotherapy using a cisplatin-based regimen has been advocated as a form of induction therapy (7). In describing their work with patients with advanced squamous cell carcinoma of the head and neck, Jacobs et al (8) reported that the use of induction chemotherapy (cisplatin and bleomycin) plus standard surgery, ra-

diation, and maintenance chemotherapy with monthly cisplatin (80 mg/m²) for 6 months resulted in a significantly lower metastatic rate. This intravenous maintenance chemotherapy with cisplatin also produced a significantly improved 3-year disease-free survival rate (67%) over that achieved with standard (49%) or induction (44%) treatment protocols in patients with cancer of the oral cavity. In a study of patients with advanced head and neck cancer, Ervin et al (9) reported a 3-year disease-free survival rate of 88% with the use of randomized adjuvant therapy with cisplatin, bleomycin, and methotrexate as compared with 57% in the control group.

Previous reports on selective arterial infusion chemotherapy revealed a better response rate in tumors supplied by a single feeding artery from the ECA, which may be attributed to the high concentration of chemotherapeutic agents infused into the lesion (10, 11). In 1995, Imai et al (12) reported an overall response rate of 96%, with a complete response rate of 50%, using CDDP (cisplatin)-CBDCA (carboplatin) combined infusion after catheterization with the Seldinger technique via a

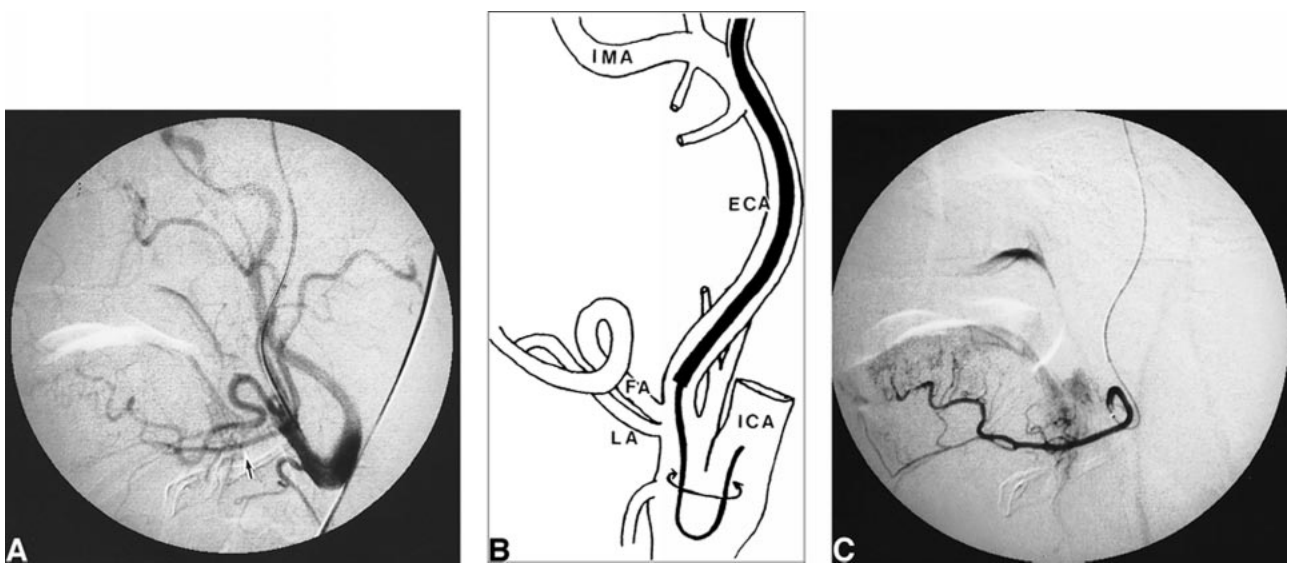


FIG 8. Superselective catheterization of the sharply angled feeding artery in a 44-year-old man with tongue cancer (T1N0M0).
 A-C, The lingual artery is sharply angled (arrow, A). A coaxial microcatheter was introduced initially into the internal carotid (or occipital) artery to make the tip of the catheter J-shaped (B), then the catheter tip was turned around and pulled back, resulting in superselective catheterization into the feeding artery (C). ICA, internal carotid artery; ECA, stem of external carotid artery; LA, lingual artery; FA, facial artery; IMA, internal maxillary artery.

transfemoral approach. Korogi et al (13) reported an overall response rate of 92%, with a complete response rate of 38%, with the use of transfemoral catheterization in patients with advanced carcinoma of the mouth. Their technique consisted of the one-shot slow infusion method repeated several times. On the other hand, the continuous infusion technique used in our series produced an overall response rate of 94% and 100% among those treated with the superselective and subselective techniques, respectively. The complete response rate after superselective catheterization in patients with tongue cancer was also particularly high (95%) relative to that reported in previous series using the same technique (4), although an exact comparison may be difficult owing to differences in patient selection, chemotherapeutic regimen, and combined radiation therapy.

After superselective catheterization, the patients who had a complete response had a lower recurrence rate; however, no statistical difference was identified in the 5-year survival rates between the two techniques for any type of oral cancer. Long-term follow-up with a larger patient population will be required to address this issue; however, for patients with tongue cancer, the survival rate seems to be better after superselective catheterization, in that our patients with more advanced disease (T3 plus T4) had a 25% 5-year survival rate after superselective catheterization versus a 14% rate after subselective treatment. Because of our low complication rate, we believe that the superselective procedure helps improve the quality of life for patients with cancer of the oral cavity.

Conclusion

Complete response and survival rates among patients with oral tumors treated with superselective or subselective continuous arterial infusion chemotherapy were relatively high, with no statistical significance between the two techniques. Further investigation is needed to identify which is the best

technique, as superselective catheterization probably resulted in better survival rates in our study because of the patient group. Superselective continuous infusion chemotherapy through the STA combined with radiation therapy may be suitable for local control of malignant tumors of the oral cavity, with a low recurrence rate.

References

1. Ramsden CH, Duff JK. **Continuous arterial infusion of head and neck tumors.** *Cancer* 1963;16:133-135
2. Cheung DK, Regan J, Savin M, et al. **A pilot study of intraarterial chemotherapy with cisplatin in locally advanced head and neck cancer.** *Cancer* 1988;61:903-908
3. Claudio F, Cacace F, Comella G, et al. **Intraarterial chemotherapy through carotid transposition in advanced head and neck cancer.** *Cancer* 1990;65:1465-1471
4. Simunek A, Krajina A, Hlava A. **Selective intraarterial chemotherapy of tumors in the lingual artery territory by a new approach.** *Cardiovasc Intervent Radiol* 1993;16:392-395
5. Kozielec T, Jozwa H. **Variation in the course of the facial artery in the prenatal period in man.** *Folia Morphol (Warsz)* 1997;36:55-61
6. Adachi B. *Das Arteriensystem der Japaner.* Bd. 2. Kyoto: Maruzen; 1928:58-96
7. Robbins KT, Vicario D, Seagren S, et al. **A targeted supradose cisplatin chemoradiation protocol for advanced head and neck cancer.** *Am J Surg* 1994;168:419-422
8. Jacobs C, Makuch R. **Efficacy of adjuvant chemotherapy for patients with resectable head and neck cancer: a subset analysis of the head and neck contracts program.** *J Clin Oncol* 1990;8:838-847
9. Ervin TJ, Clardk JR, Weichselbaum RR, et al. **An analysis of induction and adjuvant chemotherapy in the multidisciplinary treatment of squamous-cell carcinoma of the head and neck.** *J Clin Oncol* 1987;5:10-20
10. Campbell TN, Howell SB, Pfeifle CE, Wung WE, Bookstein J. **Clinical pharmacokinetics of intraarterial cisplatin in humans.** *J Clin Oncol* 1983;1:755-762
11. Los G, Blommaert FA, Barton R, Heath DD, et al. **Selective intraarterial infusion of high-dose cisplatin in patients with advanced head and neck cancer results in high tumor platinum concentrations and cisplatin-DNA adduct formation.** *Cancer Chemother Pharmacol* 1995;37:150-154
12. Imai S, Kajihara Y, Munemori O, et al. **Superselective cisplatin (CDDP)-carboplatin (CBDCA) combined infusion for head and neck cancers.** *Eur J Radiol* 1995;21:94-99
13. Korogi Y, Hirai T, Nishimura R, et al. **Superselective intraarterial infusion of cisplatin for squamous cell carcinoma of the mouth: preliminary clinical experience.** *AJR Am J Roentgenol* 1995;165:1269-1272