

Leptomeningeal Metastasis from Malignant Pleural Mesothelioma

Boris D. Petrovic, Dusko B. Kozic, Robert R. Semnic, Mladen Prvulovic, Dragana Djilas-Ivanovic, R. Nuri Sener, and Istvan Klem

Summary: Leptomeningeal metastasis from malignant mesothelioma is very rare; to our knowledge, only one imaging report exists in the literature. We present the case of widespread leptomeningeal lesions secondary to a malignant mesothelioma in a 61-year-old woman.

CNS involvement due to metastatic mesothelioma is very rare. The metastatic intracranial lesion may present as a solitary mass or as leptomeningeal infiltration (1–7). Leptomeningeal metastasis is extremely rare, and to our knowledge, only one report of the MR imaging findings of this condition exists in the literature (1). Herein, we believe we report the imaging findings in the second such reported case of this condition.

Case Report

Malignant mesothelioma of the right pleura in a 61-year-old woman was confirmed by pleurolysis and biopsy (Fig 1A and B). Although she responded well to chemotherapy, 1 year later she was admitted to the hospital because of vomiting, for which she received symptomatic therapy. A year thereafter, she was admitted again with confusion and ataxia, at which time T2-weighted images revealed an impression of widened cerebellar sulci (Fig 2A). On postcontrast T1-weighted images, widespread leptomeningeal infiltrations were evident in the cerebellar and cerebral sulci. The lesions were more prominent in the cerebellar sulci compared with in the cerebral sulci. The third and lateral ventricles were dilated, which suggested development of acute hydrocephalus (Fig 2B and C). At that stage, findings of a chest radiograph and an abdominal sonogram were noted to be normal. Lumbar puncture revealed findings consistent with those of neoplastic infiltration.

The patient died 30 days after the MR imaging examination. At autopsy, mesothelioma with infiltration of the lower lobe of the right lung was evident. Metastases to the mediastinal lymph nodes and micrometastases to the liver were noted. Leptomeningeal infiltration was confirmed by histologic analysis revealing presence of sarcomatous cells (Fig 3).

Discussion

It has been reported that hematogenous metastases of malignant mesothelioma usually involves the liver, adrenal glands, kidneys, and the contralateral lung. Metastatic spread to the CNS is rare. Most of these had been encountered as masses in the brain parenchyma (2–6), and one case was noted with orbital metastasis (7). Falconieri et al (2) reported three autopsy cases of malignant pleural mesothelioma with brain metastases and provided a review of 15 similar previously published reports. They noted that in two patients, the brain metastases were discovered incidentally at autopsy. In one patient, the brain metastasis was discovered ante mortem, when a CT scan suggested a primary tumor of the brain. With respect to the histopathologic findings, the tumors had spindle-shaped malignant cells, pseudopalisading, necrosis, and vascular buds suggestive of glioblastoma multiforme (2). Other authors also had the impression that the metastatic tumors of malignant mesothelioma in the brain mimicked the pattern of glioblastoma multiforme both histologically and radiologically (2–6). On the other hand, leptomeningeal involvement is very rare. The only imaging report is by Oksuzoglu et al (1), who used MR imaging. Their patient was a 44-year-old woman who presented clinically with convulsions, and the diagnosis of malignant mesothelioma was confirmed by biopsies of lymph nodes (1).

It is known that the causes of leptomeningeal metastasis include adenocarcinomas originating from the lung, stomach, breast, ovary, malignant melanoma, leukemia, lymphoma, and primary CNS malignancies. Clinically, these usually present as a low-grade meningitis syndrome. Our patient also presented with such a syndrome in that she had confusion and ataxia, which was an indication for a cranial MR imaging examination. This revealed leptomeningeal metastases with contrast enhancement, more prominent in the cerebellar sulci, and changes consistent with acute hydrocephalus, which likely accounted for ataxia and confusion.

Conclusion

This patient reveals that, although very rare, leptomeningeal metastases can be associated with malignant mesothelioma of the pleura. In the event that these patients present clinically with a low-grade meningitis syndrome, brain MR imaging should be performed with administration of intravenous paramagnetic contrast medium to uncover lesions in the leptomeninges.

Received November 6, 2003; accepted after revision November 20. From the Department of Diagnostic Imaging, Institute of Oncology (B.D.P., D.B.K., R.R.S., M.P., D.D.-I.), and the Department of Pathology, Institute for Lung Diseases (I.K.), Sremska Kamenica, Serbia and Montenegro; and the Department of Radiology, Ege University Hospital (R.N.S.), Bornova, Izmir, Turkey.

Address correspondence to Professor R. Nuri Sener, Department of Radiology, Ege University Hospital, Bornova, Izmir, Turkey.

FIG 1. Mesothelioma.

A, Conventional radiograph of the chest, revealing the mesothelioma in the right pleura.

B, Positive Calretinin reaction of the mesothelioma (tumor biopsy obtained by pleuroscopy; $\times 250$ magnification).

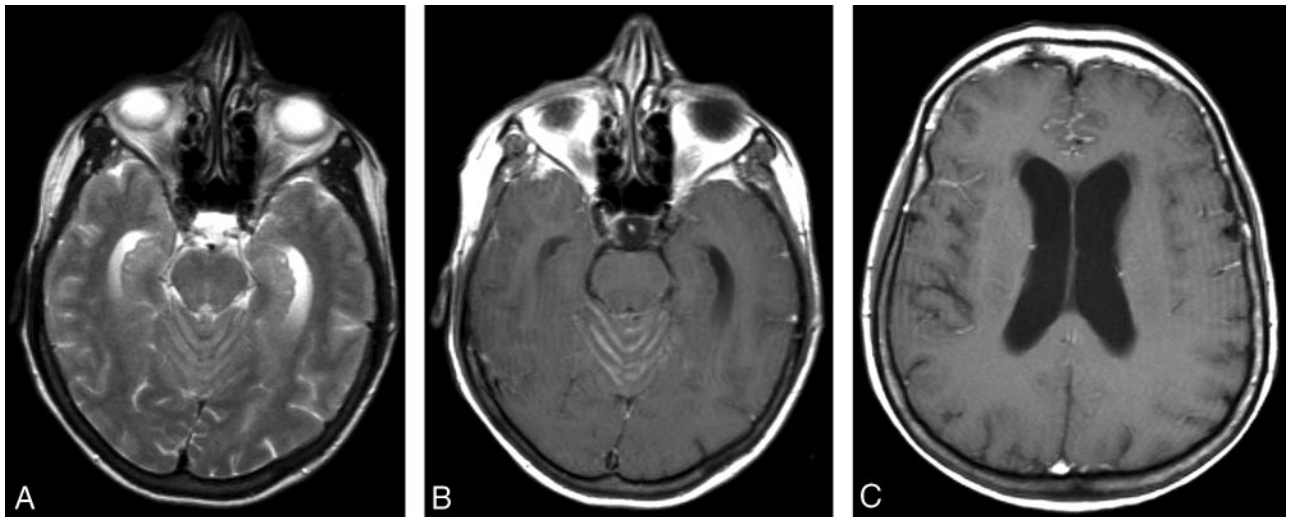
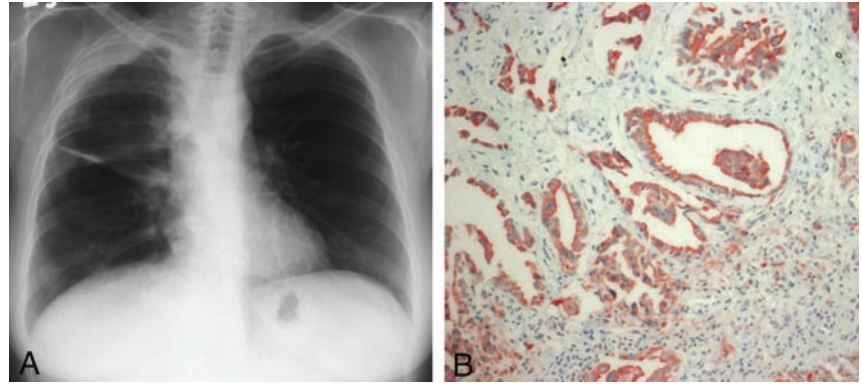


FIG 2. Leptomeningeal metastasis.

A, T2-weighted image, revealing widening of vermian sulci.

B, Postcontrast T1-weighted image, revealing enhancement of the vermian sulci corresponding to leptomeningeal infiltration. Note dilatation of temporal horns.

C, Postcontrast T1-weighted image, revealing leptomeningeal enhancement in the frontal sulci. Lateral ventricular dilatation is noted.

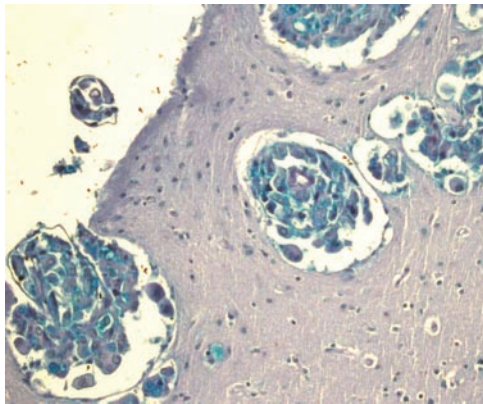


FIG 3. Leptomeningeal metastasis of the mesothelioma (Alcian blue staining; $\times 250$ magnification).

References

- Oksuzoglu B, Yalcin S, Erman M, Dagdelen S. **Leptomeningeal infiltration of malignant mesothelioma.** *Med Oncol* 2002;19:167-169
- Falconieri G, Grandi G, DiBonito L, et al. **Intracranial metastases from malignant pleural mesothelioma: report of three autopsy cases and review of the literature.** *Arch Pathol Lab Med* 1991;115:591-595
- Kitai R, Kabuto M, Kawano H, et al. **Brain metastasis from malignant mesothelioma: case report.** *Neurol Med Chir (Tokyo)* 1995;35:172-174
- Kawai A, Nagasaka Y, Muraki M, et al. **Brain metastasis in malignant pleural mesothelioma.** *Intern Med* 1997;36:591-594
- Schwechheimer K, Butzengeiger M. **Brain metastases in malignant fibrous mesothelioma: case report and review of the literature.** *Acta Neuropathol (Berl)* 1983;60:301-304
- Kobayashi S, Ida M, Matsui O, et al. **Lipomatous change in a brain metastasis from malignant pleural mesothelioma.** *Neuroradiology* 2001;43:159-161
- Kubota K, Furuse K, Kawahara M, et al. **A case of malignant pleural mesothelioma with metastasis to the orbit.** *Jpn J Clin Oncol* 1996;26:469-471