

Are your **MRI contrast agents** cost-effective?

Learn more about generic **Gadolinium-Based Contrast Agents**.



AJNR

**A Review of Two Cases of Fenestrated
Internal Jugular Veins as Seen by CT
Angiography**

Alexander J. Towbin and Emanuel Kanal

AJNR Am J Neuroradiol 2004, 25 (8) 1433-1434

<http://www.ajnr.org/content/25/8/1433>

This information is current as
of April 18, 2024.

A Review of Two Cases of Fenestrated Internal Jugular Veins as Seen by CT Angiography

Alexander J. Towbin and Emanuel Kanal

Summary: Venous fenestrations are a rarely seen entity in the neck. Although their clinical significance is questionable, their importance in presurgical planning may be considerable. We present a report of two cases of internal jugular vein fenestration.

Fenestrations, or complete divisions of vasculature, have been described in many of the craniocervical arteries. One postmortem study has shown that as many as 6% of people have a fenestrated basilar artery (1). Arterial fenestrations have been described in the vertebral artery, the basilar artery, the middle cerebral artery, the anterior cerebral artery, the posterior inferior cerebellar artery, the posterior cerebral artery, the posterior communicating artery, and the internal carotid artery. Although multiple craniocervical arterial fenestrations have been described, venous fenestrations have not. Two recent cases of internal jugular vein fenestrations are described herein.

Case Reports

Patient 1

After a fall, a 62-year-old woman presented for CT angiography (CTA) to rule out vertebral artery injury. A CT scan 1 day prior revealed a fracture of the left transverse process of C4. CTA revealed no vascular injury. There was an incidental finding of a fenestrated proximal left internal jugular vein without dilatation (Fig 1).

Patient 2

After a subarachnoid hemorrhage, a 70-year-old man presented for CTA to rule out an intracranial aneurysm. CTA showed areas of moderate and severe stenosis of the proximal right internal carotid artery and complete occlusion of the proximal left internal carotid artery. A significant network of collateral arterial flow was noted. No aneurysm was observed. There was an incidental finding of a fenestrated proximal left internal jugular vein without dilatation (Fig 2).

Discussion

The internal jugular vein is the great collecting vein of the cranium, face, and anterior neck. It is the continuation of the sigmoid sinus beginning at the jugular

foramen, where it drains most of the venous blood from the brain as well as CSF. The internal jugular vein continues inferiorly from the skull base until it joins the subclavian vein to form the brachiocephalic vein.

Fenestration of the internal jugular vein is uncommon. There have been five previously published reports of seven cases of a fenestrated internal jugular vein (2–6). One study estimated that fenestration of the internal jugular vein occurs in as much as 0.4% of the population (2).

Fenestrated arteries are associated with an increased incidence of aneurysm formation at the fenestration. As with aneurysms that tend to occur at any vessel bifurcation, the two theories that are most commonly presented to explain the association of increased incidence of aneurysm formation at fenestrations include turbulent flow at the bifurcation point and a defect in the media at both the proximal and distal branch points (7).

Fenestrated jugular veins have been associated in other reports with phlebectasia, a local fusiform dilatation (2–4). The jugular veins were not dilated in our cases. The cause of phlebectasia is unknown. There are no other anomalies associated with jugular fenestration. There is likely no clinical significance of a fenestrated jugular vein, although a detailed knowledge of anatomic variants can be helpful to the surgeon. Furthermore, an awareness that fenestrations of the jugular vein, although rare, can occur will help avoid radiologic misinterpretations or misidentifications of the vascular anatomic structures encountered in digital or conventional angiography.

References

1. Wollschlaeger G, Wollschlaeger PB, Lucas FV, Lopez VF. Experience and result with postmortem cerebral angiography performed as a routine procedure of the autopsy. *AJR Am J Roentgenol* 1967;101:68–87
2. Prades JM, Timoshenko A, Dumollard JM, et al. High duplication of the internal jugular vein: clinical incidence in the adult and surgical consequences, a report of three clinical cases. *Surg Radiol Anat* 2002;24:129–132
3. Som PM, Shugar JMA, Sacher M, Lanzieri CF. Internal jugular vein phlebectasia and duplication: CT features. *J Comput Assist Tomogr* 1985;9:390–392
4. Rossi A, Tortoni-Donati P. Internal jugular vein phlebectasia and duplication: case report with magnetic resonance angiography features. *Pediatr Radiol* 2001;31:134
5. Sylaidis P, Bardsley A, Montgomery P. Duplication of the internal jugular vein [letter]. *Arch Otolaryngol Head Neck Surg* 1997;123:1358
6. Zukschwerdt L. Seltene lokalisation einer venektasie. *Dtsch Z Chir* 1929;216:283–285
7. Sanders WP, Sorek PA, Mehta BA. Fenestration of intracranial arteries with special attention to associated aneurysms and other anomalies. *AJNR Am J Neuroradiol* 1993;14:675–680

Received November 16, 2003; accepted January 20, 2004.

From the Department of Radiology, University of Pittsburgh Medical Center, Pittsburgh, PA.

Address correspondence to Alexander J. Towbin, MD, Department of Radiology, University of Pittsburgh Medical Center, 200 Lothrop Street, Pittsburgh, PA 15213.

© American Society of Neuroradiology

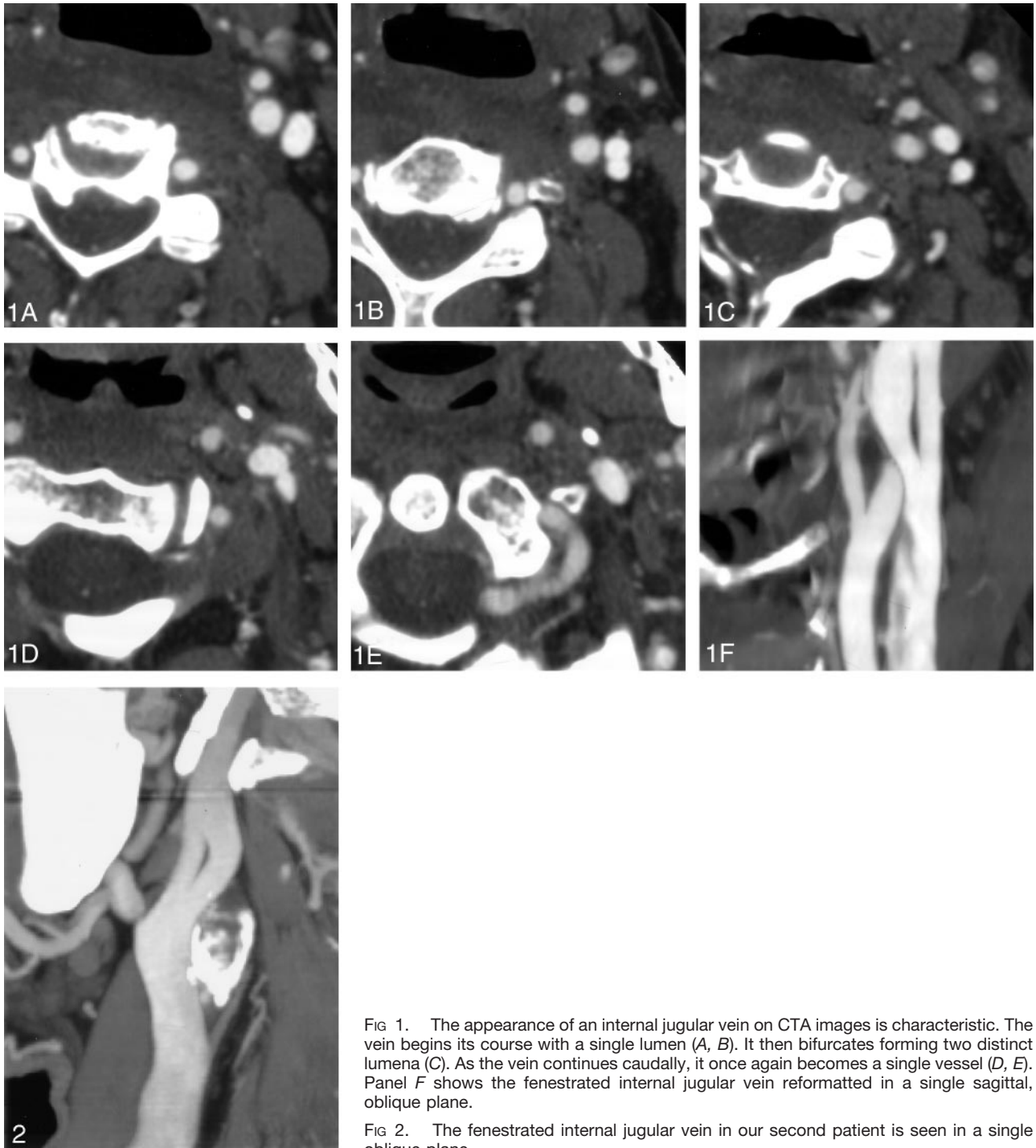


FIG 1. The appearance of an internal jugular vein on CTA images is characteristic. The vein begins its course with a single lumen (A, B). It then bifurcates forming two distinct lumina (C). As the vein continues caudally, it once again becomes a single vessel (D, E). Panel F shows the fenestrated internal jugular vein reformatted in a single sagittal, oblique plane.

FIG 2. The fenestrated internal jugular vein in our second patient is seen in a single oblique plane.