

Are your **MRI contrast agents** cost-effective?

Learn more about generic **Gadolinium-Based Contrast Agents**.



FRESENIUS  
KABI

caring for life

**AJNR**

**Taylor-Haughton line revisited.**

A J Taylor, V M Haughton, A Syvertsen and K C Ho

*AJNR Am J Neuroradiol* 1980, 1 (1) 55-56

<http://www.ajnr.org/content/1/1/55>

This information is current as  
of April 20, 2024.

# Taylor-Haughton Line Revisited

Andrew J. Taylor<sup>1</sup>  
 Victor M. Haughton<sup>1</sup>  
 Asbjorn Syvertsen<sup>1, 2</sup>  
 Khang-Cheng Ho<sup>3</sup>

In 1900 Taylor and Haughton described a technique to define a line on the scalp directly above the central (rolandic) fissure. The Taylor-Haughton line was used to identify the central fissure in computed tomography (CT) images. Radiopaque catheters are placed on the scalp on either side of the Taylor-Haughton line prior to CT imaging. The accuracy of the Taylor-Haughton line for identifying the central fissure was also investigated in cadaver brains. The Taylor-Haughton line provides a good approximation of the location of the rolandic fissure.

Four years after Roentgen reported his discovery of x-rays, Edward Taylor, examiner in anatomy, and William Haughton, demonstrator of roentgen photography at Trinity College, began to study the convolutions of the brain in relation to the surface anatomy of the head [1]. They used x-rays and thin wires placed in situ in major cerebral fissures of cadaver brains and described a technique for plotting a line on the scalp that identifies the rolandic fissure. We used the Taylor-Haughton line to identify the rolandic fissure on computed tomography (CT) scans. The accuracy of the Taylor-Haughton technique for identifying the rolandic fissure has been supported by anatomic studies.

## Materials and Methods

### *Determination of Taylor-Haughton line*

Before positioning the patient for CT, a disposable surgical cap is tied and taped tightly in place on the head (fig. 1). Line 1 from the nasion to theinion (external occipital protuberance) is drawn directly over the sagittal suture on the paper cap and divided into quarters. A second line is drawn on the cap to connect the orbitotemporal angle and the point on line 1 three-fourths the distance from nasion toinion. A small piece of barium-impregnated catheter is then placed on the cap 1.25 cm posterior to the midpoint of line 1 (superior rolandic point). Line 3 is drawn on the cap through the preauricular point perpendicular to Reid's base line. The intersection of this line and line 2 is the inferior rolandic point. A line (Taylor-Haughton line) is drawn to connect the superior and inferior rolandic points. Barium-impregnated catheters are then taped on the cap on either side of the Taylor-Haughton line for CT imaging (fig. 1).

A lateral localizer image or a lateral radiograph may be obtained to verify the position of the catheters (fig. 2). The patient is positioned in the gantry of the CT scanner. The gantry is angled and/or the patient positioned so that the angle of cut is as nearly perpendicular to the Taylor-Haughton line as possible, and CT images are obtained. We used an EMI

Received July 19, 1979; accepted after revision September 14, 1979.

Presented at the annual meeting of the American Society of Neuroradiology, Toronto, May 1979.

<sup>1</sup> Department of Radiology, Medical College of Wisconsin, and Milwaukee County General Hospital, 8700 W. Wisconsin Ave., Milwaukee, WI 53226. Address reprint requests to V. M. Haughton.

<sup>2</sup> Present address, Vestfold Hospital, Tonsberg, Norway.

<sup>3</sup> Department of Pathology, Medical College of Wisconsin, and Milwaukee County General Hospital, Milwaukee, WI 53226.

*AJNR* 1:55-56, January/February 1980  
 0195-6108/80/0011-0055 \$00.00  
 © American Roentgen Ray Society

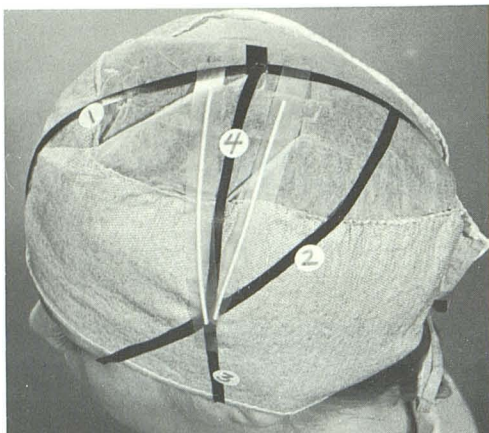


Fig. 1.—Taylor-Haughton line (4) marked on paper cap. Thin radiopaque catheters placed on either side of line. Lines 1-3 described in text.

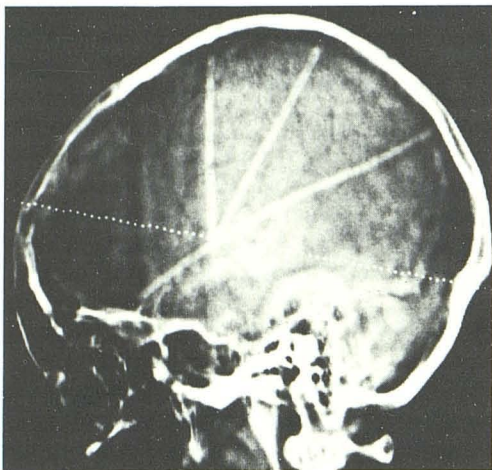


Fig. 2.—Lateral localizer image. Radiopaque catheter markers on either side of Taylor-Haughton line. Third catheter along line 2.

1005 and a GE CT/T 8800. In patients in whom sulci were discernible, the sulcus that appeared to be most exactly midway between catheters was selected as the rolandic fissure (fig. 3). In these patients, the appearance and the relative depth of fissures were noted.

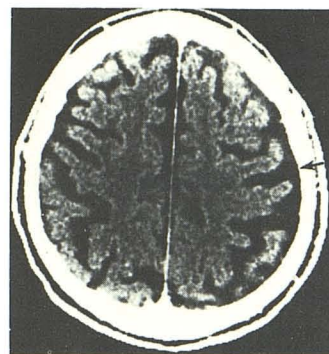
#### Cadaver Study

In 20 formalin-fixed brains without evidence of gross pathology, the central rolandic fissure was identified by gross inspection and the brain was sectioned in an axial plane perpendicular to the central rolandic fissure. The gross appearance of the central rolandic fissure on the cut section was studied and compared to CT images in the patients in whom the Taylor-Haughton line had been placed.

#### Results

In 18 consecutive patients, the Taylor-Haughton line was easily plotted and marked by means of radiopaque catheters.

Fig. 3.—CT image. Central fissure (arrow) on patient's left located by radiopaque markers on lateral aspect of scan.



In 11 cases, a specific sulcus in the CT image could be designated as the central fissure. In two cases, no sulci were seen, and in five cases, more than one sulcus was present in the region of the catheters. The sulcus identified by the Taylor-Haughton line was the deepest sulcus of the brain in three cases, the middle of three approximately equally deep sulci in three cases, and a relatively deep sulcus in five cases. These five sulci lacked characteristic features. The relative straightness of angulation of the fissure with respect to the plane of the interhemispheric fissure and appearance of adjacent sulci were not characteristic. Although the cortex in front of the gyrus anterior to the fissure in some images appeared thicker, measurements of the cortex failed to demonstrate any consistent difference.

On the cut surface of the 20 cadaver brains, the central rolandic fissure identified by the pathologist was either the deepest fissure (six cases) or the middle of three deep fissures (six cases) or a deep fissure (eight cases). The motor cortex in front of the fissure was thicker than the sensory cortex posterior to it, but the greater thickness was not evident throughout the cut in each case.

#### Discussion

Using the materials and methods that we described, the Taylor-Haughton line can be plotted reliably and quickly. Similarity of fissures identified by the line and those identified by the pathologist in cadaver brains suggests that the Taylor-Haughton line reliably locates the central fissure. When no fissure can be distinguished on the CT image, the Taylor-Haughton line nonetheless localizes the region of the central fissure. The CT appearance of the central fissure is not sufficiently characteristic that it can be recognized by appearance alone. But by means of the Taylor-Haughton line, the motor and sensory cortex can be accurately located for planning surgical procedures for anatomic studies. Once the central fissure is identified, the occipitoparietal and other fissures are usually easily defined.

#### REFERENCE

1. Taylor EH, Haughton WS. Some recent researchers on the topography of the convolutions and fissures of the brain. *Trans R Acad Med Ireland* 1900;18:511-522