

Are your **MRI contrast agents** cost-effective?

Learn more about generic **Gadolinium-Based Contrast Agents**.



FRESENIUS
KABI

caring for life

AJNR

Catheter dilatation of proximal carotid stenosis during distal bifurcation endarterectomy.

C W Kerber, L D Cromwell and O L Loehden

AJNR Am J Neuroradiol 1980, 1 (4) 348-349

<http://www.ajnr.org/content/1/4/348.citation>

This information is current as of April 20, 2024.

Catheter Dilatation of Proximal Carotid Stenosis During Distal Bifurcation Endarterectomy

Charles W. Kerber,¹ Laurence D. Cromwell,² and Otto L. Loehden³

Although the deliberate therapeutic dilatation of arteriosclerotic plaques was described more than 15 years ago, clinical acceptance of the technique has been slow [1]. Since Gruntzig and Hopff [2] developed a tough, reliable, and easy to use polyvinylchloride balloon catheter, however, the applicability of the technique has been extended beyond the dilatation of the iliac, femoral, and renal arteries, and now even coronary artery narrowings are treated [3]. Perhaps because of the fear of distal embolization, carotid artery dilatations have not yet been attempted. We treated a common carotid artery stenosis, and now report this success and details of the technique.

Case Report

A 65-year-old man had sudden right eye blindness and slurred speech for a few minutes. Two days after this episode, his right upper extremity became temporarily weak. Pertinent medical history revealed that he underwent thromboendarterectomy of the right iliac vessels 16 years before. A right aortofemoral bypass graft was performed 11 years before.

On physical examination, he was anxious, was concerned about the probability of a permanent stroke, and was obese. He had normal carotid pulsations on the right, decreased pulsations on the left, and had a bilateral loud bruit best heard near the angle of the mandible.

Carotid arteriography via the right axillary approach demonstrated arteriosclerotic narrowing of both common carotid bifurcations with probable ulceration on the left. Because of poor runoff of the left common carotid artery when the 5 French catheter was inserted in it, he was thought to have a stenotic lesion at the origin of the common carotid artery. Arch aortography via the right transfemoral approach 2 days later demonstrated a tight weblike lesion at the origin of the left common carotid artery (fig. 1).

Even though bilateral bifurcation disease was documented, because of the stenosis of the left common carotid artery origin, a left carotid bifurcation endarterectomy was not considered to be of potential benefit. Therefore, the patient had a right-sided carotid bifurcation endarterectomy the next day, from which he uneventfully recovered.

He suffered another right arm transient ischemic attack 2 months later and was admitted for left carotid bifurcation endarterectomy. The endarterectomy was performed under general endotracheal anesthesia in the x-ray department. After anticoagulation with heparin, his blood pressure was elevated and a standard left-sided carotid bifurcation endarterectomy was performed. When the arteriotomy closure was nearly complete, the guide wire was inserted in a retrograde direction down the common carotid artery with fluoroscopic control. An 8 and then a coaxial 14 French Teflon catheter was passed over the guide wire dilating the web at the origin of the left common carotid artery. Spot films were obtained to confirm the dilatation (fig. 2). The common carotid artery was then clamped below the arteriotomy site and the closure was completed. (Back-bleeding was permitted to occur through the arteriotomy from the common carotid just prior to final suture placement.) As an additional safety measure, the internal carotid artery was cross clamped, the common carotid artery clamp was removed, and flow was allowed to pass into the external carotid system in case any debris was still present. Finally the internal carotid artery clamp was removed.

The patient tolerated the procedure well and moved all extremities with no neurologic deficit on awakening. In the subsequent 3 years he did well and had no further transient ischemic attacks.

Discussion

Deliberate nonsurgical dilatation of arteriosclerotic plaques has been carried out for more than a decade, but the procedure has not been well accepted by most clinicians. Recently, the development of a reliable polyvinylchloride balloon catheter by Gruntzig has led to the wider use and acceptance of the technique in both the USA and in Europe. Therapeutic dilatation with a catheter is of value because arteriosclerotic patients are frequently ill with other diseases and have vascular systems that poorly tolerate trauma of any sort. Dilatations are done under local anesthesia and may be repeated as often as necessary. If unsuccessful, they do not preclude surgery and, in many cases, even facilitate it.

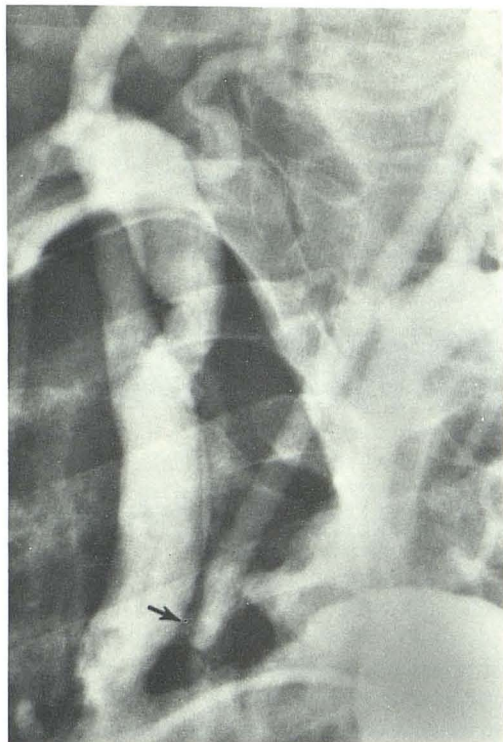
It seems reasonable that distal embolization from these

Received December 26, 1979; accepted after revision March 24, 1980.

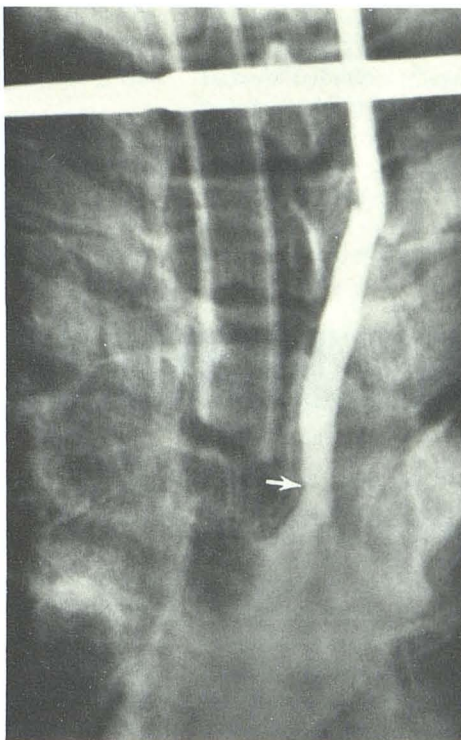
¹ Department of Radiology, University of Pittsburgh, Pittsburgh, PA 15261. Present address: Department of Radiology, University of California, San Diego, CA 92103.

² Department of Radiology, SB-05, University of Washington, Seattle, WA 98195. Address reprint requests to L. D. Cromwell.

³ Department of Radiology, Tuality Community Hospital, Hillsboro, OR 97123.



1



2

Fig. 1.—Arch injection, right posterior oblique position. Severe stenosis of left common carotid artery (arrow).

Fig. 2.—Anteroposterior view. Stenotic lesion was just dilated. Catheter lies about 4 cm cephalad of web. Contrast agent refluxes back into aortic arch, and stenosis is now widely patent (arrow).

procedures should occur. Such embolization has been reported [3], but to date, has not caused clinical problems. The brain is an unforgiving organ, and angiographers are reluctant to attack carotid or vertebral artery stenoses. In addition, the problem of carotid dilatation is compounded by the character of many carotid lesions: they are frequently ulcerated, and it is the ulceration that causes the neurologic problems [4, 5].

However, we believe that carotid artery stenoses should be treatable. To begin our clinical experiment, we wanted a patient with a purely stenotic lesion. The open arteriotomy was deemed an essential safeguard for this initial step in proving the feasibility of the technique in the carotid and vertebral system.

The treatment was successful and the patient was still asymptomatic more than 3 years later. It is doubtful whether the common carotid artery dilatation alone alleviated the patient's symptoms, but rather improved the success of the endarterectomy. The patient was spared the danger and expense of a thoracotomy. We believe that the safety of this procedure was enhanced significantly by the close coop-

eration of radiologist and surgeon, the liberal use of fluoroscopy for careful positioning of guide wire and catheter, and the presence of an angiographic/surgical team that had worked together on other occasions.

REFERENCES

1. Dotter CT, Judkins MP. Transluminal treatment of arteriosclerotic obstruction. Description of a technique and a preliminary report of its application. *Circulation* 1964;30:654-670
2. Gruntzig A, Hopff H. Perkutane Rekanalisation chronischer arterieller Verschlüsse mit einem neuen Dilatationskatheter. *Dtsch Med Wochenschr* 1974;99:2502-2505
3. Zeitler E, Gruntzig A, Schoop W. *Percutaneous vascular recanalization*. 1978 Berlin: Springer,
4. Moore WS, Hall AD. Importance of emboli from carotid bifurcation and pathogenesis of cerebral ischemic attacks. *Arch Surg* 1970;101:708-715
5. Edwards JH, Kricheff II, Riles T, Imparato A. Angiographically undetected ulceration of the carotid bifurcation as a cause of embolic stroke. *Radiology* 1979;132:369-373