

Are your **MRI contrast agents** cost-effective?

Learn more about generic **Gadolinium-Based Contrast Agents**.



FRESENIUS
KABI

caring for life

AJNR

Muscular and CNS effects of carotid artery administration of contrast media in rabbits.

C C Whisson, C A Evill, M R Sage and A J Wilson

AJNR Am J Neuroradiol 1990, 11 (1) 143-148

<http://www.ajnr.org/content/11/1/143>

This information is current as of April 19, 2024.

Muscular and CNS Effects of Carotid Artery Administration of Contrast Media in Rabbits

Christopher C. Whisson¹
 Charles A. Evill
 Michael R. Sage
 Alan J. Wilson

Facial muscle twitching during intracarotid injections of nonionic contrast media has been observed in rabbits. To investigate the cause of this reaction, cortical EEG and facial EMG recordings were made from rabbits receiving selective internal and external carotid artery injections of control solutions (normal saline, mannitol), an ionic contrast medium (meglumine iohalamate), and three nonionic contrast media (iohexol, iopromide, and iotrolan). Internal carotid artery injections with all contrast media, both ionic and nonionic, produced ipsilateral EEG changes in 24 of 28 animals; however, ipsilateral EMG changes and visible twitching were observed only in animals injected with nonionic contrast media. Internal carotid artery injections with control ionic and nonionic solutions (physiological saline and mannitol, respectively) produced no EEG changes in any animals. Mannitol produced only ipsilateral EMG changes and visible twitching in most animals. The severity of the reaction to mannitol was generally less than that to the nonionic contrast media, and this difference was statistically significant when comparing mannitol with iohexol and iotrolan but not with iopromide. External carotid artery injections with nonionic solutions (contrast media and mannitol) produced significantly more severe ipsilateral EMG changes and visible twitching than were recorded with the internal carotid artery injections. Ionic solutions (contrast media and saline) had no effect. EEG changes were not observed after external carotid artery injection of any solution, with the exception of two of the seven animals injected with iotrolan. Angiography demonstrated retrograde filling of the external carotid arterial system from internal carotid artery injection via functioning orbital anastomoses. In contrast, internal carotid arterial vessels were not seen angiographically after external carotid artery injection.

We conclude that the visible twitching reaction to internal carotid artery injection of nonionic contrast media is due partly to lack of ions and partly to some intrinsic chemotoxicity of these media. This reaction is unrelated to the EEG changes, which occur with all contrast media and appear not to be ion-dependent. The visible reactions, therefore, do not appear to be centrally mediated but rather due to a locally mediated muscular or neuromuscular effect.

AJNR 11:143-148, January/February 1990

The new nonionic contrast media have generally been shown to have lower toxicity than the older ionic contrast media in all parenteral applications and are gradually replacing them [1]. Several studies, however, have demonstrated that the nonionic contrast media, despite their lowered osmolality, still exhibit some chemotoxicity.

Iohexol has been shown to exert a negative inotropic effect on cultured chick embryo ventricular cells that was not accounted for by calcium binding or hyperosmolality [2]. Intracarotid injection of iodixanol, with an osmolality similar to plasma, has been shown to cause a degree of blood-brain barrier breakdown in more than 50% of rabbits tested [3]. All ionic and nonionic contrast media that were tested by Dawson et al. [4] produced changes in red cell morphology, even when the contrast media were isosmolar with plasma.

In recent experiments on the effects of intracarotid contrast media on the blood-

Received January 19, 1989; revision requested March 20, 1989; revision received May 8, 1989; accepted May 10, 1989.

This work was supported by a grant from Schering AG, Berlin.

¹ All authors: Department of Radiology, Flinders Medical Centre, Bedford Park, 5042, South Australia, Australia. Address reprint requests to C. C. Whisson.

0195-6108/90/1101-0143
 © American Society of Neuroradiology

brain barrier, a clonic reaction has been observed in the facial muscles of the rabbit in response to selective internal carotid artery injection with nonionic contrast media. This reaction was not observed when an ionic contrast medium was injected [3, 5, 6]. A twitching reaction in the rabbit has been noted by Golman [7] after the intracarotid injection of nonionic contrast media. Small movements of the head and neck were noted by Skalpe [8, 9] during selective vertebral artery injection with nonionic contrast media. Additionally, incidental observations have been made of involuntary movements during clinical angiography when using the nonionic contrast media. The details are unclear, and such movements have generally been ascribed to pain or discomfort [10–12].

The aim of this study was to investigate the twitching reaction in the rabbit to intracarotid injection of contrast medium. The effects of injections of ionic contrast material (meglumine iohalamate [MGI]), nonionic, monomeric contrast material (iohexol and iopromide), a dimeric, nonionic contrast agent (iotrolan), and control solutions of saline (ionic) and mannitol (nonionic) were compared by observing the visible facial muscle reaction and recording the facial muscle EMG and the cortical EEG.

Materials and Methods

Forty-three rabbits (IMVS strain, 1.6–3.0 kg) of either sex were anesthetized with a 25% solution of urethane in 0.9% saline injected intravenously at a dose of 7 ml/kg. Several pilot studies were performed initially with the anesthetic agents ketamine (Ketalar, Parke-Davis) and xylazine (Rompun, Bayer) in combination ($n = 3$), alphaxalone (Saffan, Glaxo) ($n = 2$), and halothane (Fluothane, ICI) and nitrous oxide in combination ($n = 1$). This was done to exclude the possibility that the reaction is somehow linked to the use of urethane as the anesthetic.

The vertex of the skull was exposed and an area cleaned of periosteum. Four 2.5-mm-diameter stainless steel screws were inserted via burr holes, 5 mm lateral to the sagittal suture and 5 mm anterior and posterior to the coronal suture. Care was taken not to pierce the internal lamina of the skull vault.

Each animal was then placed supine and intubated via a tracheostomy. The left common carotid artery was exposed and cannulated with a 1.0-mm-internal-diameter polyethylene catheter (Dural plastics, Dural NSW). The tip of the catheter was advanced to the level of the internal/external carotid bifurcation. The external carotid artery was clamped to ensure that the total volume of selective internal carotid artery injections was delivered to the brain. If the occipital artery branched from the internal carotid artery it was ligated.

The animal was turned prone. Ventilation was begun at 4 ml/kg at 80 breaths/min to maintain normal arterial blood gases. A pair of EMG leads was attached to the muscles of each cheek and four EEG leads were attached to the skull screws (right and left, anteriorly and posteriorly).

Injections were made with an infusion pump (Braun, Melsungen) at a rate of 5 ml/min for a period of 30 sec (i.e., a dose of 2.5 ml). Recordings were made on a Grass polygraph (Grass Instruments, U.S.) and taken continuously from 30 sec before the injection to 30 sec after the recordings returned to normal. The polygraph was calibrated periodically with a voltage divider and set at sensitivities of 0.1 mV/cm (EEG recordings) and 0.2 mV/cm (EMG recordings).

Test solutions were 0.9% saline (Abbott, Sydney), 0.6 mol/l mannitol (BDH, Australia), meglumine iohalamate (280 mg l/ml, Conray

280, May and Baker, England), iohexol (280 mg l/ml, Omnipaque, Nycomed, Oslo), iopromide (280 mg l/ml, Ultravist, Schering, Berlin), and iotrolan (280 mg l/ml, Isovist, Schering, Berlin). The mannitol solution had an osmolality of 650 mOsm/kg, as measured by freezing point depression, and was approximately isosmotic with the iohexol and iopromide solutions.

All test solutions were injected via infusion pump at a rate of 5 ml/min for 30 sec. We have monitored the infusion pressure produced by this regime and have shown that it does not exceed the pressure threshold beyond which blood-brain barrier disruption has been shown to occur [13].

Only one internal carotid artery injection was done in each rabbit because of the known risk of blood-brain barrier damage from a single injection of contrast medium [3, 5]. A selective external carotid artery injection, identical in composition, rate, and duration to the internal carotid artery injection, was then made after moving the clamp from the external to the internal carotid artery. In one animal injected with MGI, EEG changes were recorded on the noninjected side after injection in the internal carotid artery. A second injection (iohexol) was given to investigate the relationship of this paradoxical EEG change to any muscular reaction.

In addition to the electrical monitoring, visible reactions to the test solutions were observed and scored as follows:

0 = no reaction.

1 = slight reaction (quivering of whiskers only, movement of an ear, or slight movement of neck muscles).

2 = a moderate reaction (twitching of the facial muscles).

3 = a severe reaction involving very rapid twitching, often with head movements.

4 = the most severe reaction, involving extremely strong twitching, persisting for several seconds beyond the end of the injection.

Digital subtraction angiography was performed in three rabbits (EEG and EMG recordings were not taken from these animals) to demonstrate the distribution of test solution resulting from selective internal and external carotid artery injections. MGI was used in these experiments to avoid the movement that occurred with the injection of the nonionic contrast material.

A significant group response was determined by using Fisher's exact probability test. Differences between groups in the severity of the facial muscle reaction were assessed by using the Sign test and the Mann-Whitney test.

Results

In rabbits anesthetized with urethane, the cortical EEG recording is dominated by slow waves [11] (Fig. 1). Comparable recordings were obtained in all animals prior to injection. In all cases the preinjection EMG showed little activity (Fig. 2).

1. Internal Carotid Artery Injections

These results are presented in Table 1 and representative EEG and EMG recordings are shown, respectively, in Figures 1 and 2.

During the injection of saline and mannitol, no EEG changes were recorded. Loss of amplitude of the EEG slow waves was recorded during the injection of all the contrast media tested (Fig. 1). In all cases except one the EEG changes were greater (or exclusively) on the injected (left) side. In a single

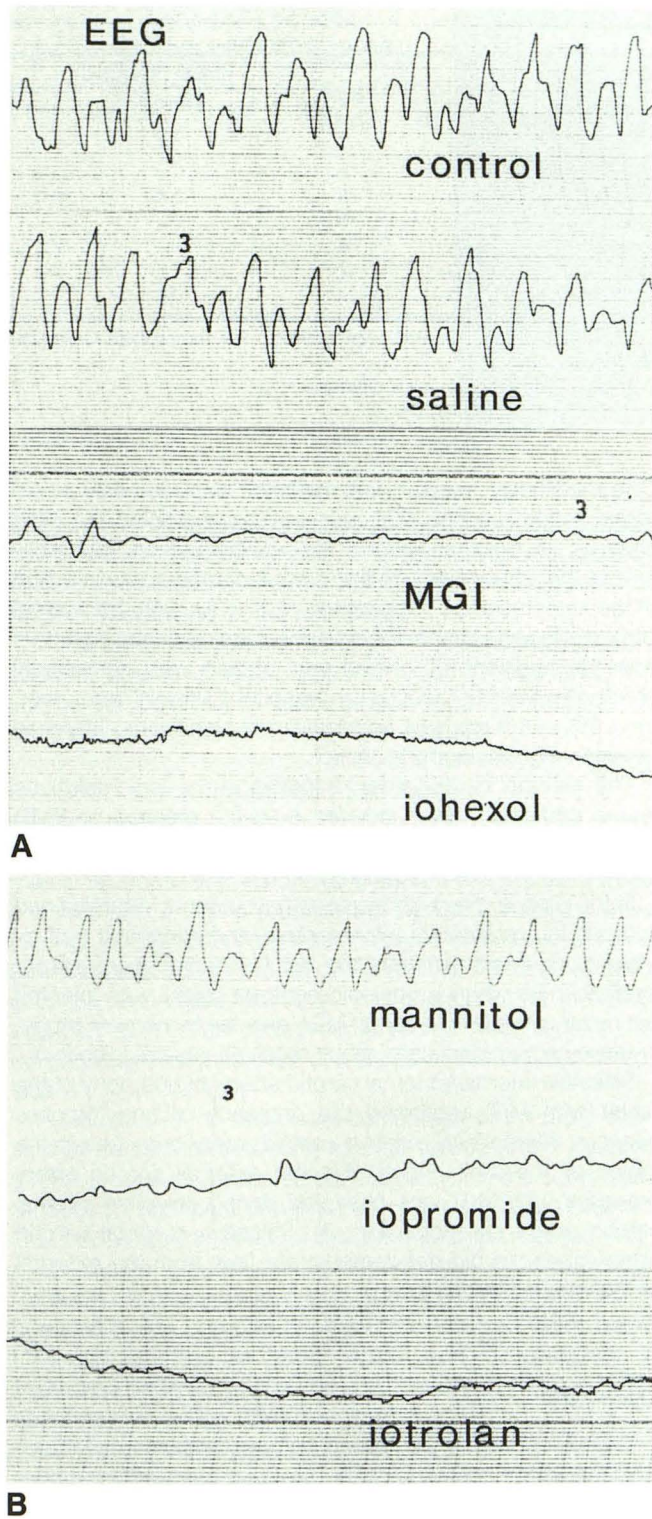


Fig. 1.—A and B, Examples of recordings of left EEG from rabbits during control period (preinjection) and selective internal carotid artery injection with normal saline, MGI, iohexol, mannitol, iopromide, or iotrolan.

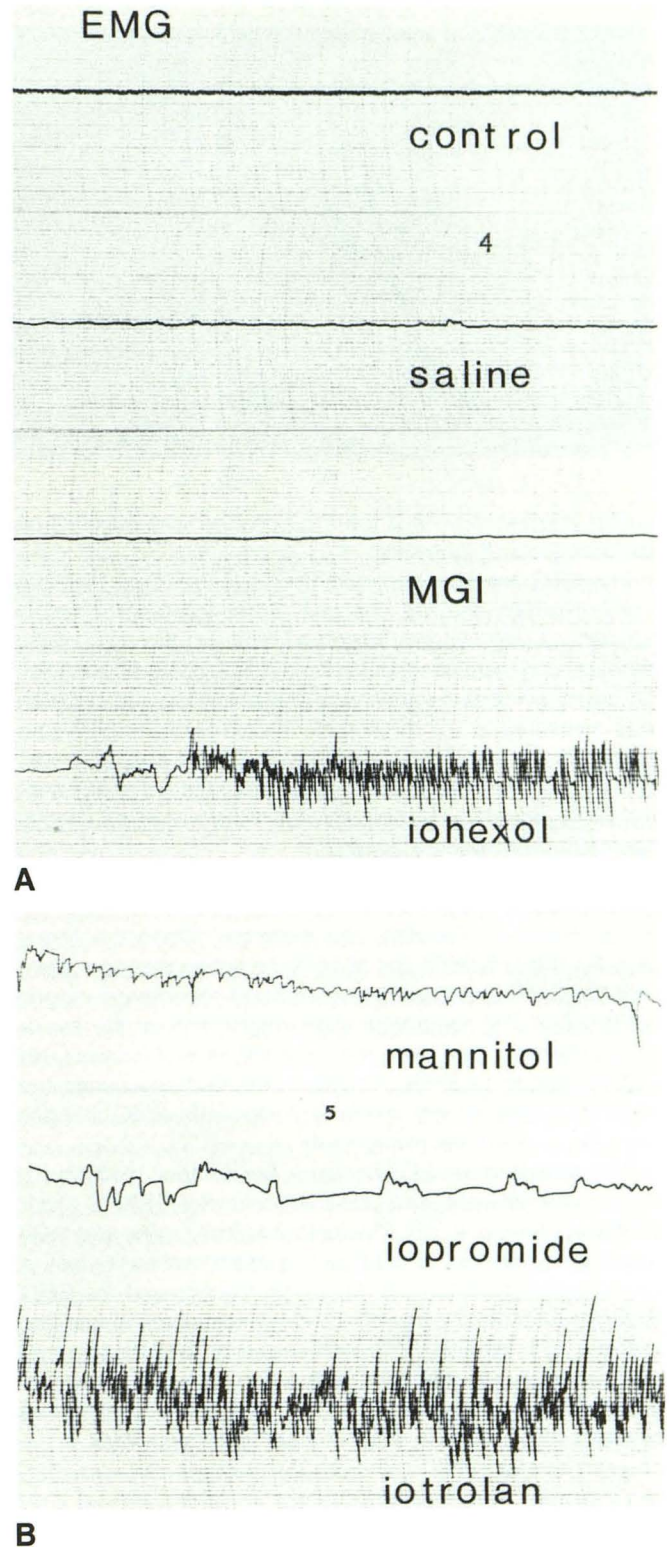


Fig. 2.—A and B, Examples of recordings of left EMG from rabbits during control period (preinjection) and selective internal carotid artery injection with normal saline, MGI, iohexol, mannitol, iopromide, or iotrolan.

TABLE 1: Results of Internal Carotid Artery Injections in Rabbits

Solution	EEG Change	EMG Change	Grade of Visible Reaction ^a				
			0	1	2	3	4
Saline	0	0	5	—	—	—	—
Mannitol	0	5	1	4	2	—	—
MGI	5	0	7	—	—	—	—
Iohexol	7	7	—	1	4	2	— ^b
Iopromide	5	7	—	5	2	—	—
Iotrolan	7	7	—	3	3	1	— ^b

Note.—In all cases $n = 7$, except saline, for which $n = 5$.

^a Refer to text for explanation of grade.

^b Different from mannitol, $p < .05$.

animal injected with MGI the EEG change was maximal on the noninjected (right) side.

The EEG changes occurred over a longer time than the visible reaction or EMG changes. Some lag (approximately 12 sec) was consistently observed between the start of the injection and the first sign of effects (EEG, EMG, and visible). The dead space of the apparatus (three-way tap and catheter) was measured at 0.5 ml (6 sec). Recovery of the EEG to a preinjection state was gradual, and the exact end point was unclear; however, the effect persisted beyond the end of both the EMG-recorded reaction and the visible reaction (lasting approximately twice as long).

The facial muscle reaction was seen consistently with the internal carotid artery injection of the nonionic solutions (iohexol, iopromide, iotrolan, and mannitol). When the cheek muscles were involved, the observed reaction was coincident with the EMG changes. During some of the internal carotid artery injections, some very slight movements of the ear or neck were seen that were not recorded as EMG activity. No visible reaction or EMG changes were recorded during the injection of MGI. As with the EEG changes, the EMG changes were maximal on the injected side.

With regard to the EEG changes, the contrast media were significantly different from saline and mannitol (Fisher's exact probability test, $p < .01$). The ionic solutions (saline and MGI) had significantly less effect (Fisher's exact probability test, $p < .01$) with regard to both the visible reaction and the EMG changes than did the nonionic solutions (iohexol, iopromide, iotrolan, and mannitol). The visible reaction was significantly more severe with iohexol and iotrolan than with mannitol (Mann-Whitney test, $p < .05$), but this difference between mannitol and iopromide was not statistically significant.

2. External Carotid Injections

Results of the external carotid artery injections are presented in Table 2. No EEG changes were observed with external carotid artery injection of any solution with the exception of two of the seven animals injected with iotrolan in which a small EEG change was recorded on the injected side.

Injections of nonionic solutions (mannitol or contrast media) resulted in visible reactions and changes in EMG recordings.

TABLE 2: Results of External Carotid Artery Injections in Rabbits

Solution	EEG Change	EMG Change	Grade of Visible Reaction ^a				
			0	1	2	3	4
Saline	0	0	4	—	—	—	—
Mannitol	0	6	—	—	4	2	1
MGI	0	0	4	—	—	—	—
Iohexol	0	4	—	—	—	1	3 ^b
Iopromide	0	7	—	—	1	3	3
Iotrolan	2	7	—	—	—	4	3 ^b

Note.— $n = 4$ for saline, MGI, and iohexol; $n = 7$ for mannitol, iopromide, and iotrolan.

^a Refer to text for explanation of grade.

^b Different from mannitol, $p < .05$.

One animal only, injected with mannitol, displayed only a very slight visible reaction that was not accompanied by EMG changes. In all other animals the visible reaction was more severe than that seen with the internal carotid artery injection of the same solution (Sign test, $p < .01$). As with the internal carotid artery injections, the severity of the reactions observed with the injections of iohexol and iotrolan was significantly greater than that produced by mannitol (Mann-Whitney test, $p < .05$), but there was no statistically significant difference between iopromide and mannitol.

The external carotid artery injection of the ionic solutions (saline and MGI) never induced a visible reaction or EMG change. This was significantly different from the nonionic group (Fisher's exact probability test, $p < .01$).

In the pilot studies with the anesthetic agents ketamine and xylazine in combination, alphaxalone, and halothane and nitrous oxide in combination, the visible reaction was present in all animals when a nonionic contrast agent was injected but never with the injection of MGI, as seen in the main study. In these pilot studies each rabbit received several injections.

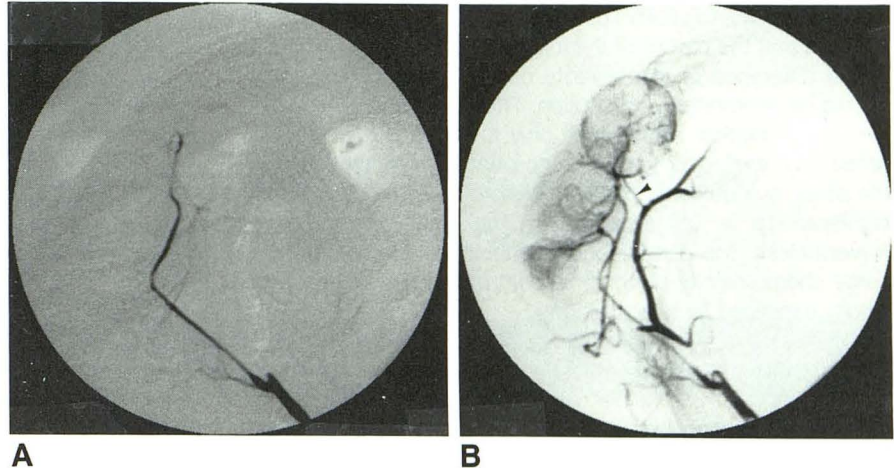
Selective internal/external carotid artery angiography of the rabbit with MGI confirmed the presence of anastomoses between internal and external carotid artery branches in the region of the orbit. Filling of some external carotid artery branches with MGI was observed during selective internal carotid artery injections (Fig. 3). Selective external carotid artery injections did not demonstrate flow from the external to the internal carotid artery.

Discussion

Experiments were performed on anesthetized animals for ethical reasons and to exclude pain as a stimulus for movement. Urethane was chosen because of its ease of use, wide therapeutic window, and stability of anesthesia. This agent causes the EEG in the rabbit to be dominated by slow waves [11].

A pilot study was performed initially by using the anesthetic agents ketamine and xylazine in combination, alphaxalone, and halothane and nitrous oxide in combination. When each of these agents was used, a visible reaction was present in

Fig. 3.—Selective internal carotid artery digital subtraction angiography in the rabbit.
 A, Filling of internal carotid artery is seen.
 B, Late arterial phase shows anastomoses between internal and external carotid artery (arrowhead), plus external carotid artery.



all animals when a nonionic contrast medium was injected but never with the injection of MGI. This pilot study was done to exclude the possibility that the reaction is somehow linked to the use of urethane as the anesthetic.

In this study, we observed that the injection of the nonionic contrast agents (iohexol, iopromide, and iotrolan) into the internal carotid artery of rabbits produced ipsilateral EEG and EMG changes in the ipsilateral facial muscles, coinciding with visible twitching. The injection of an ionic contrast agent (MGI) produced similar ipsilateral EEG changes but no EMG changes or visible twitching. Similarly, internal carotid artery injection with the inert, nonionic solution mannitol (approximately isosmotic with iohexol and iopromide) produced EMG changes and a visible reaction but no EEG changes, while internal carotid artery injection with an inert ionic solution (physiological saline) produced neither EEG changes, EMG changes, nor visible reactions. This suggests that the EMG changes and visible reactions observed after injection of nonionic contrast media are at least partly related to a lack of ions.

A reduction in the slow wave component of the EEG, such as that demonstrated during internal carotid artery injection of all the contrast media tested, but neither of the controls, is thought to represent either an arousal or irritation reaction [14, 15]. While the effect of this on the function of the brain is not known, it represents an abnormality indicative of neurotoxicity. A decrease in the voltage of the EEG recorded in humans during cerebral angiography has also been noted [16] and reported as being "often seen in arousal or in frightened patients" [17]. Other authors have not noted EEG abnormalities during clinical angiography [10].

All the contrast media tested produced similar EEG changes after internal carotid artery injection and cannot be reliably separated on this basis. This is important in that most evidence to date would suggest that the nonionic contrast agents show less neurotoxicity than the ionic contrast agents. Changes were maximal on the injected side but some contralateral effect would be expected through communication of the circulations via the circle of Willis, which is known to be competent in the rabbit [18]. A single animal injected with MGI showed EEG changes that were greater on the nonin-

jected side. A second injection with iohexol in this animal again showed the greater EEG changes on the noninjected side while increased EMG activity was recorded on the injected side. This animal may have had an anomaly of the intracranial vessels favoring delivery to the contralateral cerebral circulation. It was not feasible to confirm this angiographically.

An EEG change was observed in only two animals during external carotid artery injections. Both were injected with the contrast agent iotrolan. We are as yet unable to explain this, as external carotid artery angiography did not demonstrate retrograde filling into the internal carotid artery branches. Retrograde flow is nonetheless theoretically possible, and we propose that this occurred in the two animals concerned.

The mechanism of the muscle reaction is unknown and paradoxical, as the nonionic contrast media have been shown to have less toxicity in parenteral application than do the ionic media [1]. However, incidental observations have been made of involuntary movements during clinical angiography with the nonionic contrast media. The details are unclear, and such movements have generally been ascribed to pain or discomfort [10–12]. The fact that the reaction we have observed occurs with all nonionic solutions (contrast agents and mannitol) suggests that lack of ions is a factor. Recent work by Morris et al. [19, 20] has suggested a need for a minimum sodium ion content in both ionic and nonionic contrast media to prevent ventricular fibrillation in dogs. In that work, long application times (30 sec or more) of the solutions were used. The relevance of Morris's findings to skeletal muscle is unclear and its relevance to the clonic reaction we have been observing is even less clear, as we have used pure meglumine iohalamate (containing no sodium ions at all) without observing a reaction. There is also a possible role of calcium ions, which are known to be required for skeletal muscle function. Golman [7] has also noted this reaction in rabbits and that the addition of small amounts of calcium (or magnesium) ions to the nonionic contrast agent seemed to have a "beneficial effect" on the reaction. Many contrast media contain no calcium ions and in fact contain the calcium chelators sodium citrate and sodium edetate (EDTA) [21]. All the contrast media we tested contain EDTA (0.1 mg/ml), but this was not added

to the mannitol solution. Thus far, there is no information to suggest that the nature of the ion(s) is important.

The difference in the severity of reactions with mannitol should be interpreted with caution. The observation is subjective, the statistical significance only just falls below the .05 probability level, and the difference between iopromide and the other two nonionic contrast agents was not statistically significant ($p > .05$) according to the Mann-Whitney test. Nevertheless, the observed differences are consistent with some chemotoxicity of nonionic contrast media and are not wholly explained by a lack of ions.

We believe that the muscular reaction we have observed is locally and not centrally mediated. A locally mediated effect is likely because the visible reaction and EMG changes are more severe during external carotid artery injections, which result in greater delivery of contrast media to the facial muscles than is obtained with internal carotid artery injections, and both the greatest EEG and EMG changes were observed on the injected side. A centrally mediated effect would be expected to be expressed mostly on the contralateral side. The angiographic evidence of retrograde filling of the external carotid artery and its branches during selective internal carotid artery injection via orbital anastomoses demonstrates the presence of the solution in the local musculature, which is necessary for a locally mediated effect to occur. These anastomoses have been documented previously [22]. Further evidence that the muscle reaction is locally mediated comes from the injections of mannitol in which a visible reaction and EMG changes were observed while no EEG changes were recorded (Table 1).

It is not apparent where this local effect may be mediated, be it peripheral nerve, neuromuscular junction, or the skeletal muscle itself. By neuromuscular pharmacological manipulation of our model the actual site of action may become more clear.

REFERENCES

1. Grainger RG. Intravascular contrast media—the past, the present and the future. *Br J Radiol* **1982**;55:1–18
2. Davis WL, Nelson J, Barry W. Effects of contrast media on cultured myocardial cells. *Invest Radiol* **1986**;21:626–630
3. Wilcox J, Wilson AJ, Evill CA, Sage MR. Comparison of blood-brain barrier disruption by intracarotid iohexol and iodixanol in rabbits. *AJNR* **1987**;8:769–772
4. Dawson P, Harrison M, Weisblatt E. Effect of contrast media on red cell filtrability and morphology. *Br J Radiol* **1983**;56:707–710
5. Wilcox J, Evill CA, Sage MR. Effects of intracarotid ionic and non-ionic contrast materials on the blood-brain barrier in a rabbit model. *Neuroradiology* **1986**;28:271–274
6. Wilson AJ, Wilcox J, Evill CA, Sage MR. The effect of contrast medium viscosity on the blood-brain barrier after intracarotid injection in the rabbit. *AJNR* **1989**;10:129–133
7. Golman K. The blood-brain barrier: effects of nonionic contrast media with and without addition of Ca^{++} and Mg^{++} . *Invest Radiol* **1979**;14:305–308
8. Skalpe IO. The toxicity of nonionic water-soluble monomeric and dimeric contrast media in selective vertebral angiography. *Neuroradiology* **1983**;24:219–223
9. Skalpe IO. The toxicity of nonionic water-soluble contrast media in selective vertebral angiography. *Neuroradiology* **1985**;27:77–79
10. Nakstad P, Sortland O, Aaserud O, Lundervold A. Cerebral angiography with the nonionic contrast medium iohexol and meglumine-Ca-metrizoate. *Neuroradiology* **1982**;23:199–202
11. Skalpe IO, Lundervold A, Tjorstad K. Cerebral angiography with the nonionic (metrizamide) and ionic (meglumine metrizoate) water soluble contrast media. *Neuroradiology* **1977**;14:15–19
12. Wolf K-J, Steidle B, Ganzer D, Seyferth W, Keysser R. Comparative evaluation of low osmolar contrast media in (femoral) arteriography. In: Taenzer V, Zeitler E, eds. *Contrast media in urography, arteriography, and computerised tomography*. Stuttgart: Thieme Verlag, **1983**:102–106
13. Rapoport SI. Blood-brain barrier opening by isotonic saline infusion in normotensive and hypertensive animals. *Acta Radiol (Diagn)* [Stockh] **1978**;19:921–932.
14. Longo VG. *Electroencephalographic atlas for pharmacological research*. Amsterdam: Elsevier, **1962**
15. Sovak M, Ranganathan R, Johnson M. Spectral analysis of lapine EEG: neurotoxicological evaluation of the new nonionic contrast media. *Invest Radiol* **1980**;15:452–456
16. Foltz EL. The EEG effects of intracarotid diodrast. *Electrophysiol Clin Neurophysiol* **1952**;4:113
17. Lundervoldt A, Engeset A. Polygraphic recordings during cerebral angiography. *Acta Radiol (Diagn)* [Stockh] **1966**;5:368–380
18. Jeppsson PG, Olin T. Cerebral distribution of contrast medium and paradoxical location of lesions of the blood-brain barrier in the rabbit. *Acta Radiol (Diagn)* [Stockh] **1975**;16:577–584
19. Morris TW. Ventricular fibrillation during right coronary arteriography with ioxaglate, iohexol and iopamidol in dogs. *Invest Radiol* **1988**;23:205–208
20. Morris TW. The importance of sodium concentration on the incidence of fibrillation during coronary arteriography in dogs. *Invest Radiol* **1988**;23 (Suppl):S137–S139
21. Morris TW, Sahler LG, Violante M, Fischer HW. Work in progress. Reduction of calcium activity by radiopaque contrast media. *Radiology* **1983**;148:55–59
22. du Boulay GH. Comparative neuroradiologic vascular anatomy of experimental animals. In: Newton TH, Potts DG, eds. *Radiology of the skull and brain*. St. Louis: Mosby, **1974**:2775–2778