

Are your **MRI contrast agents** cost-effective?

Learn more about generic **Gadolinium-Based Contrast Agents**.



FRESENIUS
KABI

caring for life

AJNR

**Incidental discovery of intraocular lens prosthesis
by CT.**

J C Chaloupka and M Castillo

AJNR Am J Neuroradiol 1990, 11 (5) 1083-1084

<http://www.ajnr.org/content/11/5/1083.2.citation>

This information is current as
of April 20, 2024.

CT Enhancement After Use of Cocaine

It is well known that the great vein of Galen and the venous sinuses often are seen on non-contrast-enhanced CT, and that in several situations [1], the major cerebral arteries also may be seen. We report a series of several patients in Hartford, Connecticut, in whom the major middle cerebral arteries and the circle of Willis (Fig. 1) were visualized on unenhanced CT after the patients recently had used cocaine intranasally. All patients were in their twenties.

The CT scans were all done between July and September 1989 on a GE 9800 machine. It is possible that the supply of cocaine in Hartford during this period was tainted with an agent that caused enhancement of vessels. The patients had received no IV contrast agents before their CT scans.

We would like to know if others have reported such findings on non-contrast-enhanced CT scans of their patients and if those findings were associated with the use of cocaine.

A. Hall
V. Wagle
Hartford Hospital
Hartford, CT 06115

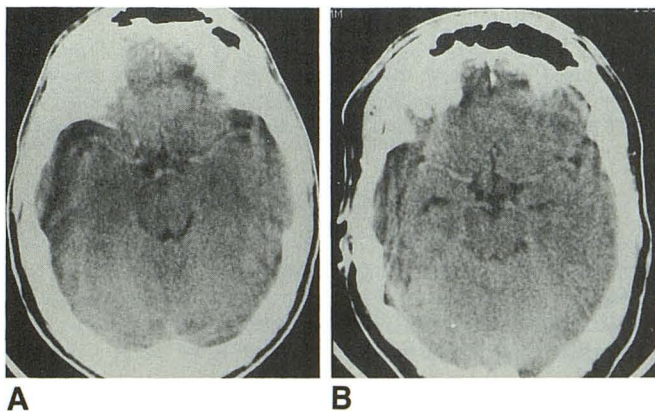


Fig. 1.—A and B, CT scans of two patients who recently had used cocaine intranasally show bilateral enhancement of middle cerebral arteries (A) and of middle, posterior, and anterior cerebral arteries (B).

REFERENCE

- Osborne D, Bohan T, Hodson A. CT Demonstration of hyperdense cerebral vasculature due to bromide therapy. *J Comput Assist Tomogr* 1984;8(5):982-984

Editor's note.—This phenomenon may be seen in polycythemia and dehydration. The Journal would welcome the thoughts of readers on this topic.

Incidental Discovery of Intraocular Lens Prosthesis by CT

It has been our recent experience that an intraocular lens prosthesis frequently is discovered incidentally when 0° angle gantry positioning is used for routine CT scans of the head.

Many institutions have replaced the traditional standard of obtaining transverse scans of the head by performing CT parallel to the orbitomeatal line (i.e., 20° angulation to the true axial plane). Instead, they use sections that are parallel to McGregor's line (i.e., 0° angulation, or true axial plane). One result of this change in technique is complete inclusion of the orbits in routine CT scans of the head. As expected, a variety of nonpathologic variants and asymptomatic diseases are being detected incidentally with increasing frequency [1].

We have found that an intraocular lens prosthesis has a characteristic appearance on CT scans that is distinctly different from that of a normal native lens (Fig. 1). A normal native lens has homogeneous high attenuation and is biconvex, with the anterior surface commonly being mildly flattened. Its thickness in adults is 4-5 mm [2]. In the elderly, both the anterior and posterior surfaces of the lens can become flattened more prominently [3]. In contrast, an intraocular lens prosthesis appears as a linear or minimally curvilinear structure

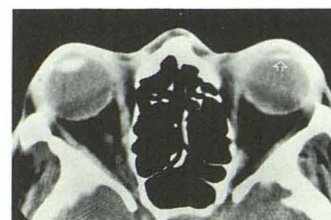


Fig. 1.—Axial CT scan of head at level of midorbits shows characteristic features of an intraocular prosthetic lens (arrow) in left globe. Lens in right globe is normal.

of high attenuation. The prosthetic lens is also thinner, only about 1–2 mm thick. It is otherwise in the same anatomic position and orientation as a native lens.

These characteristic CT features of an intraocular lens prosthesis readily distinguish it from most diseases of the intraocular lens or a traumatically introduced foreign body within the anterior chamber. It is theoretically possible that a similar appearance may be seen with posttraumatic cataracts with associated spontaneous phacolysis and various types of phacectomy, as a residual capsular membrane may be present [4]; however, we have not yet encountered such examples.

John C. Chaloupka
Mauricio Castillo
Emory University Hospital
Atlanta, GA 30322

REFERENCES

- Castillo M, Hudgins P. Incidental discovery of dislocated lens by computed tomography. *Arch Ophthalmol* 1989;107:489
- Hogan MJ, Alvarado JA, Weddell JE. *Histology of the human eye: an atlas and textbook*. Philadelphia: Saunders, 1971:33
- Williams PL, Warwick R, eds. *Gray's anatomy*, 36th ed. Philadelphia: Saunders, 1980:1176–1177
- Way LW. *Current surgical diagnosis and treatment*, 6th ed. Los Altos, CA: Lange, 1983:825

Clinically Silent Infarcts Shown by MR After Cerebral Angiography

We report what we believe to be five cases of clinically silent infarcts shown on MR performed after cerebral angiography. One patient in the group was a 40-year-old man with a scalp mass who had brief nausea after vertebral arteriography. MR on the day after arteriography showed four areas of hyperintensity in the cerebellum on T2-weighted images (Fig. 1A) although the results of his neurologic examination were normal.

Another patient was a 60-year-old man with subarachnoid hemorrhage. Cerebral arteriograms were normal, and MR images obtained 1 day later were also normal. A second arteriogram was acquired 12 days after the first, and MR images obtained 1 week after the second angiogram showed what was thought to be a subacute infarct of the right caudate nucleus (Fig. 1B), not evident on the earlier MR examination.

In a third case, postangiographic MR showed what was thought to be a small cerebellar infarct in a 17-year-old patient and, in a fourth case, showed a basal ganglia infarct not seen on MR images obtained before angiography. In the fifth case, MR showed a left thalamic infarct in a 28-year-old man after angiography with multiple injections of contrast material into the vertebral artery.

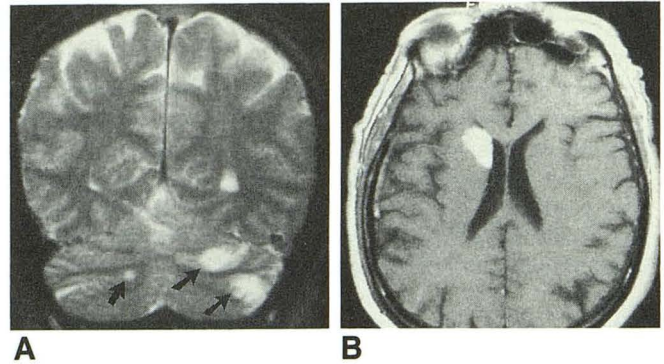


Fig. 1.—MR images obtained after cerebral angiography show clinically silent brain infarcts in two patients.

A, T2-weighted, coronal image, 200/80, of one patient shows multiple areas of increased signal in cerebellum (arrows).

B, Postcontrast, T1-weighted image, 500/30, of another patient shows intense signal arising from head of right caudate nucleus extending into internal capsule and putamen. This suggests breakdown of blood-brain barrier, consistent with subacute nature of this infarction.

Although the frequency of neurologic deficits associated with cerebral angiography is low [1–3], these five cases lead us to believe that the frequency of infarcts is higher than clinical studies would suggest. We wonder if this may be the tip of an iceberg of clinically silent, postangiographic infarcts that may be confusing if not recognized as such.

Alex Mamourian
Burton P. Drayer
Barrow Neurological Institute
Phoenix, AZ 85013

REFERENCES

- Dion JE, Gates PC, Fox AJ, Barnett HJ, Blom RJ. Clinical events following neuroangiography: a prospective study. *Stroke* 1987;18:997–1007
- Mani RL, Eisenberg RL, MacDonald EJ Jr, Pollock JA, Mani JR. Complications of catheter cerebral angiography: analysis of 5,000 procedures. I. Criteria and incidence. *AJR* 1978;131:861–865
- Kerber CW, Cromwell LD, Drayer BP, Bank WO. Cerebral ischemia. I. Current angiographic techniques, complications, and safety. *AJR* 1978;130:1097–1103

Editor's note.—Preangiographic MR studies were not available in all of these cases, and the causes of the infarcts are uncertain. However, this is an interesting hypothesis. The Journal would welcome additional letters or reports of controlled studies on this subject.

Letters are published at the discretion of the Editor and are subject to editing.

Letters to the Editor must not be more than two double-spaced, typewritten pages. One or two figures may be included. Abbreviations should not be used.

Material being submitted or published elsewhere should not be duplicated in letters, and authors of letters must disclose financial associations or other possible conflicts of interest.

Letters concerning a paper published in the *AJNR* will be sent to the authors of the paper for a reply to be published in the same issue. Opinions expressed in the Letters to the Editor do not necessarily reflect the opinions of the Editor.