AJNR

Far-lateral disk herniation: treatment by automated percutaneous diskectomy.

G Onik, J Maroon and Y L Shang

AJNR Am J Neuroradiol 1990, 11 (5) 865-868
http://www.ajnr.org/content/11/5/865

Far-Lateral Disk Herniation:
Treatment by Automated Percutaneous Diskectomy

Gary Onik[1]
Joseph Maroon[2]
Yulin Shang[3]

Automated percutaneous diskectomy has certain advantages over other surgical approaches to the treatment of far-lateral disk herniation; primarily, the procedure can be performed under local anesthesia without soft-tissue disruption. We describe four patients with far-lateral herniations who were successfully treated with the procedure.

***AJNR* 11:865–868, September/October 1990**

Treatment of extremely far-lateral disk herniations poses somewhat of a dilemma [1]. The standard interlaminar approach may necessitate a large, if not complete, facetectomy to expose the herniation, thereby increasing soft-tissue trauma and potentially creating instability [2, 3]. A paraspinal approach that obviates facet removal has been described [4, 5]; however, the scarcity of this type lesion, with the infrequent use of this approach to the spine, means that the anatomy is unfamiliar to most neurosurgeons.

Automated percutaneous diskectomy, which has recently gained attention as a noninvasive alternative treatment for uncomplicated disk herniations [6–9], may also be a good alternative treatment for the extremely far-lateral herniated nucleus pulposus, provided the herniation is still contained. Performing the procedure from a posterolateral approach under local anesthesia affords excellent proximity to the herniation as well as safety, since the chance of nerve root injury is greatly minimized when the patient is awake.

We describe four patients with extremely far-lateral herniations who were successfully treated by automated percutaneous diskectomy.

Subjects and Methods

Automated percutaneous diskectomy is performed in the operating room or radiologic suite under C-arm fluoroscopic control. A preoperative one-slice planing CT scan is taken in the prone position to identify any bowel in the intended path of the procedure. Strict sterile technique is followed, and continuous vital sign monitoring with pulse oximetry is carried out. The patient is placed in the lateral decubitus position, and an entry point is chosen approximately 10 cm from the midline at the level of the herniated disk as determined by the CT scan. Local anesthetic is used to anesthetize the skin at the entry point and the underlying fascia and musculature. An 18-gauge pencil-tip trocar with removable hub is placed down to the disk space. Before penetrating the anulus, an anteroposterior view is obtained to confirm that the tip of the trocar is lateral to a line that joins the medial border of the pedicles, confirming that the trocar is not traversing the thecal sac.

During trocar placement, the patient is monitored for signs of radicular pain. When radicular pain is experienced, the trocar is withdrawn its full length and then redirected. Once confirmed to be outside the thecal sac, the trocar is advanced into the center of the disk. Anteroposterior and lateral fluoroscopic views are obtained to confirm this location. After confirmation, the hub of the trocar is removed, and a 2.8-mm cannula with an inner-tapered dilator is passed over the hubless trocar. When the 2.8-mm cannula reaches the anulus, its position against

Received August 14, 1989; revision requested October 2, 1989; revision received March 9, 1990; accepted March 12, 1990.

[1] Department of Diagnostic Radiology, Room 3901, Presbyterian-University Hospital, De Soto at O'Hara Sts., Pittsburgh, PA 15213. Address reprint requests to G. Onik.

[2] Department of Neurosurgery, Allegheny General Hospital, Pittsburgh, PA 15212.

[3] University of Pittsburgh, Pittsburgh, PA 15213.

0195–6108/90/1105–0865

the anulus is confirmed by a 90° oblique view to the cannula. With the outer cannula in place and the 18-gauge trocar still in the center of the disk, a trephine is placed over the 18-gauge trocar through the cannula, and the anulus is incised. The trephine and trocar are removed, and the Nucleotome (Surgical Dynamics, Inc., Alameda, CA) is placed through the outer cannula into the disk. It is confirmed to be within the disk on two views, and then the disk is aspirated for approximately 20 min.

Case Reports

Case 1

A 48-year-old man had not worked for 6 weeks owing to severe pain and paresthesia in the left anterior thigh. The patient did not respond to bed rest, analgesics, and physical therapy. His physical examination was remarkable for decreased pin-prick sensation over the L4 distribution on the left with decreased knee jerk and normal strength in his quadriceps. A CT scan showed a far-lateral herniated disk at the L4–L5 level to the left consistent with the patient's symptoms (Fig. 1). A percutaneous diskectomy at the L4–L5 level on the left side was performed by means of the technique described above. The patient was discharged from the hospital the next day without complications. He reported relief of his symptoms 1 week after the procedure and was asymptomatic at follow-up approximately 2 years later.

Case 2

A 45-year-old female railroad employee injured herself while coupling and uncoupling trains. She presented with a 17-month history of right anterior thigh pain with associated paresthesia. She had been unable to work since her injury. The patient did not respond to conservative therapy, which consisted of rest, physical therapy, and nonsteroidal antiinflammatory medication. Her physical examination revealed decreased strength on the right of the quadriceps with decreased right knee jerk. A CT scan revealed a far-lateral herniated nucleus pulposus on the axial image consistent with her symptoms (Fig. 2). An automated percutaneous lumbar diskectomy provided immediate relief of her symptoms. Physical examination at 6 weeks revealed increased strength in the quadriceps with persistent decreased knee jerk. She remains asymptomatic 1½ years after the procedure.

Case 3

A 50-year-old waitress presented with right anterior thigh pain of 4 months' duration. She did not respond to conservative therapy, which consisted of epidural steroids and physical therapy. Physical examination showed a decreased right knee jerk and was otherwise unremarkable. Her CT examination showed a far-lateral herniation with deviation of the right L4 nerve root posteriorly, consistent with her symptoms (Fig. 3). A percutaneous diskectomy provided immediate relief of her symptoms. She remains asymptomatic more than 3 years after the procedure.

Case 4

A 39-year-old male construction worker presented with a 2-month history of low back and right anterior thigh pain when he stressed himself. While on physical therapy his pain progressed in severity and became constant. His CT scan revealed a far-lateral herniated nucleus pulposus impinging on the L4 nerve root as it was exiting the neural foramen (Figs. 4 and 5). The patient underwent an L4–L5 percutaneous diskectomy, which gave him immediate relief from his pain. He remains asymptomatic more than 1 year after the procedure.

Discussion

Far-lateral disk herniations occur most frequently at the L4–L5 level and, next most often, at the L3–L4 level, imping-

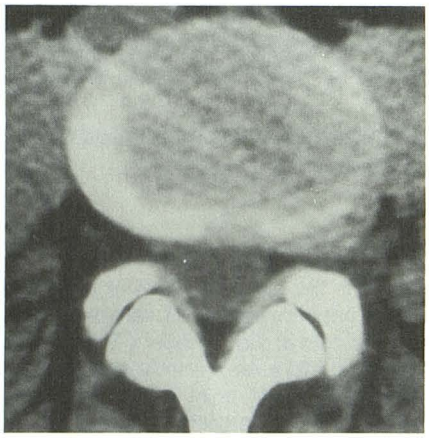

Fig. 1.—Axial CT scan shows a far-lateral herniation at L4–L5 disk level on the left. Note that space between disk and L4 nerve root is no longer present (compared with right side). The margins of herniation are smooth, and there is no migration superiorly or inferiorly, indicating a contained herniation.

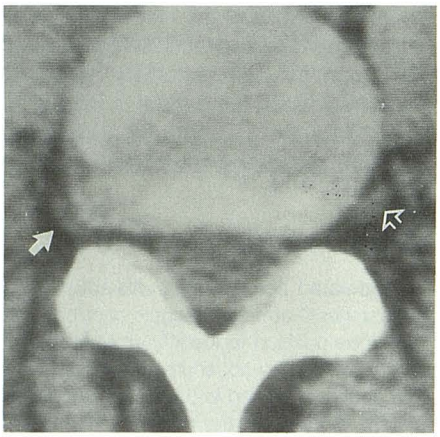

Fig. 2.—Axial CT scan shows a far-lateral right-sided herniation with posterior displacement of right L4 nerve root (*solid arrow*) as compared with left (*open arrow*). The margins are smooth, and there is no evidence of migration superiorly or inferiorly, indicating a contained herniation.

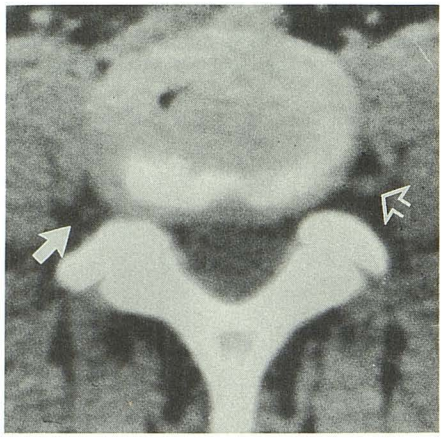

Fig. 3.—Axial CT scan shows a far-lateral herniation at L4–L5 disk level on the right. Posterior displacement of L4 nerve root (*solid arrow*) can be seen, particularly when compared with left side. Space between nerve root and anterior surface of superior articular facet on that side is closed down (compare with opposite side, *open arrow*). Since the instruments for percutaneous diskectomy are supposed to be inserted behind the nerve root, displacement of the nerve root, which narrows this space, can make the procedure more difficult.

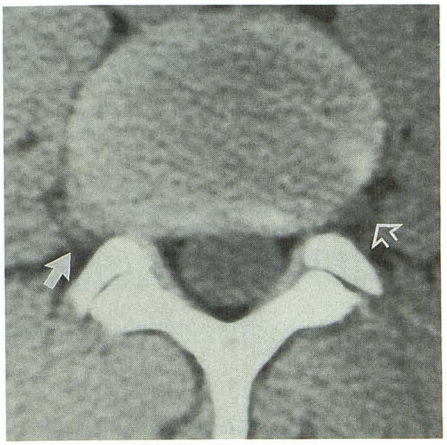

Fig. 4.—Axial CT scan shows right L4 nerve root (*solid arrow*) displaced posteriorly and flattened as compared with the left (*open arrow*).

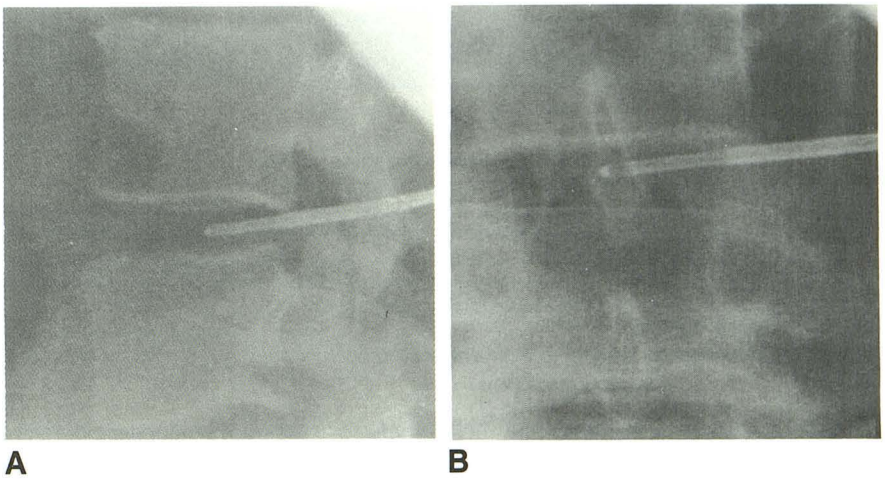

Fig. 5.—*A* and *B*, Anteroposterior (*A*) and lateral (*B*) radiographs show placement of Nucleotome into L4–L5 disk of the patient in Figure 4. The probe takes a posterolateral course to the disk space. The probe had to be maneuvered past the nerve root; therefore, its trajectory is not exactly parallel to the disk space.

ing on the nerve root that has already exited the neural foramen. The characteristic clinical picture includes anterior thigh pain, a negative straight-leg-raising test, and a reduced or absent knee jerk reflex [3]. When the point of compression is outside the confines of the neural foramen, as it is in this entity, myelography is usually nondiagnostic. CT and MR studies now provide the most accurate means of diagnosis.

The surgical approach to the extraforaminal herniation can be difficult. The posterior interlaminar approach may require a facetectomy of varying degrees; however, facetectomy raises concerns about subsequent instability in the treatment of these patients. While the development of instability after facetectomy is controversial and the exact percentage of patients at risk is not clear, the evidence of preexisting instability (spondylolisthesis), the presence of concomitant hypertrophic degenerative changes, and the level at which the facetectomy is done all may be factors in the development of instability [3].

To avoid this problem, a number of operations that use a paramedian approach to the far-lateral herniation have been developed. In 1953 Watkins performed an operation lateral to the sacrospinalis muscle in which he removed a portion of the ilium with retraction of the entire muscle group medially. Ray used a similar approach, proceeding lateral to the sacrospinalis muscle group. Wiltse and Spencer [5], in a modified approach, split the muscle group between the multifidus and the longissimus muscles, obviating removal of the ilium. This lateral approach, however, is unfamiliar to many surgeons, and in our institution there has been a reluctance to use this technique, particularly in the obese patient. Because the nerve root may be draped over the disk fragment, there is the danger of nerve injury, especially when the surgeon is inexperienced in using this approach.

Automated percutaneous diskectomy appears to be an alternative to both these methods. The path to the disk is direct in relation to the herniation. The instruments pass close to the herniation and may actually go through it in many instances. Because the procedure is done under local anesthesia, the possibility of nerve root injury is minimized. If a patient experiences radicular pain during the procedure, the position of the trocar is changed. In addition, the instruments do not violate the spinal canal, thus eliminating the problem of epidural fibrosis. Finally, there is no bone removal or danger of instability.

While these four cases were successfully treated, it is known that a large number of far-lateral herniations are actually extruded fragments. To obtain a high percentage of successful results, patients must be carefully selected, and we continue to use the criterion of fragment migration above or below the disk space to exclude patients from this procedure. In addition, all patients should have the classic clinical findings of anterior thigh pain with absent knee jerk or quadriceps weakness to confirm the diagnosis.

Automated percutaneous diskectomy in the extremely far-lateral herniation may technically be somewhat more difficult than automated percutaneous diskectomy in more usually placed herniations. Commonly, the nerve root is pushed posteriorly by the herniation in this entity, decreasing the space behind the nerve root and just anterior to the superior articular facet, which is usually the path the instruments take. In one case, the nerve root was not directly impinged upon, but pressure on the herniation by the instruments indirectly increased the pressure on the nerve root, producing radicular symptoms. Finally, there is theoretically an increased chance for reherniation extremely far laterally owing to the hole in the anulus made with the introduction of the instruments.

In conclusion, the extremely far-lateral herniation represents a unique problem in both diagnosis and treatment. The two traditional surgical approaches to this entity have definite disadvantages. Automated percutaneous diskectomy, which can be performed under local anesthesia without violating the epidural space or necessitating facet removal, appears to be

a reasonable alternative approach to the extremely far-lateral herniation in selected cases.

REFERENCES

1. Godersky JC, Erickson DL, Seljeskog EL. Extreme lateral disc herniation: Diagnosis by computed tomographic scanning. *Neurosurgery* **1984**;14:549–551
2. Jackson RP, Glah JJ. Foraminal and extraforaminal lumbar disc herniation: diagnosis and treatment. *Spine* **1986**;12:577–585
3. Abdullah AF, Wolber PGH, Warfield JR, Gunadi IK. Surgical management of extreme lateral lumbar disc herniations: Review of 138 cases. *Neurosurgery* **1988**;22:648–653
4. Ray CD. The paralateral approach to decompressions for lateral stenosis and far lateral lesions of the lumbar spine. In: Watkins E, ed. *Lumbar discectomy and laminectomy*. Collis Aspen, **1987**:217–227
5. Wiltse LL, Spencer CW. New uses and refinements of the paraspinal approach to the lumbar spine. *Spine* **1988**;13:696–706
6. Onik GM, Helms C, Hoaglund F, Morris J. Percutaneous lumbar diskectomy using a new aspiration probe: porcine and cadaver model. *Radiology* **1985**;155:251–252
7. Onik GM, Helms C, Hoaglund F, Morris J. Successful percutaneous lumbar diskectomy using a new aspiration probe: a case report. *AJNR* **1985**;6:290–293
8. Onik G, Maroon J. Percutaneous automated discectomy—a less invasive alternative for the treatment of herniated lumbar discs. *Perspectives Radiol* **1988**;1:2
9. Davis GW, Onik GM. Clinical experience with automated percutaneous discectomy. *Clin Orthop* **1989**;238:98–103