AJNR

Intracranial complication during insertion of a nasogastric tube.

S A Glasser, W Garfinkle and M Scanlon

AJNR Am J Neuroradiol 1990, 11 (6) 1170
http://www.ajnr.org/content/11/6/1170.citation

Intracranial Complication During Insertion of a Nasogastric Tube

Insertion of a nasogastric tube is not without hazards. One of the most serious is inadvertent intracranial placement. Of 11 previously reported cases [1–8], all occurred in patients who had craniofacial or maxillofacial trauma. We report a case of inadvertent intracranial complication directly related to the placement of a nasogastric tube in a patient who had no history of head trauma.

Case Report

An attempt was made to insert a nasogastric tube through the right nares of a 45-year-old woman who had been vomiting for 2 weeks. She was fully alert, cooperative, and oriented before the procedure and had no known history of previous head trauma. Resistance was encountered during placement of the tube, and moderate amounts of bright red blood returned through the tube. Repeated injections of air were made through the tube, but no air sounds could be heard in the epigastrium. As the tube was advanced farther, the patient became increasingly somnolent. Again several hundred milliliters of air was injected, but the location of the tube was not established, and the tube was withdrawn. Simultaneously, the patient became completely unresponsive.

A CT scan of the head was performed immediately and showed subdural pneumocephaly of the right anterior and middle cranial fossae and small collections of air in the right frontal and occipital lobes (Fig. 1). Opacification of the right ethmoidal, maxillary, and frontal sinuses were noted also. However, MR performed 4 months before had shown sinusitis in exactly the same locations.

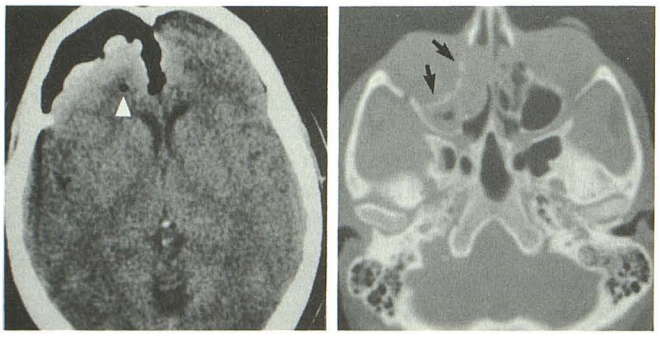

A B

Fig. 1.—Intracranial complication during insertion of a nasogastric tube. *A* and *B*, CT scans show pneumocephalus and small areas of intraparenchymal air (*arrowhead, A*) and opacification of right ethmoidal and maxillary sinuses (*arrows, B*).

Discussion

This case illustrates that trauma is not a necessary predisposing factor for inadvertent intracranial placement of a nasogastric tube. We hypothesize that a thin cribiform plate, perhaps the result of sinusitis, may precipitate an intracranial complication during insertion of the tube.

This case also illustrates the wisdom of obtaining radiologic confirmation of the tube's location before introducing air or fluids often used to help confirm the location. Bouzarth [9] recommends that a precurved Silastic nasopharyngeal airway be inserted through the patient's nose before the nasogastric tube is inserted. The preformed curve of the airway tends to direct the nasogastric tube away from the cribiform plate. Following these precautions should help prevent intracranial complications during insertion of a nasogastric tube.

Scott A. Glasser
William Garfinkle
Mary Scanlon
Albert Einstein Medical Center
Philadelphia, PA 19141

REFERENCES

1. Borovich B, Braun J, Yosefovich T, Gullburd J, Gruchkiewicz J, Peyser E. Intracranial penetration of nasogastric tube. *Neurosurgery* **1981**;8:245–247
2. Fletcher S, Henderson L, Miner M, Jones J. The successful surgical removal of intracranial nasogastric tubes. *J Trauma* **1987**;27:948–952
3. Fremstad J, Martin S. Lethal complication from insertion of nasogastric tube after severe basilar skull fracture. *J Trauma* **1978**;18:820–822
4. Gregory J, Turner P, Reynolds A. A complication of nasogastric intubation: intracranial penetration. *J Trauma* **1978**;18:823–824
5. Gustavsson S, Forsberg A, Ryrberg CH. The accidental introduction of a nasogastric tube into the brain. *Acta Chir Scand* **1978**;144:55–56
6. Koch K, Becker G, Edwards M. Intracranial placement of a nasogastric tube. *AJNR* **1989**;10:443–444
7. Moustoukas N, Litwin M. Intracranial placement of a nasogastric tube: an unusual complication. *South Med J* **1983**;76:816–817
8. Seebacher J, Noxik D, Mathiew A. Inadvertent intracranial introduction of a nasogastric tube: a complication of severe maxillofacial trauma. *Anesthesiology* **1975**;42:100–103
9. Bouzarth W. Intracranial nasogastric tube insertion (editorial). *J Trauma* **1978**;18:818–819