

The **next generation** GBCA  
from Guerbet is here

Explore new possibilities >

Guerbet | 

© Guerbet 2024 GUOB220151-A

# AJNR

## **Multiple dural arteriovenous fistulas of the cranium and spine.**

S L Barnwell, V V Halbach, C F Dowd, R T Higashida, G B Hieshima and C B Wilson

*AJNR Am J Neuroradiol* 1991, 12 (3) 441-445  
<http://www.ajnr.org/content/12/3/441>

This information is current as  
of March 20, 2024.

# Multiple Dural Arteriovenous Fistulas of the Cranium and Spine

Stanley L. Barnwell<sup>1,2</sup>  
 Van V. Halbach<sup>1,2</sup>  
 Christopher F. Dowd<sup>2</sup>  
 Randall T. Higashida<sup>1,2</sup>  
 Grant B. Hieshima<sup>1,2</sup>  
 Charles B. Wilson<sup>1</sup>

Dural arteriovenous fistulas are acquired lesions that usually involve the dura around the cavernous sinus. The transverse, sigmoid, and superior sagittal sinuses may be affected occasionally. With the exception of bilateral cavernous sinus dural arteriovenous fistulas, the simultaneous occurrence of dural arteriovenous fistulas at two locations is rare. Among 105 patients evaluated for dural arteriovenous fistulas, we identified seven patients with fistulas at two sites. The age of the patients ranged from 27 to 74 years. Presentation was related to hemorrhage in three patients, loss of vision in four, and a bruit and headaches in one. Patients were treated with combined surgical and endovascular techniques. All treated lesions were completely closed with no mortality or permanent morbidity.

The presence of multiple fistulas must be considered in patients being evaluated for dural arteriovenous fistulas. Patients with multiple fistulas usually present with life-threatening hemorrhages or acute neurologic decline; the risk factor for hemorrhages, including those related to venous outflow obstruction, is high in patients with multiple dural arteriovenous fistulas.

*AJNR* 12:441-445, May/June 1991

Dural arteriovenous fistulas (DAVFs) constitute 10–15% of all intracranial arteriovenous malformations [1]. They occur most often in the region of the cavernous, transverse, and sigmoid sinuses, but they may occur in any dural structure. Recent evidence suggests that DAVFs are acquired lesions and not malformations; fistulous connections presumably develop in a thrombosed dural sinus [2–4].

Bilateral cavernous sinus fistulas are relatively common, but DAVFs that occur at two separate sites are rare; to our knowledge, only two well-documented cases have been described [5, 6]. In a retrospective review of the 105 patients with DAVFs treated at our institution over the past 10 years, we identified seven patients with multiple DAVFs. Multiple lesions refer to fistulas that are distinct anatomically in relation to arterial inflow, location of the fistulous site, and venous drainage. We report here the clinical presentation, angiographic evaluation, and results of treatment using combined surgical and interventional radiologic techniques.

## Subjects and Methods

### Subjects

The radiologic and clinical findings for the seven patients who were treated for multiple DAVFs at our institution between 1979 and 1989 were reviewed retrospectively. The four women and three men ranged in age from 27 to 74 years (mean, 57 years). Unlike the strong female preponderance reported for DAVFs in the cavernous sinus [7], our study contained a nearly equal distribution of men and women.

Received April 3, 1990; revision requested June 26, 1990; revision received November 13, 1990; accepted November 18, 1990.

<sup>1</sup> Department of Neurological Surgery, School of Medicine, University of California, San Francisco, CA 94143. Address reprint requests to S. L. Barnwell, % The Editorial Office, 1360 Ninth Ave., Suite 210, San Francisco, CA 94122.

<sup>2</sup> Department of Radiology, School of Medicine, University of California, San Francisco, CA 94143.

0195-6108/91/1203-0441

© American Society of Neuroradiology



### Causes

DAVFs developed spontaneously in all patients; no patient had a history of trauma. Patient 2 was on oral contraceptives and had multiple peripheral venous thromboses. A hematologic work-up was unremarkable for a hypercoagulable state.

### Presenting Signs and Symptoms

Presentations are summarized in the Case Reports section of this article. Rupture of the DAVF produced intracerebral hematomas in both patients with supratentorial DAVFs (patients 2 and 5). After embolization of the transverse sinus DAVF and surgical closure of the superior sagittal sinus DAVF, patient 2 presented a second time with a residual transverse sinus fistula that caused increased intracerebral pressure and decreasing vision, a pseudotumor cerebri syndrome. Patient 3 had a spinal DAVF and presented with a lower extremity myelopathy. Patients 1, 6, and 7 presented with a cavernous sinus syndrome associated with a carotid-cavernous DAVF. Patient 4 presented with a 20-year history of bruit and headaches.

### Location

Locations of DAVFs are summarized in Table 1. DAVFs occurred at separate sites in all seven patients. Multiple sites included the cavernous sinus and ethmoidal groove or inferior petrosal sinus (patients 1 and 7), midregion of the superior sagittal sinus, left transverse sinus, and left sigmoid sinus (patient 2), the spine at C1–C2 and C6–C7 (patient 3), right and left transverse sinuses (patient 4), left ethmoidal groove and posterior fossa (patient 5), and right cavernous sinus and sphenoparietal sinus (patient 6).

### Arterial Supply

Hypertrophied dural vessels provided the arterial supply to the fistulas (Table 1). Posterior fossa, superior sagittal sinus, and sphenoparietal dural fistulas were supplied by branches from the external carotid artery, the internal carotid artery via the meningohypophyseal trunk, and the vertebral artery. Cavernous sinus fistulas were supplied from either the tentorial branch of the meningohypophyseal trunk or from the capsular artery. Ethmoidal groove DAVFs were supplied by ethmoidal branches from the ophthalmic artery.

Each fistula had venous drainage separate from the other fistulas. The venous drainage went either to the involved sinus or, if this sinus was thrombosed, to collateral cortical veins (Table 1).

### Venous Drainage

Each fistula had venous drainage separate from the other fistulas. The venous drainage went either to the involved sinus or, if this sinus was thrombosed, to collateral cortical veins (Table 1).

### Treatment

Therapy for these fistulas involved a variety of endovascular techniques and surgery. Particulate embolic agents, coils, silk, and liquid adhesives were used for transarterial or transvenous embolization. In cases where endovascular techniques were incomplete, surgery to coagulate or embolize the fistula was performed.

## Case Reports

### Case 1

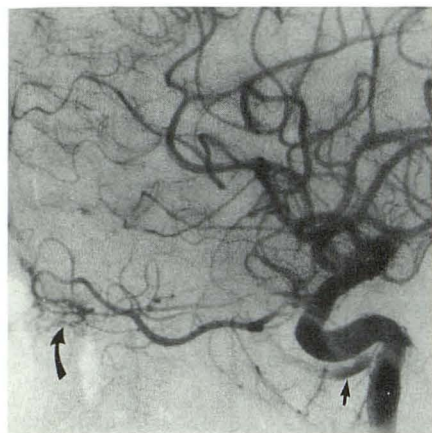
This 62-year-old woman presented with a 15-month history of bruit, proptosis, and decreased vision. Angiographic evaluation demonstrated a DAVF involving the right cavernous sinus, supplied by the right and left meningohypophyseal arteries and draining into the superior ophthalmic vein (Fig. 1). A second fistula was found in the right ethmoidal groove, supplied by the right and left ethmoidal arteries from the ophthalmic arteries and draining to a parafalcine vein. The fistula in the cavernous sinus was treated by intraoperative coil embolization, and the fistula in the ethmoidal groove was coagulated. Postoperative angiograms showed that both fistulas were closed. The patient died of unrelated causes 1 month later.

TABLE 1: Summary of Cases

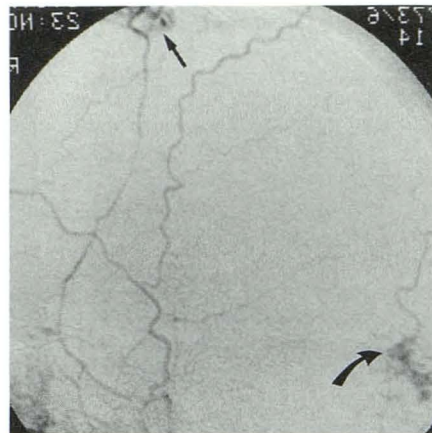
Patient No.	Location of Fistulas	Arterial Supply	Venous Drainage
1	a) R cavernous sinus b) R ethmoidal groove	a) R and L meningohypophyseal trunk b) R and L ophthalmic	a) Superior ophthalmic vein b) Parafalcine vein
2	a) Superior sagittal sinus b) L transverse sinus  c) L sigmoid sinus	a) R and L middle meningeal artery b) L meningohypophyseal trunk, posterior cerebral artery, vertebral artery, ascending pharyngeal artery, posterior auricular artery, occipital artery c) L meningohypophyseal trunk, posterior cerebral artery, vertebral artery, ascending pharyngeal artery, posterior auricular artery, occipital artery	a) Cortical vein b) Straight sinus  c) Sigmoid sinus, superior petrosal sinus
3	a) C1–C2 b) C6–C7	a) R vertebral artery, ascending pharyngeal artery b) R costocervical artery	a) Medullary veins b) Medullary veins
4	a) R transverse sinus b) L transverse sinus	a) R and L occipital artery, R middle meningeal artery b) L middle meningeal artery	a) Cortical veins b) Transverse sinus
5	a) L ethmoidal groove b) Posterior fossa	a) L ophthalmic b) L external carotid	a) Cortical veins b) Dural vein
6	a) R cavernous sinus b) R sphenoparietal sinus	a) R accessory meningeal b) R middle meningeal artery, R deep temporal	a) Superior ophthalmic vein b) Jugular vein
7	a) L cavernous sinus b) L inferior petrosal sinus	a) R and L capsular artery b) L middle meningeal artery, L STA, ascending pharyngeal artery	a) Superior ophthalmic vein b) Jugular vein

Note.—a), b), c) entries represent separate fistulas, R = right, L = left, STA = superficial temporal artery.

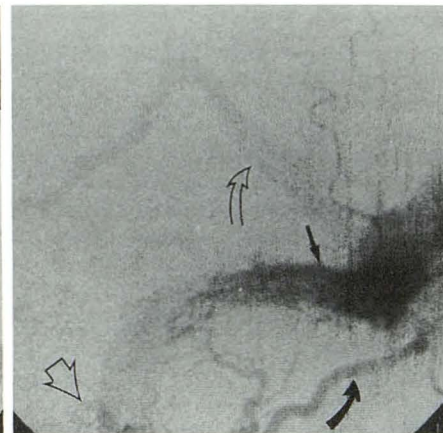




**Fig. 1.**—Patient 1. Right internal carotid artery injection, lateral projection, shows dural arteriovenous fistula (straight arrow) of the cavernous sinus and a second fistula at ethmoidal groove (curved arrow) supplied by ethmoidal branches of ophthalmic artery. The cavernous sinus fistula was treated by embolization through the wall of the cavernous sinus with wire.



A



B

**Fig. 2.**—Patient 2.

**A,** Right external carotid artery injection, lateral projection, shows dural arteriovenous fistula of the superior sagittal sinus (straight arrow) and a second fistula involving left transverse sinus (curved arrow).

**B,** Left external carotid artery injection, lateral projection, shows fistula in left transverse sinus (straight arrow) supplied by occipital artery (closed curved arrow) with venous drainage retrograde into straight sinus (open curved arrow). A second fistula lies within sigmoid sinus (open arrowhead).

#### Case 2

This 27-year-old woman presented with an intracerebral hemorrhage. Angiographic evaluation demonstrated three separate dural fistulas, one involving the superior sagittal sinus, one in the left transverse sinus, and a third in the distal left sigmoid sinus (Fig. 2). Venous drainage from each fistula was into the adjacent sinus, although the superior sagittal sinus fistula also drained to a cortical vein and was the most likely source for the hemorrhage. The fistulas were treated by coagulating or embolizing the fistulas intraoperatively. Postoperative angiography showed that the fistulas were obliterated, and the patient has done well for 2 years.

#### Case 3

This 69-year-old woman presented with arm and leg myelopathy. Angiography demonstrated a spinal radiculomedullary arteriovenous fistula at C1–C2, supplied by the right vertebral and ascending pharyngeal arteries. The lesion was coagulated. Follow-up angiography demonstrated a second fistula at C6–C7, supplied by the right

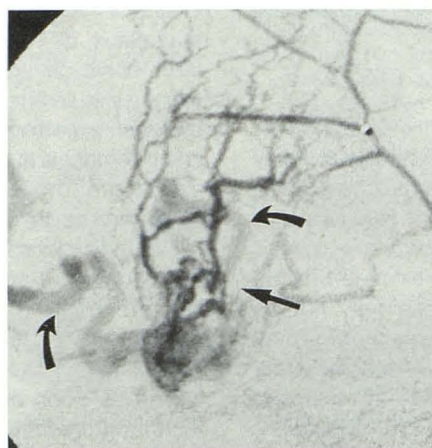
costocervical artery. This lesion was also coagulated and closed. The patient died 4 months later, her condition never having improved.

#### Case 4

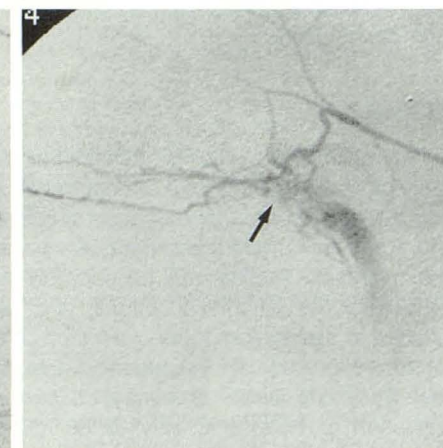
This 49-year-old man presented with a 20-year history of headaches and, more recently, a loud bruit. Angiography demonstrated fistulas in the right and left transverse sinuses (Figs. 3A and 3B). The right-sided lesion was large and had cortical venous drainage. This fistula was treated by transarterial and intraoperative embolization. The fistula in the left transverse sinus was occluded by transarterial embolization. Postoperative angiography demonstrated that both lesions were closed. The patient has done well in follow-up for 2 years with no bruit.

#### Case 5

This 49-year-old man presented with a frontal lobe hemorrhage from a dural fistula of the left ethmoidal groove (Fig. 4A). The



A



B

**Fig. 3.**—Patient 4.

**A,** Right middle meningeal artery injection, lateral projection (posterior on left), shows dural arteriovenous fistula (straight arrow) involving right transverse sinus. Venous drainage is to cortical, collateral veins (curved arrows).

**B,** Left middle meningeal artery injection, right anterior oblique projection, shows second fistula in left transverse sinus (arrow).



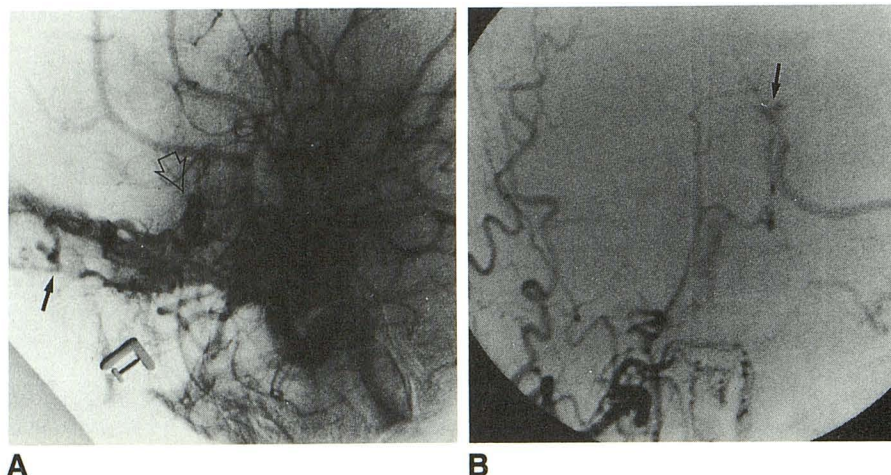


Fig. 4.—Patient 5.

A, Left internal carotid artery injection, lateral projection, shows ethmoidal groove dural arteriovenous fistula (closed arrow). The venous drainage is through a cortical vein that has an associated pseudoaneurysm (open arrowhead).

B, Right external carotid artery injection, Towne's projection, shows a second fistula (arrow) in posterior fossa, supplied by a branch of the external carotid artery.

hematoma was removed and the fistula coagulated. Postoperative angiography showed no residual ethmoidal groove fistula, but a second fistula was found in the posterior fossa (Fig. 4B). This asymptomatic fistula has not been treated.

#### Case 6

This 74-year-old man presented with diplopia and decreasing vision caused by a right cavernous sinus fistula, supplied by the right accessory meningeal artery and draining to the superior ophthalmic vein (Fig. 5). There was a second, asymptomatic fistula in the right sphenoparietal sinus, supplied by the middle meningeal and deep temporal arteries and draining into the jugular bulb. The cavernous sinus fistula was closed by embolization. The vision of the patient has improved although the diplopia persists after 10 months. The asymptomatic lesion was not treated.

#### Case 7

This 72-year-old woman presented with decreased vision and diplopia from a left cavernous sinus fistula, supplied by the capsular artery from the cavernous internal carotid artery and draining to the superior ophthalmic vein (Figs. 6A and 6B). A second fistula, supplied by the middle meningeal and ascending pharyngeal arteries and draining to the jugular bulb, was present in the left inferior petrosal sinus. Embolization of the cavernous sinus fistula successfully closed the lesion and improved vision, although the diplopia has remained for 10 months. The inferior petrosal sinus fistula was asymptomatic and was not treated.

#### Discussion

The occurrence of multiple fistulas has been reported only rarely [5, 6, 8]. The low rate of occurrence of multiple DAVFs may reflect in part a general assumption that fistulas occur singly, and little thought is given to the possibility of a second lesion. Second fistulas may be supplied by arteries that do not supply the recognized fistula, and hence may not be included in the angiographic evaluation. Alternatively, it may not be recognized that the second fistula is a separate entity from the initial DAVF and may be excluded from further evaluation or treatment, only to be found on subsequent angiograms.

Presenting symptoms caused by DAVFs range from very mild symptoms that require no therapy to those that produce major neurologic deficits or fatal hemorrhage [9–11]. The angiographic appearance of DAVFs also varies widely from lesions with relatively low velocity arterial inflow and no restriction of venous outflow to lesions with high flow and major sinus occlusive disease with collateral cortical drainage. The latter angiographic pattern of venous occlusive disease and collateral cortical venous drainage is associated with a higher risk of hemorrhage [3, 6, 12–18].

The clinical presentation and angiographic findings in our patients suggest that multiple lesions have a higher risk of hemorrhage than most single DAVFs. All presented with catastrophic hemorrhage or neurologic deficits, or had angiographic patterns that put them at high risk for hemorrhage, including venous ectasias, cortical venous drainage, and stenotic veins. These risk factors are the result of advanced venous occlusive disease.

The pathogenesis of multiple DAVFs is not yet known. Because it is well established that DAVFs can occur secondary to thrombosis, a hypercoagulable state may lead to thrombosis at several sites. Such an origin may be established by the results of laboratory tests, such as those for protein S, protein C, and antithrombin 3 deficiency, hyperviscosity syndromes, and elevated platelet count. In addition, once a fistula is established in a dural structure, the venous drainage into that sinus is impaired, which may cause stagnation and thrombosis distal from the original fistula and produce a second fistula site. In patient 7, the elevated pressure from the inferior petrosal sinus fistula may have promoted stasis and thrombosis in the cavernous sinus, or vice versa. A similar elevation of pressure may be important in the development of bilateral cavernous sinus DAVFs.

The indications for treatment of second, incidentally identified DAVFs are not well defined. If there are risk factors for hemorrhage such as collateral cortical venous drainage, disabling bruits or headaches, or neurologic deficits related to the fistula, our experience suggests that the fistula should be closed as soon as possible [19–21]. If none of these risk factors is present, however, treatment may be elective, depending on the ease of treatment.



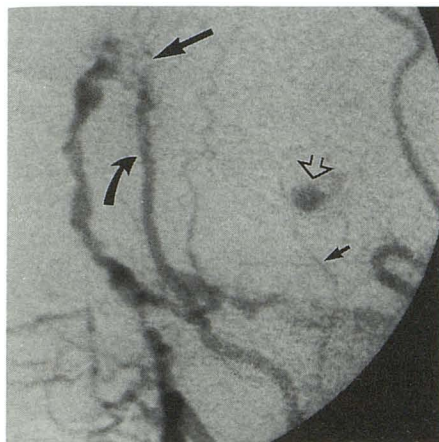
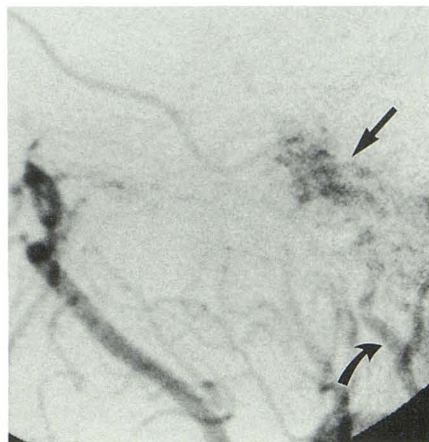
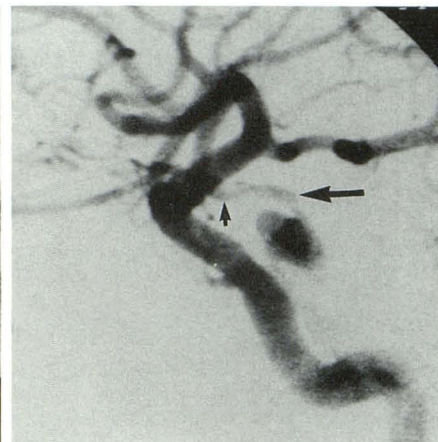


Fig. 5.—Patient 6. Right external carotid artery injection, lateral projection, shows two fistulas, one involving the sphenoparietal sinus (large straight arrow), supplied by the middle meningeal artery (curved arrow), and the other within the cavernous sinus (open arrowhead), supplied by both the accessory meningeal artery (small straight arrow) and the meningohypophyseal trunk of the internal carotid artery (not shown).



A



B

Fig. 6.—Patient 7. A, Left external carotid artery injection, lateral projection, shows dural arteriovenous fistula (straight arrow) of inferior petrosal sinus supplied by ascending pharyngeal artery (curved arrow). B, Left internal carotid artery injection, lateral projection, shows cavernous sinus dural arteriovenous fistula (large arrow), supplied by the capsular artery (small arrow).

There may be some concern that low-risk fistulas may progress; to our knowledge, no studies have been published on this possibility. It is known, however, that some DAVFs have regressed spontaneously [5, 22–24]. However, those fistulas in our series that were asymptomatic and without suspected risk factors for hemorrhage were not treated. Angiography was performed in all patients after surgical or endovascular therapy. In all cases, the treated fistula was closed. Additional angiographic evaluation was performed only if the bruit recurred.

In our series of 105 patients, multiple DAVFs occurred in 7%. The rate of occurrence of multiple lesions indicates the need to study all the intracranial vessels while evaluating DAVFs.

## REFERENCES

- Newton TH, Cronqvist S. Involvement of the dural arteries in intracranial arteriovenous malformations. *Radiology* 1969;93:1071–1078
- Chaudhary MY, Sachdev VP, Cho SH, Weitzner I, Puljic S, Huang YP. Dural arteriovenous malformation of the major venous sinuses: an acquired lesion. *AJNR* 1982;3:13–19
- Graeb DA, Dolman CL. Radiological and pathological aspects of dural arteriovenous fistulas. *J Neurosurg* 1986;64:962–967
- Houser OW, Campbell JK, Campbell RJ, Sundt TM. Arteriovenous malformations affecting the transverse dural venous sinus: an acquired lesion. *Mayo Clin Proc* 1979;54:651–661
- Kataoka K, Taneda M. Angiographic disappearance of multiple dural arteriovenous malformations. *J Neurosurg* 1984;60:1275–1278
- Sakaki S, Fujita H, Kohno K, Matsuoka K. Dural arteriovenous malformation in the posterior fossa associated with intracerebellar hematoma. *J Neurosurg* 1984;60:1067–1069
- Newton TH, Hoyt WF. Dural arteriovenous shunts in the region of the cavernous sinus. *Neuroradiology* 1970;1:71–81
- Tamaki N, Fujita K, Yamashita H. Multiple arteriovenous malformations involving the scalp, dura, retina, cerebrum, and posterior fossa. Case report. *J Neurosurg* 1971;34:95–98
- Lasjunias P, Chiu M, Terbrugge K, Tolia A, Hurth M, Bernstein M. Neurological manifestations of intracranial dural arteriovenous malformations. *J Neurosurg* 1986;64:724–730
- Magidson MA, Weinberg PE. Spontaneous closure of a dural arteriovenous malformation. *Surg Neurol* 1976;6:107–110
- Vinuela F, Fox AJ, Pelz DM, Drake CG. Unusual clinical manifestations of dural arteriovenous malformations. *J Neurosurg* 1986;64:554–558
- Fardoun F, Adam Y, Mercier P, Guy G. Tentorial arteriovenous malformation presenting as an intracerebral hematoma. *J Neurosurg* 1981;55:976–978
- Grisoli F, Vincentelli F, Fuchs S, et al. Surgical treatment of tentorial arteriovenous malformations draining into the subarachnoid space. Report of four cases. *J Neurosurg* 1984;60:1059–1066
- Houser OW, Baker HL, Rhoton AL, Okazaki H. Intracranial dural arteriovenous malformations. *Radiology* 1972;105:55–64
- Ishii K, Goto K, Ihara K, et al. High-risk dural arteriovenous fistulae of the transverse and sigmoid sinuses. *AJNR* 1987;8:113–120
- Kuhner A, Krastel A, Stoll W. Arteriovenous malformations of the transverse dural sinus. *J Neurosurg* 1976;45:12–19
- Malik GM, Pearce JE, Ausman JI, Mehta B. Dural arteriovenous malformations and intracranial hemorrhage. *Neurosurgery* 1984;15:332–338
- Willinsky R, Lasjunias P, Terbrugge K, Pruvost P. Brain arteriovenous malformations: analysis of the angio-architecture in relationship to hemorrhage (based on 152 patients explored and/or treated at the Hospital de Bicetre between 1981 and 1986). *J Neurosurg* 1988;15:225–237
- Halbach VV, Hieshima GB, Higashida RT, Reicher M. Carotid cavernous fistulae: indications for urgent treatment. *AJNR* 1987;8:627–633
- Halbach VV, Higashida RT, Hieshima GB, Goto K, Norman D, Newton TH. Dural fistulas involving the transverse and sigmoid sinuses: results of treatment in 28 patients. *Radiology* 1987;163:443–447
- Halbach VV, Higashida RT, Hieshima GB, Rosenblum M, Cahan L. Treatment of dural arteriovenous malformations involving the superior sagittal sinus. *AJNR* 1988;9:337–343
- Bitoh S, Sakaki S. Spontaneous cure of dural arteriovenous malformation in the posterior fossa. *Surg Neurol* 1979;12:111–114
- Endo S, Koshu K, Suzuki J. Spontaneous regression of posterior fossa dural arteriovenous malformation. *J Neurosurg* 1979;51:715–717
- Hansen JH, Sogaard I. Spontaneous regression of an extra- and intracranial arteriovenous malformation. Case report. *J Neurosurg* 1976;45:338–341