

Are your **MRI contrast agents** cost-effective?

Learn more about generic **Gadolinium-Based Contrast Agents**.



FRESENIUS
KABI

caring for life

AJNR

Three-dimensional fast low-angle shot imaging and computerized volume measurement of the hippocampus in patients with chronic epilepsy of the temporal lobe.

M Ashtari, W B Barr, N Schaul and B Bogerts

This information is current as of April 19, 2024.

AJNR Am J Neuroradiol 1991, 12 (5) 941-947
<http://www.ajnr.org/content/12/5/941>

Three-Dimensional Fast Low-Angle Shot Imaging and Computerized Volume Measurement of the Hippocampus in Patients with Chronic Epilepsy of the Temporal Lobe

Manzar Ashtari¹
William B. Barr^{2,3}
Neil Schaul²
Bernhard Bogerts^{3,4}

This study investigated the use of three-dimensional fast low-angle shot (FLASH) imaging and computer-assisted morphometry for identifying hippocampal changes associated with unilateral temporal lobe seizures. Contiguous 3.1-mm coronal FLASH images were obtained in 28 patients with electroencephalographically verified left ($n = 17$) or right ($n = 11$) temporal lobe seizures and 28 age- and sex-matched control subjects. Hippocampal volumes were calculated with the use of a computerized mensuration system developed for detailed morphometric assessment. The results of a multivariate analysis of variance revealed a significant group difference by hemisphere interaction ($F = 26.3$, $p < .001$). Significant reductions in left hippocampal volume (32%, $p < .001$) were exhibited in patients with left temporal lobe seizures, and significant reductions in right hippocampal volume (35%, $p < .001$) were seen in patients with right temporal lobe seizures. A discriminant analysis with the use of left and right hippocampal volumes classified patients with left temporal lobe seizures with 94% sensitivity and 73% specificity and patients with right temporal lobe seizures with 89% sensitivity and 94% specificity.

The results of this study demonstrate that unilateral temporal lobe seizures are accompanied by significant reductions in hippocampal volume ipsilateral to the seizure focus. The use of FLASH imaging and computer-assisted morphometry of the hippocampus appears to provide valuable structural information for confirming the laterality of the electroencephalographic seizure focus.

AJNR 12:941-947, September/October 1991

Epilepsy surgery has become an increasingly available option for treatment of intractable temporal lobe seizures. Assessment of surgical candidates typically involves hospital admission for long-term electroencephalographic (EEG) monitoring with surface or depth electrodes, neuropsychological testing, and various structural (e.g., CT, MR) and functional (e.g., positron emission tomography, single-photon emission tomography) brain imaging procedures. Decisions to perform a temporal lobectomy are made when the information obtained from these diagnostic procedures converges in support of an epileptogenic focus in either the left or right temporal lobe. The goal of the present study was to investigate the use of a method of obtaining structural correlates of the epileptogenic focus with MR imaging and computer-assisted morphometry.

Temporal lobe seizures may result from many types of disease, including tumors, vascular malformations, and developmental abnormalities such as heterotopias or dysplasias [1]. Results from postmortem and postsurgical studies have indicated that the most common abnormality is hippocampal sclerosis, which is found as the sole abnormality in approximately 65% of epilepsy patients who undergo temporal lobectomy [1]. Hippocampal sclerosis is characterized by a unique pattern of neuronal loss and gliosis that can be observed microscopically in the fascia dentata, hippocampus, and prosubiculum [1]. This disease also may be observed macroscopically as a gross reduction in hippocampal volume [2].

Received January 2, 1991; returned for revision February 11, 1991; final revision received April 4, 1991; accepted April 5, 1991.

Presented in part at the annual meeting of the Association of University Radiologists, Seattle, WA, May 1989.

This work was supported by the Mental Health Clinical Research Center of Hillside Hospital, Long Island Jewish Medical Center, MH-41960. This study was performed in association with The Brain Morphometry and Image Analysis Center supported by a grant from the Helen and Irving Schneider Family.

¹ Department of Radiology, Long Island Jewish Medical Center, Long Island Campus for the Albert Einstein College of Medicine, New Hyde Park, NY 10042. Address reprint requests to M. Ashtari.

² Department of Neurology, Long Island Jewish Medical Center, Long Island Campus for the Albert Einstein College of Medicine, New Hyde Park, NY 10042.

³ Department of Psychiatry, Hillside Hospital, Long Island Jewish Medical Center, Long Island Campus for the Albert Einstein College of Medicine, New Hyde Park, NY 10042.

⁴ Present address: Department of Psychiatry, University of Düsseldorf, P.O. Box 120510, W-4000 Düsseldorf, Germany.

Previous neuroradiologic techniques such as CT scanning have been used successfully for detection of gross structural disease associated with seizures (e.g., tumors), but have been less sensitive for detecting more subtle forms of disease such as hippocampal sclerosis [3]. Neuroradiologic detection of hippocampal sclerosis has improved more recently with the development of MR imaging. Most attention has been placed on observations of increased signal intensities on T2-weighted images. The rate of detecting these abnormalities in reported studies has ranged from 0% to 61% [4, 5]. Other investigators have reported reductions of the size of the hippocampus and temporal lobes on standard T1-weighted images [6, 7], although these findings have been given relatively less attention.

The recent development of three-dimensional (3-D) gradient-echo fast low-angle shot (FLASH) sequences has provided a method for obtaining thin contiguous slices with enhanced neuroanatomic detail [8]. Standard two-dimensional spin-echo (SE) sequences collect distinct signals from individual slices during TE/TR intervals. The 3-D FLASH sequence obtains a single MR signal from the entire volume of the object situated in the imaging fields, thus producing images with a higher signal-to-noise (S/N) ratio. A study by Hendrick et al. [9] showed that optimized FLASH imaging yields a 20–50% improvement in S/N per unit time over optimized SE imaging. The same study also demonstrated that FLASH sequences deliver about 1.2 to 2.7 times the contrast-to-noise ratio per unit time in comparison with SE imaging. However, one of the major disadvantages of the FLASH sequence is that it is vulnerable to magnetic field inhomogeneity and susceptibility.

FLASH sequences, in combination with computer-assisted morphometry, have been shown to provide accurate anatomic measures of various brain structures in clinical and normal control groups [10, 11]. Computerized morphometry has also been used with SE sequences in patients with seizures to assess asymmetries in the anterior temporal lobe and hippocampal volumes [12]. In the current study, we used the FLASH sequence in conjunction with a computerized mensuration system to obtain left and right hippocampal volumes in patients with unilateral temporal lobe seizures and in a matched sample of control subjects.

Subjects and Methods

Subjects

MR scans from a sample of 34 patients with focal temporal lobe seizures were obtained from a consecutive series of 65 patients undergoing inpatient evaluations for intractable epilepsy. Evidence of

temporal lobe seizures was seen on EEG and video recordings in all patients during 1 week of continuous intensive monitoring with surface and sphenoidal electrodes. Scans from six patients with space-occupying lesions on images from standard MR clinical sequences were excluded from further analysis.

The patient sample consisted of 28 patients (15 men and 13 women) with a mean age of 31.2 years (range, 16–52). In all patients, ictal and interictal EEG evidence showed that the seizures originated from one temporal lobe (17 left temporal, 11 right temporal). Histories of early risk factors, defined as events such as febrile convulsions occurring before the age of 5 years, were present in 18 (64%) of 28 patients. A total of 19 patients (68%) had temporal lobectomies (13 left, six right) since having MR imaging for this study.

A sample of 28 normal volunteers served as a control group. These individuals were selected with pairwise-matching techniques according to the age and sex of each patient. The characteristics of the patient and control subjects, including height and seizure variables, are presented in Table 1. No group differences were observed in demographic variables or in height among the three groups or in seizure variables between the two patient groups.

Image Acquisition

MR images of the brain were acquired on a 1.0-T whole-body MR system (Magnetom, Siemens, Erlangen, Germany). The imaging protocol included a series of standard SE sequences in the axial and coronal orientations for clinical evaluation of neuropathologic abnormalities. Additional coronal slices were collected by using a FLASH sequence, 40/15/1 (TR/TE/excitations), with a matrix size of 256 × 256 and 50° flip angle. This sequence provided 63 contiguous slices through the whole head with a resolution of 1.0 × 1.0 × 3.1 mm in 11 min. All images were transferred from a VAX 11/750 to a Sun 3-160 workstation (Sun Microsystems, Mountainview, CA) via magnetic tapes for morphometric analysis following image acquisition.

Computerized Mensuration System

The morphometric measurements were performed with a menu-driven semiautomated computer mensuration system (Ektron Applied Imaging, Burlington, MA). The algorithmic philosophy of this program has been described elsewhere [13]. The program is written in C language and runs on the family of Sun workstations.

The system's *manual* function was used to delineate the hippocampus. The *auto* function could not be used as a result of the complexity of the structure, poor edge definition from aspects of the surrounding brain tissue, and the nonuniform signal intensities involved. For measurement of the hippocampus, the operator traces the outline of the structure with a mouse by depositing points along the border separating the hippocampus from surrounding tissue. The computer then corrects for partial occupancy of in-plane edge pixels and calculates the outlined area of the structure by using Stoke's theorem

TABLE 1: Three-Dimensional Fast Low-Angle Shot Imaging in Chronic Temporal Lobe Epilepsy: Characteristics of Patients and Control Subjects

Group	No. of Subjects	Male/Female Ratio	Mean Age (yr)	Mean Height (cm)	Mean Duration of Chronic Seizures (yr)	Mean No. of Seizures/ Month
Seizure focus in left temporal lobe	17	10/7	31.8	172.5	18.4	6.8
Seizure focus in right temporal lobe	11	5/6	30.3	168.1	16.6	7.6
Normal control	28	15/13	31.5	172.8	—	—

as opposed to pixel counts. The slice volume is then calculated by multiplying the area by the slice thickness (3.1 mm), and the total hippocampal volume is calculated by summing contiguous slices. The hippocampus was always measured by the same rater to ensure consistent delineation of the structure for this study. All measurements were performed under blind conditions and cases were ordered randomly.

Criteria for Anatomic Delineation

Anatomic guidelines for structure delineation were established by using serial 20- μ m Nissl- and myelin-stained coronal sections of whole brain provided by the Histological Laboratory of the Department of Psychiatry, University of Düsseldorf. Delineation of the hippocampal formation included both the dentate gyrus and the subiculum. The border between the subiculum and the parahippocampal gyrus was defined as the most medial extent of the junction of subiculum and parahippocampal gyrus.

The portion of hippocampal tissue situated posteriorly to the thalamus was difficult to visualize on most MR sections. Therefore, all hippocampal measurements began at the same posterior landmark, defined as the level where the ascending fornix (crura) was interrupted by coronal sections. This is the level where the pulvinar was clearly visualized. In many brains, it was also difficult to separate the most anterior parts of the hippocampal formation (pes hippocampi) from the posterior extension of the amygdala. Therefore, the mamillary body was used as an anatomic landmark to separate the majority of the hippocampus from the amygdala. The anterior border for all hippocampal measurements was defined as the slice caudad to the mamillary body. The anterior and posterior landmarks used in this study are illustrated in sagittal orientation in Figure 1. The measurement of the hippocampus included approximately 80% of the total hippocampal formation.

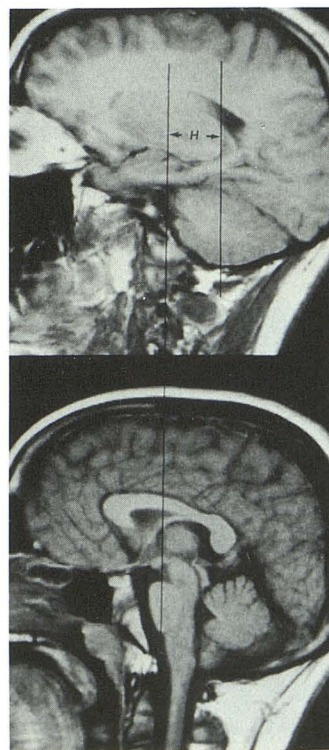


Fig. 1.—Longitudinal (antero-posterior) landmarks of hippocampal (H) measures shown in sagittal orientation. Anterior landmark (left line) consists of slice posterior to mamillary body. Posterior landmark (right line) consists of slice where pulvinar (posterior portion of thalamus) can be seen. These landmarks include approximately 80% of hippocampal formation when measured on coronal sections.

Results

Validity and Reliability of Hippocampal Volume Measurements

The validity and reliability of the computer mensuration system is described elsewhere [13]. To test the validity of the hippocampal volume measures used in this study, the volumes calculated from MR scans of the normal control sample were compared with volumes measured in histologic serial sections of 10 normal control brains from a postmortem brain collection at the University of Düsseldorf. Further description of the postmortem sample is provided by Bogerts et al. [14]. The postmortem measures were obtained from available specimens of the 10 people who died at the youngest ages. This sample consisted of five men and five women who died at a mean age of 41.7 years (range, 33–52 years). The same delineation criteria were used to measure the hippocampus in both the MR and postmortem samples. The postmortem volumes were corrected by a mean shrinkage factor of 1.96 [14]. The results of direct comparisons between the samples revealed that the average difference between the MR volumes ($n = 28$) and postmortem volumes ($n = 10$) was 2.5% (see Table 2).

For assessment of the reliability of the volume measurements, 15 MR scans were measured by a second operator (for interrater reliability) and, after 3 weeks, again by the first operator (for test-retest reliability). Intraclass correlation coefficients for interrater and test-retest reliabilities of both left and right hippocampal volumes ranged from .85 to .98 [11].

Group Differences in Hippocampal Volume

Mean hippocampal volumes for men and women from the MR and postmortem samples are provided in Table 2. Differences between patient groups (left temporal vs right temporal vs MR controls), differences between hippocampal volumes (left hippocampus vs right hippocampus), and differences between men and women were tested with a multivariate analysis of variance (MANOVA). The MANOVA offers the advantage of analyzing all effects simultaneously while reduc-

TABLE 2: Mean Hippocampal Volume Measurements Listed by Sex for Postmortem and MR Control Subjects and Patients with Left and Right Temporal Lobe Seizures

Group/Sex	Mean Volume in mm ³ (Range)	
	Left	Right
Postmortem control		
Male ($n = 5$)	2760.4 (2085–3745)	2939.8 (2085–4061)
Female ($n = 5$)	2673.8 (2288–3238)	2507.4 (1290–3455)
MR control		
Male ($n = 15$)	2727.7 (2110–3705)	2598.5 (2152–3279)
Female ($n = 13$)	2676.1 (1710–3426)	2642.9 (1920–3316)
Left temporal seizure focus		
Male ($n = 10$)	2093.1 (1163–2694)	2596.5 (2374–2943)
Female ($n = 7$)	1587.1 (1281–2279)	2207.1 (1734–3331)
Right temporal seizure focus		
Male ($n = 5$)	2102.8 (1514–2842)	1576.6 (996–2250)
Female ($n = 6$)	2193.0 (1522–2466)	1747.5 (1005–2435)

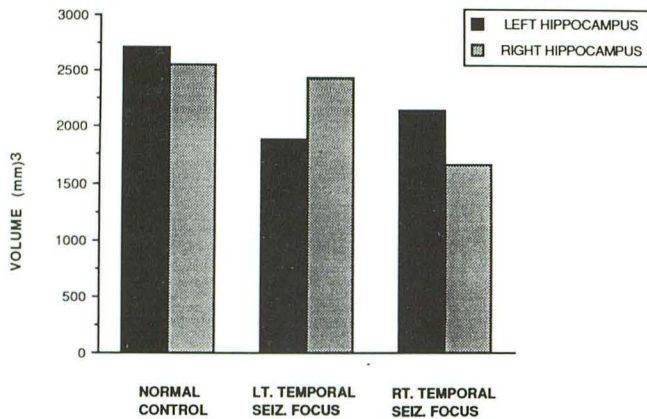


Fig. 2.—Mean left and right hippocampal MR volumes for normal controls ($n = 28$), patients with left (LT.) temporal lobe seizures (SEIZ.) ($n = 17$), and patients with right (RT.) temporal lobe seizures ($n = 11$).

ing the probability of obtaining chance results from conducting multiple separate analyses (i.e., type I experimental error).

The results of the MANOVA revealed significant group differences ($F = 21.01, p < .001$) and a significant two-way interaction between group and differences in right and left hippocampal volumes ($F = 26.3, p < .001$). Overall differences between men and women were not significant, although there was a trend for an interaction between sex and group ($F = 2.6, p < .09$). The three-way interaction between group, sex, and differences between left and right hippocampal volume was not significant.

In order to determine whether there were potential effects introduced by any systematic group differences in body or brain size, the same analyses were conducted by covarying subject height. The results of all analyses were essentially the same. In fact, the interaction effect of greatest interest (group by hemisphere) was enhanced ($F = 36.2, p < .001$).

A graphic representation of the mean left and right hippocampal volumes for the patient groups and controls is presented in Figure 2. For clarification of the group effects

observed in the MANOVA results, posthoc *t* tests were conducted to examine specific differences. Comparisons between patients and controls revealed significant left hippocampal reductions in patients with left temporal lobe seizures (left: $t = 5.15, p < .001$; right: $t = 0.65$, not significant). This difference amounted to a 32% reduction in the left hippocampus, while only a 4% reduction was observed in the right hippocampus. Significantly reduced left and right hippocampal volumes were exhibited in patients with right temporal lobe seizures (right: $t = 4.89, p < .001$; left: $t = 2.88, p < .01$). These differences reflected volume reductions of 35% in the right hippocampus and 17% in the left hippocampus. Visual examples of scans from patients and controls are presented in Figure 3.

The results of *t* tests between patient groups (left temporal vs right temporal) revealed significant right hippocampal reductions in patients with right temporal lobe seizures ($t = 4.39, p < .001$). Lower mean left hippocampal volumes were exhibited in patients with left temporal lobe seizures than in patients with right temporal lobe seizures, although these differences were not statistically significant ($t = 1.52$). For clarification of the trend for a two-way interaction between sex and group, the means suggest that women with left temporal lobe seizures and men with right temporal lobe seizures exhibit the greatest degree of hippocampal volume reduction ipsilateral to the seizure focus.

Within-Subject Differences in Hippocampal Volume

The results of paired *t* tests examining within-subject (left hippocampus vs right hippocampus) effects indicated that the left hippocampus in patients with left temporal lobe seizures was significantly smaller than the right hippocampus (22% reduction, $t = 5.81, p < .001$). In patients with right temporal lobe seizures, a smaller right hippocampus was seen in comparison with the left (22% reduction, $t = 3.27, p < .01$). It is interesting that a relatively smaller right hippocampus was also exhibited in the control group ($t = 2.26, p < .05$), although the magnitude of the difference between the right and left was on the order of only a 6% reduction.

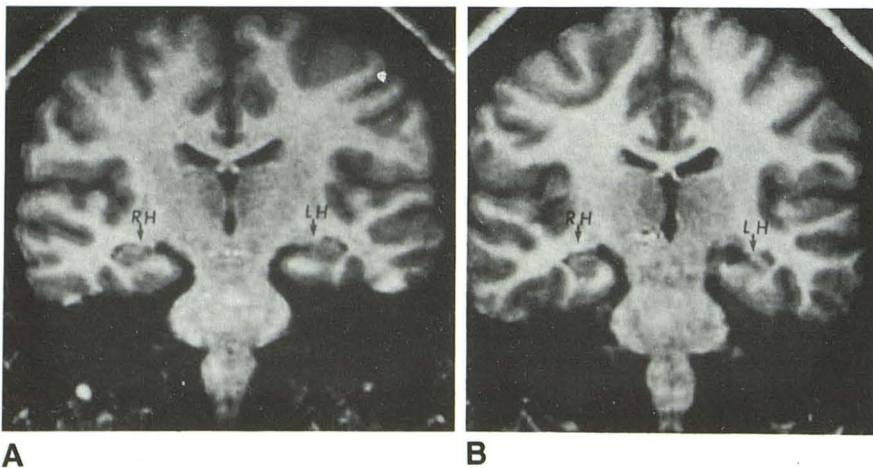


Fig. 3.—A and B, Coronal FLASH images of right (RH) and left (LH) hippocampi in normal control subject (A) and patient with left temporal lobe seizures (B).

Classification of Patients According to Left and Right Hippocampal Volumes

A discriminant analysis is a statistical procedure in which linear combinations of two or more predictor variables are used to classify individual subjects into groups. This analysis was used to examine the rate of classifying patients with left and right temporal lobe seizures into their respective groups with left and right hippocampal volumes as the predictor variables. The results of this analysis were statistically significant (Wilks' lambda = .39, chi-square = 23.7, $p < .001$) and correctly classified 86% of the patients into their respective groups (see Table 3). This analysis provided 94% sensitivity and 73% specificity in classifying patients with left temporal lobe seizures and 89% sensitivity and 94% specificity in classifying patients with right temporal lobe seizures.

Among the four patients who were misclassified by the discriminant analysis, nearly identical right and left hippocampal volumes were seen in two. In one of these patients, postoperative pathology was consistent with a neuronal migration defect in the left temporal lobe; this patient has had no further seizures during the 9 months since left temporal lobectomy. In the other patient, evidence of right frontal schizencephaly was seen in addition to right temporal lobe seizures; surgery has not yet been performed. In two other patients with right temporal lobe seizures, the right hippocampus was larger than the left. A visual inspection of standard sequences revealed that one of these patients had bilateral idiopathic calcifications in the globus pallidus; this patient has had no further seizures during the 2 years following right temporal lobectomy. In the other patient, a noticeably small right temporal lobe was seen on standard MR imaging despite a relatively large right hippocampus; surgery has not yet been performed.

In the total surgical sample, 14 of 19 patients have had no further seizures after a mean postsurgical follow-up of 17.4 months (range, 3–40 months). In the remaining five patients, significant reductions in seizure frequency (less than two seizures/year) have occurred following surgery. All five of these patients were correctly classified by the discriminant analysis.

Discussion

The results of this study show that groups of patients with seizure foci in the left or right temporal lobe exhibit significant reductions in mean hippocampal volume ipsilateral to the

seizure focus. The degree of reduction on the affected side amounted to greater than 30% when compared with age- and sex-matched controls. Reductions in mean left hippocampal volume were observed in both patient groups in comparison with controls, although the degree of reduction was greater in patients with left temporal lobe seizures. Reductions in mean right hippocampal volume were more specific to patients with right temporal lobe seizures. The results of further analyses revealed that these findings were not confounded by group differences in sex or body size. A statistical classification procedure that used left and right hippocampal volumes classified patients with left temporal lobe seizures with 94% sensitivity and 73% specificity and patients with right temporal lobe seizures with 89% sensitivity and 94% specificity.

The results of this study are similar to those reported in a previous investigation obtaining hippocampal volumes with SE sequences and computerized morphometry [12]. In the previous study, differences between left and right hippocampal volumes were used successfully to classify patients and controls with 76% sensitivity and 100% specificity. In the current study, left and right hippocampal volumes were analyzed independently to classify patients with left or right temporal lobe seizures. The methods used in the previous study offer the advantage of increased specificity as to the side of the seizure focus. However, the use of left-right differences appears to be less sensitive than the use of individual left and right hippocampal volumes and may also obscure important findings observed contralateral to the seizure focus.

One of the most important research applications of MR imaging and computerized morphometry in studies of epilepsy is to obtain in vivo measures of both hippocampal regions. Most studies of disease associated with seizures are conducted on specimens obtained from resective surgery. Several histopathologic studies have demonstrated neuronal loss in these resected specimens [1]. However, those findings are restricted to the affected side and leave many questions about the contralateral hippocampus open to speculation. Investigations of postmortem samples have reported a relatively high rate of bilateral hippocampal disease in this population [2, 15, 16], but these findings may be confounded by hippocampal changes resulting from the cause of death (e.g., myocardial infarction, status epilepticus).

This study's analyses of in vivo measures of the left and right hippocampi revealed bilateral changes in some patients. Volume reductions in both hippocampi were observed in the right temporal lobe seizure group, while reductions were limited to the left side in the left temporal lobe seizure group. To our knowledge, the correspondence between bilateral hippocampal abnormalities and left/right EEG results have not been reported in postmortem analyses. Our results may suggest that the left hippocampus is more vulnerable to pathologic influences than the right, regardless of whether seizures originate from the left or right temporal lobe. Our results also suggest that men with right temporal lobe seizures and women with left temporal lobe seizures may be particularly vulnerable to these influences. It is possible that some of these findings may result from features particular to

TABLE 3: Discriminant Analysis of Results of Locating Seizure Foci in Right or Left Temporal Lobe Based on Hippocampal Volumes

Location of Seizure Focus	No. (%)	
	Correct Side Predicted	Incorrect Side Predicted
Left temporal lobe ($n = 17$)	16 (94)	1 (6)
Right temporal lobe ($n = 11$)	8 (73)	3 (27)
Total ($n = 28$)	24 (86)	4 (14)

the right temporal lobe group or from having relatively fewer patients with right temporal lobe seizures in the current sample population.

The reductions in hippocampal volume observed in this study may reflect macroscopic changes attributable to hippocampal sclerosis. The degree of seizure reduction observed in our 1-year postsurgical follow-up suggests an accurate identification of seizure onset in our surgical patients. Methods of hippocampal resection often differ among surgical centers. Some centers conduct en bloc resections that provide intact tissue for pathologic analysis [17]. Others resect the hippocampus by subpial aspiration and thus destroy the tissue [18]. Hippocampal specimens were unavailable for pathologic analysis for the majority of our sample as a result of the use of subpial aspiration at this center. Therefore, one of the major disadvantages of this study is the inability to supplement our findings with pathologic verification of hippocampal sclerosis. However, the consistent reductions in hippocampal volume observed at the site of seizure origin indicate that our measures provide a useful index of structural disease, although their relationship to the neuronal loss observed in hippocampal sclerosis remains only inferential at this time.

The major application of quantitative MR methods in the field of epilepsy will most likely be in clinical evaluations of surgical candidates. Our results confirm previous findings that these methods are sensitive to detecting unilateral structural disease associated with the laterality of the EEG focus [12]. This previous investigation also determined that quantitative measures of the hippocampus are more sensitive to detecting disease than are other types of MR detection methods [12]. The relative lack of specificity of our methods reinforces the position that the results of MR should never provide the sole basis for deciding whether to perform excisional surgery. The results of neuroradiologic investigations are best used in this population as supplementary information for confirming the results of EEG monitoring and other aspects of the clinical evaluation (e.g., neuropsychology, positron emission tomography) [19].

Mensuration techniques for quantifying anatomic detail require neuroimaging methods that enable the acquisition of thin contiguous slices with enhanced gray/white matter contrast. With standard SE sequences, it is often difficult to obtain more than 20 slices at a time with thicknesses less than 4 mm. The most worthwhile attributes of 3-D MR imaging include the ability to obtain thin slices with extensive anatomic coverage. Thin slices maximize the accuracy of volumetric measurements by acquiring more slices to cover the same anatomy and by decreasing partial-volume averaging.

While the FLASH sequence provides images of the whole hippocampal formation, arbitrary judgment is needed to delineate the anterior and posterior boundaries of the structure. We have thus chosen to measure a selected portion of the hippocampus based on fixed anatomic landmarks that can be consistently identified in both patients and controls. Additional error may be introduced by not measuring the volume of the entire structure. However, we believe this error to be less than that which would be obtained by making arbitrary judgments at these boundaries. The results of our validity tests

provide support for the accuracy of the information obtained from the scans and measurements used in this study [11] (Table 2).

The anatomic landmarks used for this study enabled us to obtain volumes of approximately 80% of the total hippocampus. The most anterior and posterior portions of this structure were excluded as a result of the inability to reliably distinguish these regions from surrounding tissue on MR images with a 3.1-mm slice thickness. This was most notable in the anterior portions, where it was extremely difficult to distinguish the hippocampus from the posterior extension of the amygdala. We have also found it difficult to distinguish the anterior hippocampus from the posterior amygdala in FLASH sequences with the 1.6-mm slice thickness routinely used in our other clinical experimental protocols. It is possible that the exclusion of the remaining 20% of the hippocampus in this study may have resulted in a failure to detect important group differences in these anterior regions, but it was necessary to exclude these portions in order to maintain the overall reliability of the measurements.

Although a nonselective RF FLASH sequence is advantageous for imaging the whole head, it will not allow imaging of selective or oblique orientations. Jack et al. [12, 20] have acquired SE sequences with slices orthogonal to the axis of the temporal lobe to accommodate the angulation of the hippocampus and to achieve better visualization of the anterior portion of this structure. The acquisition of these oblique sections apparently improves the ability to distinguish the anterior hippocampus from the amygdala. However, this method does not necessarily improve the accuracy of the hippocampal volume since an arbitrary judgment is still required to distinguish these structures [20].

Careful attention to measurement criteria is necessary when comparing results across studies. For example, the results of our within-group analyses of hippocampal volumes in normal controls revealed significantly smaller mean right-sided volumes. These findings contrast with those reported in a previous study, in which smaller left hippocampal volumes were observed in controls [20]. Since the measurements in the earlier study included a more anterior extension of the hippocampus than the measures used in this study, the discrepancy may be the result of differences in the criteria used to define the hippocampus.

The results of this study were obtained with the use of 3-D FLASH imaging. FLASH imaging is recommended for research settings for numerous reasons not yet outlined in this discussion. Standard SE sequences used with gap or interleaved slices are susceptible to patient movement and interaction between slices. The short acquisition time of the FLASH sequence reduces the possibility of patient movement. Furthermore, the improved slice profile produces more accurate slices with a uniform slice thickness and less interaction between slices. Reformatting of the 3-D images can also yield images in a new orientation, thereby reducing a second or third time-consuming MR scan.

In summary, the results of this study indicate that the combination of 3-D FLASH imaging and computerized mensuration procedures provides a valuable index of hippocampal disease in patients with temporal lobe seizures. These meth-

ods may also provide valuable information for identifying subtle structural abnormalities in other clinical populations.

REFERENCES

- Babb TL, Brown WJ. Pathological findings in epilepsy. In: Engel J, ed. *Surgical treatment of the epilepsies*. New York: Raven, 1987:511-540
- Margerison JH, Corsellis JAN. Epilepsy and the temporal lobes. *Brain* 1966;89:499-530
- Blom RJ, Vinuela F, Fox WT, Blume J, Girvin J, Kaufmann JCE. Computed tomography in temporal lobe epilepsy. *J Comput Assist Tomogr* 1984;8:401-405
- Sperling MR, Wilson G, Engel J Jr, Babb TL, Phelps M, Bradley W. Magnetic resonance imaging in intractable partial epilepsy: correlative studies. *Ann Neurol* 1986;20:57-62
- Kuzniecky R, de la Sayette V, Ethier R, et al. Magnetic resonance imaging in temporal lobe epilepsy: pathological correlations. *Ann Neurol* 1987;22:341-347
- Sostman HD, Spencer DD, Gore JC, et al. Preliminary observations on magnetic resonance imaging in refractory epilepsy. *Magn Reson Imaging* 1984;2:301-306
- McLachan RS, Nicholson RL, Black S, Carr T, Blume WT. Nuclear magnetic resonance imaging, a new approach to the investigation of refractory temporal lobe epilepsy. *Epilepsia* 1985;26:555-562
- Frahm J, Haase A, Matthaei D. Rapid three-dimensional MR imaging using the FLASH technique. *J Comput Assist Tomogr* 1986;10:363-368
- Hendrick ER, Kneeland JB, Stark DD. Maximizing signal-to-noise and contrast-to-noise ratios in FLASH imaging. *Magn Reson Imaging* 1987;5:117-127
- Filipek PA, Kennedy DN, Caviness VS, Rossnick SL, Spraggins TA, Starewicz PM. Magnetic resonance imaging-based brain morphometry: development and application to normal subjects. *Ann Neurol* 1989;25:61-67
- Bogerts B, Ashtari M, Degreef G, Alvir J, Bilder RM, Lieberman JA. Reduced temporal limbic structure volumes on magnetic resonance images in first episode schizophrenia. *Psychiatr Res Neuroimaging* 1990;35:1-13
- Jack CR, Sharbrough FW, Twomey CK, et al. Temporal lobe seizures: lateralization with MR volume measurements of the hippocampal formation. *Radiology* 1990;175:423-429
- Ashtari M, Zito JL, Gold BI, Lieberman JA, Borenstein M, Herman PG. Computerized volume measurement of brain structure. *Invest Radiol* 1990;25:798-805
- Bogerts B, Falkai P, Happts M, et al. Post-mortem volume measurements of limbic system and basal ganglia structures in chronic schizophrenics: initial results from a new brain collection. *Schizophr Res* 1990;3:295-301
- Sano K, Malamud N. Clinical significance of sclerosis of the cornu ammonis. *Arch Neurol Psychiatry* 1953;70:40-53
- Moritzen-Dam A. Hippocampal neuron loss in epilepsy and after experimental seizures. *Acta Neurol Scand* 1982;66:601-642
- Polkey CE. Anterior temporal lobectomy at the Maudsley Hospital, London. In: Engel J, ed. *Surgical treatment of the epilepsies*. New York: Raven, 1987:641-645
- Olivier A. Commentary: cortical resections. In: Engel J, ed. *Surgical treatment of the epilepsies*. New York: Raven, 1987:405-416
- Engel J, Driver MV, Falconer MA. Electrophysiological correlates of pathology and surgical results in temporal lobe epilepsy. *Brain* 1975;98:129-156
- Jack CR, Twomey CK, Zinsmeister AR, Sharbrough FW, Peterson RC, Cascino GD. Anterior temporal lobes and hippocampal formations: normative volumetric measurements from MR images in young adults. *Radiology* 1989;172:549-554

The reader's attention is directed to the commentary on this article, which appears on the following pages.