Are your MRI contrast agents cost-effective?
Learn more about generic Gadolinium-Based Contrast Agents.
FRESENIUS KABI
caring for life

AJNR

Bilateral choroid plexus cysts in the lateral ventricles.

H Nakase, T Morimoto, T Sakaki, Y Takahashi, H Nakagawa and S Iwasaki

AJNR Am J Neuroradiol 1991, 12 (6) 1204-1205
http://www.ajnr.org/content/12/6/1204.citation

This information is current as of April 19, 2024.

Bilateral Choroid Plexus Cysts in the Lateral Ventricles

Small choroid plexus cysts are a common finding at autopsy [1]. They generally are less than 1 cm in diameter and do not cause signs or symptoms of obstruction [2]. We report a case of bilateral choroid plexus cysts in the lateral ventricles detected by MR imaging.

Case Report

A 4-year-old boy had slight retardation of psychomotor development and a history of three febrile convulsions. He had been in good health until a generalized seizure occurred. On the day of admission, he was in status epilepticus, but the seizures were controlled by administration of diazepam and phenobarbital. CT of the brain showed no abnormality. The day after admission, the patient was alert and asymptomatic. Results of a general physical examination and routine laboratory studies were normal. An electroencephalogram showed decreased normal rhythm and slowing in the delta range, with sharp waves in both centroparietal areas. MR showed bilateral round cystic masses, 14 × 12 mm on the right and 11 × 9 mm on the left, in the trigones of the lateral ventricles (Fig. 1). On T1- and T2-weighted images, the cysts had a slightly higher signal than that of CSF, and the walls of the cysts enhanced after the administration of gadopentetate dimeglumine. The cysts were attached to the choroid plexus. Because the patient's seizures were controlled by administration of antiepileptic drugs, he received no surgical treatment and has been observed as an outpatient. No clinical or radiologic changes were observed at a 1-year follow-up examination. Histologic confirmation was not obtained, but a presumptive diagnosis of choroid plexus cyst was made on the basis of the MR findings.

Discussion

Choroid plexus cysts are nonneoplastic cysts lined by cells that are morphologically similar to those of the epithelium in the CNS. They have various names: ependymal cysts, neuroepithelial cysts, choroidal-epithelial cysts, and subarachnoid-ependymal cysts [3].

Several cases of choroid plexus cysts in the lateral ventricles have been reported, along with the MR findings [3–7]. The density of the cysts is similar to that of CSF. The walls of the cysts can be seen clearly on MR but not on CT. In our case, the cysts had a slightly higher signal than that of CSF on T1- and T2-weighted MR images,

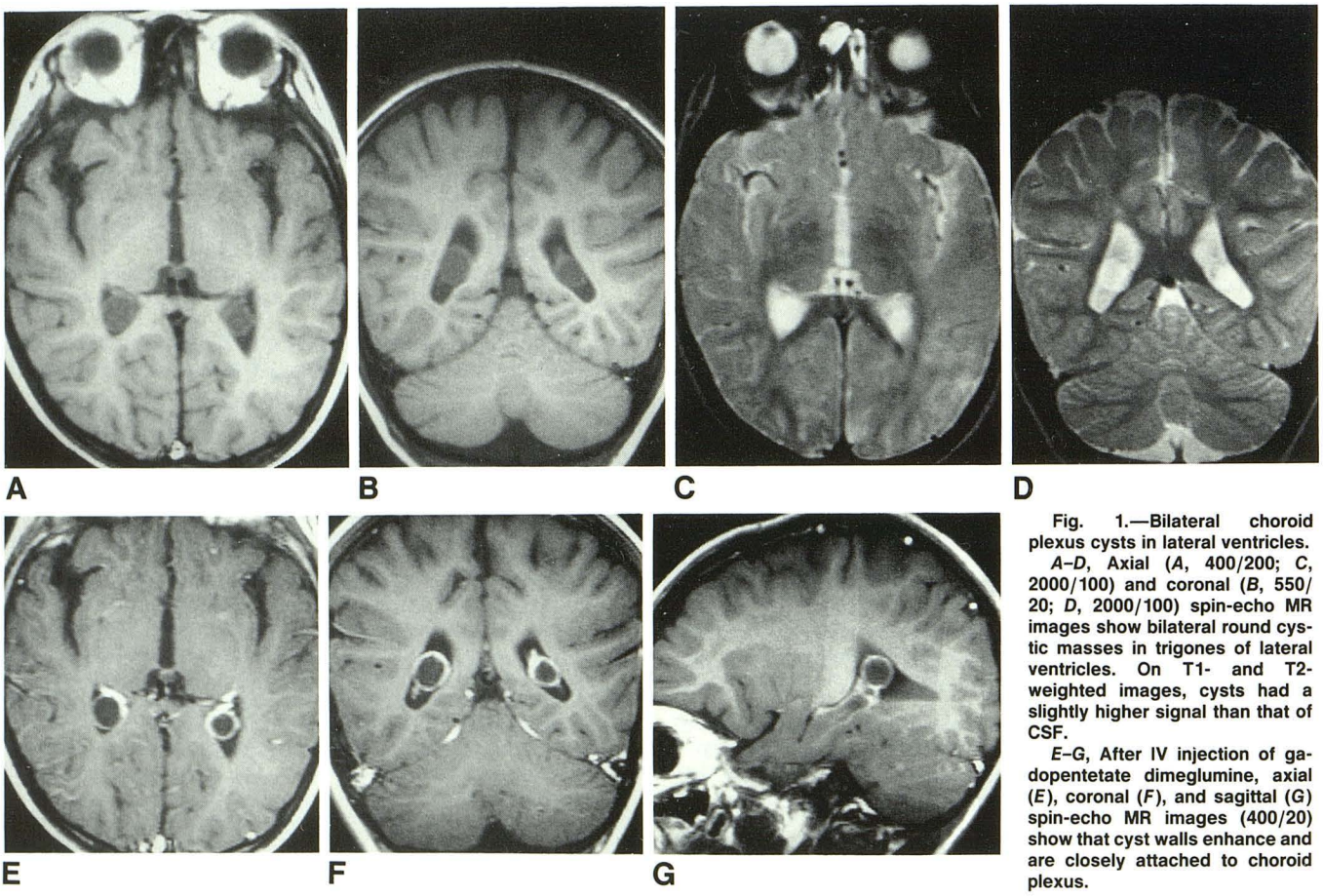

Fig. 1.—Bilateral choroid plexus cysts in lateral ventricles.
***A–D*, Axial (*A*, 400/200; *C*, 2000/100) and coronal (*B*, 550/20; *D*, 2000/100) spin-echo MR images show bilateral round cystic masses in trigones of lateral ventricles. On T1- and T2-weighted images, cysts had a slightly higher signal than that of CSF.**
***E–G*, After IV injection of gadopentetate dimeglumine, axial (*E*), coronal (*F*), and sagittal (*G*) spin-echo MR images (400/20) show that cyst walls enhance and are closely attached to choroid plexus.**

and the walls of the cysts enhanced after the administration of contrast medium. MR showed that the cysts were closely attached to the choroid plexus, indicating their origin from that structure. Most choroid plexus cysts are located in the body and atrial portions of the lateral ventricle, usually on the left side [5]. Schnopfhagen [8] thought that the cysts were the result of cystic degeneration of the choroid plexus associated with aging, but the findings in our case (young age of the patient and bilateral location) suggest that congenital factors may be involved.

The main mechanism of signs and symptoms is obstruction of the CSF pathway. Headache is the most common symptom, and asymptomatic intraventricular choroid plexus cysts in the lateral ventricles are not an indication for surgery [9, 10].

Hiroyuki Nakase
Tetsuya Morimoto
Toshisuke Sakaki
Yukihiro Takahashi
Hiroyuki Nakagawa
Satoru Iwasaki
Nara Medical University
Nara, Japan

REFERENCES

1. Andreussi L, Cama A, Cozzutto C, Gianbartolomei G, Grossi G. Cyst of the choroid plexus of the left lateral ventricle. *Surg Neurol* **1979**;12:53–57
2. Dempysey RJ, Chandler WF. Choroid plexus cyst in the lateral ventricle causing obstructive symptoms in an adult. *Surg Neurol* **1981**;15:116–119
3. Czervionke CF, Daniels DL, Meyer GL, Pojunas KW, Williams AL, Haughton VM. Neuroepithelial cysts of the lateral ventricles: MR appearance. *AJNR* **1987**;8:609–613
4. Numaguchi Y, Kumra A, Schmidt RD, Martino C. Noncolloid neuroepithelial cysts in the lateral ventricle: magnetic resonance features. *J Comput Tomogr* **1988**;12:174–181
5. Numaguchi Y, Foster RW, Gum GK. Large asymptomatic noncolloid neuroepithelial cysts in the lateral ventricle: CT and MR features. *Neuroradiology* **1989**;31:98–101
6. Nakase H, Hisanaga M, Hashimoto S, Imanishi M, Utsumi S. Intraventricular arachnoid cyst: report of two cases. *J Neurosurg* **1988**;68:482–486
7. Yasumoto Y, Tada H, Matsumura K, Ito K, Iizuka Y, Sumie H. Intraventricular arachnoid cyst: a case report. *Prog CT* **1989**;11:598–601
8. Schnopfhagen. Die Sogenannte Cystose Degeneration der Plexus Choroidei Grosshirns. *Wein Akad Sitzungscheriete* **1876**
9. Nakase H. Intraventricular arachnoid cyst (letter). *J Neurosurg* **1989**;70:155
10. Lee KS, Bae HG, Yun IG. Intraventricular arachnoid cyst (letter). *J Neurosurg* **1989**;70:154