Are your MRI contrast agents cost-effective?
Learn more about generic Gadolinium-Based Contrast Agents.
FRESENIUS KABI
caring for life

AJNR

Proton relaxation enhancement associated with iodinated contrast agents in MR imaging of the CNS.

J R Jinkins, J W Robinson, L Sisk, G D Fullerton and R F Williams

This information is current as of April 17, 2024.

AJNR Am J Neuroradiol 1992, 13 (1) 19-27
http://www.ajnr.org/content/13/1/19

Proton Relaxation Enhancement Associated with Iodinated Contrast Agents in MR Imaging of the CNS

J. R. Jinkins,[1] J. W. Robinson,[1] L. Sisk,[1] G. D. Fullerton,[1] and R. F. Williams[1]

Purpose: To study the effects of iodinated radiographic contrast agents on proton relaxation in MR imaging. **Patients and Methods:** Two patients were evaluated after the intrathecal administration of an iodinated nonionic contrast agent (Isovue) and five subjects with cranial tumors following the intravenous administration of an iodinated ionic contrast medium (Renografin). **Results:** Both patients with subarachnoid iodinated contrast media demonstrated a relative reduction in T1 and/or T2 times using a spin-echo sequence, while four of five of the subjects with intracranial tumors (one glioma, one dural metastasis, three meningiomas) and intravenous enhancement revealed a visible MR effect. Confirmation of these in vivo observations was obtained by in vitro measurement of T1 and T2 while varying the concentration of the contrast media in saline. All iodinated contrast media showed progressively reduced relaxation times (T1 and T2) as the concentration of the agent was increased. The largest contributing relaxation mechanism is probably due to the binding and exchange of the surrounding water with the contrast molecules. **Conclusion:** The observed T1/T2 effects suggest that administration of iodinated contrast media in the period immediately prior to MR scanning may be contraindicated in selected cases due to the demonstrated alteration of MR signal intensity that may lead to diagnostic inaccuracies.

Index terms: Contrast media, paramagnetic; Contrast media, effects; Magnetic resonance, contrast enhancement; Magnetic resonance, technique

AJNR 13:19–27, January/February 1992

With the increasing interest in conventional radiologic and computed imaging methods and their relationship to one another in patient evaluation, the possible adverse effect of one examination upon the other sometimes comes into question. This is particularly true in regard to the need for timely patient diagnosis and treatment during a period of rapidly escalating cost of medical care. A study was initiated to evaluate possible perturbation in magnetic resonance (MR) images by iodinated x-ray contrast agents commonly used in clinical imaging of the central nervous system.

Received August 9, 1990; revision requested October 26, 1990; revision received August 27, 1991; final acceptance August 28, 1991.

Presented at the Annual Meeting of the ASNR, Los Angeles, CA, March 19–23, 1990.

[1] All authors: Department of Radiology, The University of Texas Health Science Center at San Antonio, 7703 F. Curl Drive, San Antonio, TX 78284-7800. Address reprint requests to J. R. Jinkins.

AJNR 13:19–27, Jan/Feb 1992 0195-6108/92/1301-0019
© American Society of Neuroradiology

Materials and Methods

In Vivo Imaging Studies

All clinical studies were performed with a 1.5 T General Electric Signa (Milwaukee, WI) clinical unit utilizing spin-echo acquisitions with T1 (500/15/2: TR/TE/NEX) and/or T2 (2500/30-80/1) weighting. Each examination was acquired within 2 hours of iodinated contrast media administration.

One patient was studied on MR within 2 hours of intraventricular instillation of a water soluble iodinated contrast agent (3 mL of Isovue-300) through an intraventricular shunt to evaluate the patency of the ventricular system in noncommunicating hydrocephalus. A second patient was evaluated on MR approximately 2 hours after lumbar myelography (10 mL Isovue-300), for possible postoperative lumbar adhesive obstruction.

Five additional subjects were studied with intravenous contrast agents (100 mL of Renografin-76) following computed tomography (CT), for the purpose of examining known cerebral tumors (three meningiomas, one glioblastoma multiforme, and one dural metastasis from carcinoma of the prostate). All patients with cerebral neoplasia also had Gd-DTPA (0.1 mmol/kg) administered for further evaluation. In all cases, subsequent studies were acquired for

comparison before administration or following the excretion of the iodinated contrast agent. In two of the cases, the patients were referred from an outside institution with a history of cerebral neoplasm. In these cases, both a CT and an MR were requested. In the interest of expediency, first the noncontrast MR was performed. Subsequently, iodinated contrast media was given and the MR was repeated after approximately a 1-hour delay. Then Gd-DTPA was administered and T1-weighted imaging through the tumor was acquired. Finally, the patient was sent to CT for a postcontrast study. In the three other individuals, the MR was obtained within 2 hours of a routine iodine contrast-enhanced CT examination. In these cases, the MR was repeated at 24–48 hours, allowing for reasonable clearing of the iodinated contrast agent from the body.

In Vitro Imaging Studies

The basic relationship of T1 and T2 relaxation in regard to alteration in signal intensity was studied in the 1.5 T GE Signa clinical magnet with regard to several commonly used iodinated contrast agents at full strength (Isovue, Omnipaque, and Renografin) and compared with normal saline and sterile water as a reference. In addition, serial saline dilutions (vol/vol) of Isovue-300 and Omnipaque-300 over a concentration range (1:1 to 1:6; agent:saline) were performed to grossly estimate the visibility of dilution changes in T1-weighted (500/15/2) and T2-weighted (2500/30-80/1) images. Omnipaque 180 and Omnipaque 300 are identical iodinated agents; however, they are packaged at different concentrations. This is also the case for Renografin-76 and Reno-M60.

In Vitro Relaxation Time Measurements

To accurately measure the true T1 and T2 values of these iodinated agents, the relaxation rates were measured on a GE CSI 2 T/45 MR imager operating at 2.0 T. The objective in this experiment was to demonstrate the presence or absence of an MR effect. No attempt was made to approximate the concentration of iodinated contrast in vivo, as these concentrations are not known. A standard inversion-recovery pulse sequence was used to measure T1 relaxation times, and a Hahn spin-echo pulse sequence was used to calculate T2 relaxation times (1–3).

Measurements on the CSI 2 T/45 were obtained by placing a 10-mL sample of the iodinated contrast agent or control in a 25-mL glass scintillation vial. The vial was positioned in the isocenter of the magnet, with the long axis of the vial parallel to the bore, inside a 7-cm diameter "bird cage"-imaging coil. For each sample the coil was tuned to the proton frequency of 85.56 MHz and matched to 50 ohms. The radiofrequency power and gain was set at the same level for all samples and accurate 90° and 180° pulse widths were measured. Measurements of T1 and T2, however, are from vial to vial or experiment to experiment, independent of these parameters. Copper sulfate-doped water samples of known T1 and T2, at the same volume as the in vitro samples, were premeasured for precision. Triplicate measurements of each in vitro standard were made for accuracy. Samples were analyzed after the magnetic field homogeneity had been adjusted to produce line widths of less than 50 Hz. A delay of 15 seconds between pulses was routinely employed as described above. Data was acquired in four acquisitions using a spectral width of ±5,000 Hz, a data block size of 4K, and a 25-Hz line broadening. All data was acquired in triplicate on different days, which necessitated repositioning the sample in the magnet.

In vitro relaxation measurements on the CSI 2 T/45 were made on stock solutions (approximately 1 M) of the iodinated contrast agents. The concentrations of the undiluted agent reported by the manufacturer of the contrast agent were used to calculate the molar concentration of the stock solution. Dilution of the agents with sterile saline was done to provide a concentration range of approximately 0.1–1.0 M. This range was selected to approximate the clinical dilution range that is typically used in CNS studies.

Renografin 76 is an ionic salt of diatrizoic acid and *N*-methylglucamine. This salt is also referred to as meglumine diatrizoate or diatrizoate meglumine and is an ionic material with a molecular weight of 809.13. The commercial preparation of diatrizoate meglumine (E. R. Squibb and Sons, Inc, Princeton, NJ) also contains additional diatrizoic acid in order to maximize the ionic amine-carboxylic acid salt formation by shifting the chemical equilibrium toward maximum salt formation. Consequently, it was feasible to evaluate the contribution of each chemical moiety of this ionic salt in vitro to the observed alterations in relaxation rates (R1 and R2) caused by each moiety. This was accomplished by independently measuring the concentration dependence of the relaxation rates of solutions of the components of Renografin-76 (ie, sodium diatrizoate and *N*-methyl-glucamine) and comparing them with both diatrizoate meglumine (Sigma Chemical Co., St. Louis, MO) and Renografin-76 at 2 T.

The solutions of meglumine diatrizoate, sodium diatrizoate, and *N*-methyl-glucamine (Sigma Chemical Co.) were prepared similarly in sterile saline to give 1 M stock solutions. Dilutions of these materials were made identically to that described previously. All samples were protected from light before and during the relaxation measurements.

Results

Within 2 hours following the ventriculogram, the infant with hydrocephalus demonstrated visible T1 shortening in the lateral ventricles that contained iodinated contrast media as compared to the noncommunicating, loculated fourth ventricle (Fig. 1). This differential in intensity resolved to isointensity following reabsorption of the contrast agent and shunting of both the lateral and fourth ventricles.

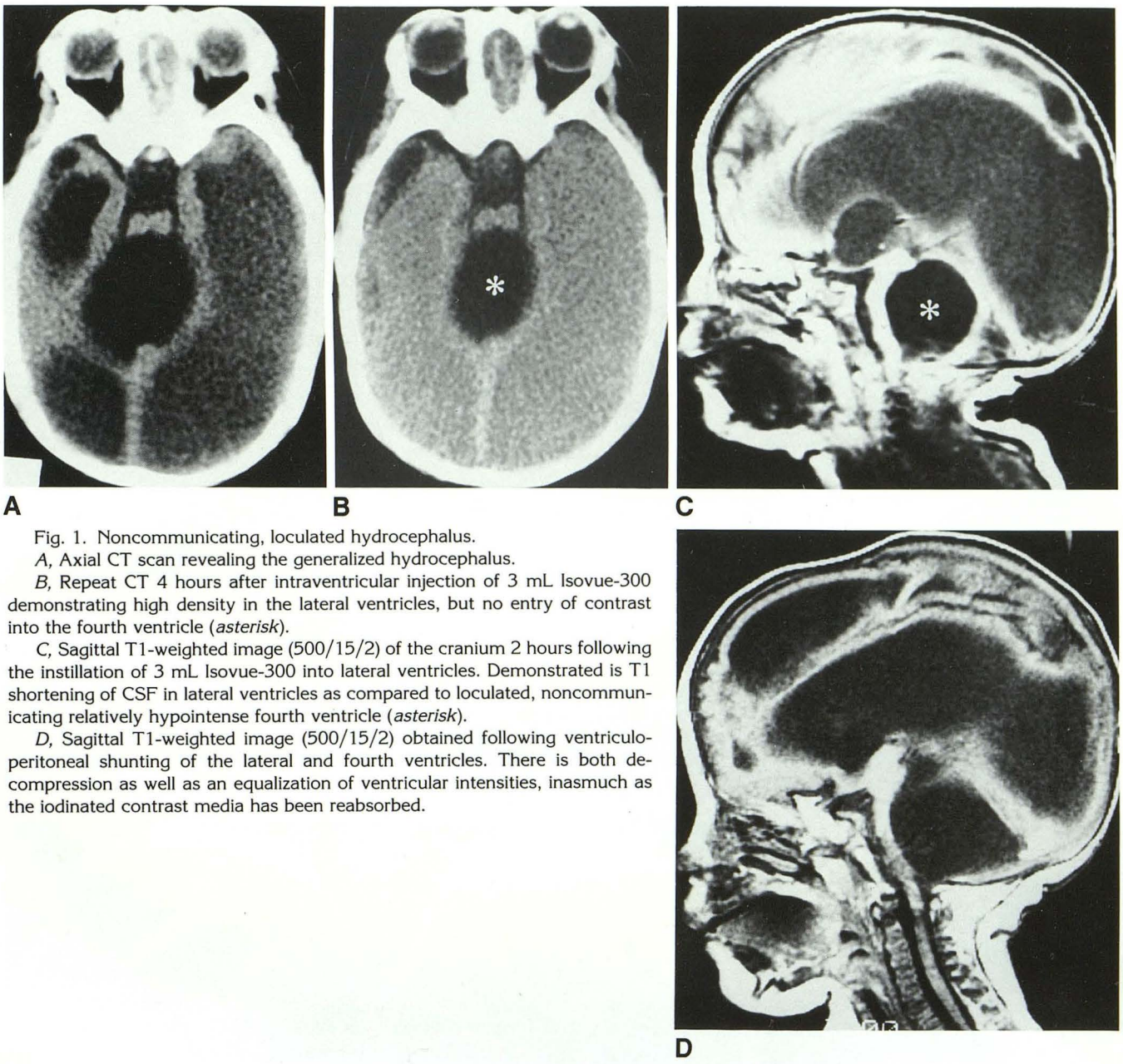

Fig. 1. Noncommunicating, loculated hydrocephalus.

A, Axial CT scan revealing the generalized hydrocephalus.

B, Repeat CT 4 hours after intraventricular injection of 3 mL Isovue-300 demonstrating high density in the lateral ventricles, but no entry of contrast into the fourth ventricle (*asterisk*).

C, Sagittal T1-weighted image (500/15/2) of the cranium 2 hours following the instillation of 3 mL Isovue-300 into lateral ventricles. Demonstrated is T1 shortening of CSF in lateral ventricles as compared to loculated, noncommunicating relatively hypointense fourth ventricle (*asterisk*).

D, Sagittal T1-weighted image (500/15/2) obtained following ventriculoperitoneal shunting of the lateral and fourth ventricles. There is both decompression as well as an equalization of ventricular intensities, inasmuch as the iodinated contrast media has been reabsorbed.

The second subject who had a nonionic iodinated contrast agent administered intrathecally revealed a complete block to cerebrospinal fluid (CSF) flow due to postoperative scarring at the level of L3-4 (Fig. 2). In the region of the myelographic contrast media accumulation above the level of the block, there was subtle but visible T2 shortening (hypointensity) of the CSF with reference to the intensity of the CSF below the myelographic block.

One of the cranial meningiomas scanned demonstrated no visible MR effect to intravenous iodinated contrast agents. A second, calcified meningioma, however, showed definite T1 shortening (hyperintensity) within the tumor after the administration of ionic iodinated contrast media, actually increasing its conspicuity within a halo of surrounding cerebral edema (Fig. 3). The third noncalcified meningioma after enhancement revealed no visible T1 effect (ie, change in intensity), perhaps because the natural intensity of the tumor overwhelmed the minor intensity change caused by the iodinated contrast agent. However, several areas within the tumor illustrated marked T2 shortening (hypointensity) relative to the precontrast study (Fig. 4).

The glioblastoma multiforme scanned following intravenous injection of ionic iodinated con-

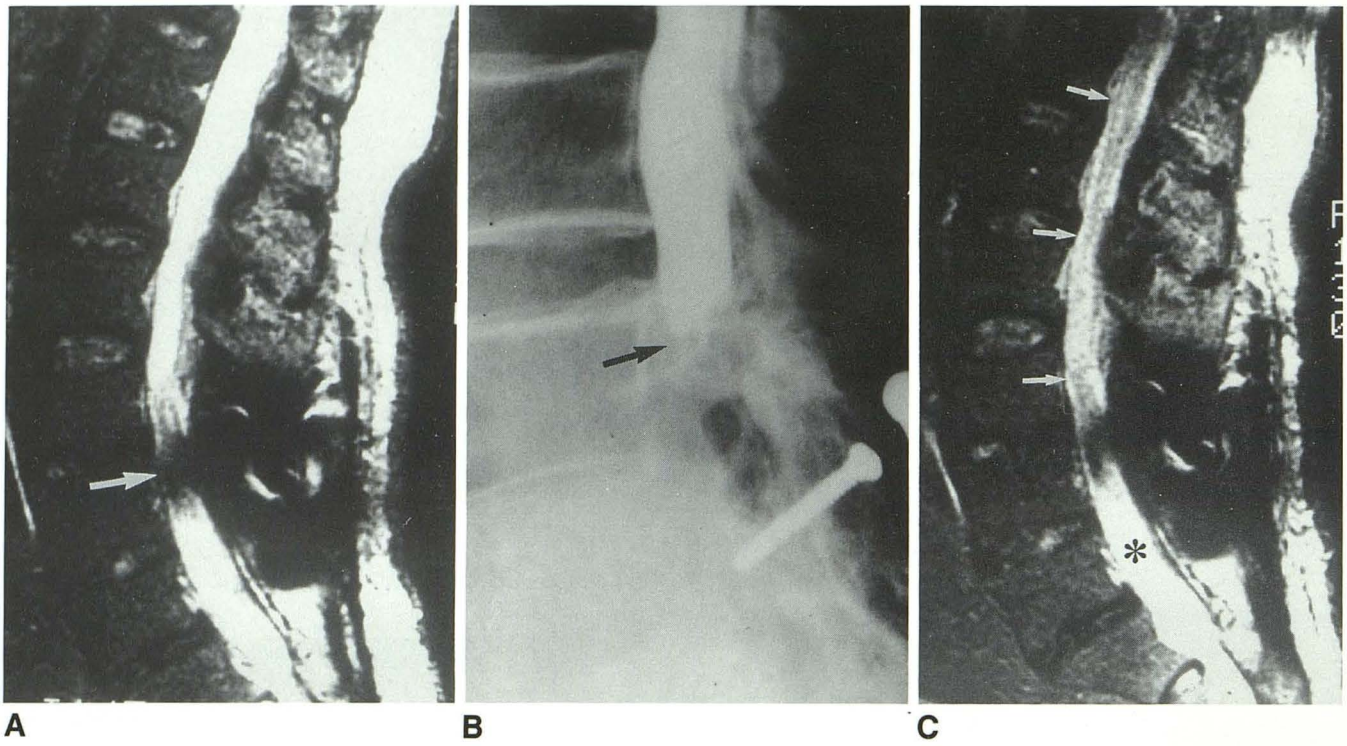

Fig. 2. Complete spinal block secondary to postsurgical scarring.

A, Precontrast T2-weighted (2500/80/1) sagittal image of the lumbosacral spine demonstrating the metallic artifact at the site of surgery (*arrow*). Note the equal intensity of the CSF above and below the operative site.

B, Immediate postmyelographic film (10 mL Isovue-300) illustrating the complete block at L3-L4 (*arrow*).

C, T2-weighted sagittal image (2500/80/1) obtained within 2 hours of myelogram demonstrating the subtle (hypointense) T2 shortening of the CSF (*arrows*) in the area of myelographic contrast medium accumulation, relative to the CSF below the level of the block (*asterisk*).

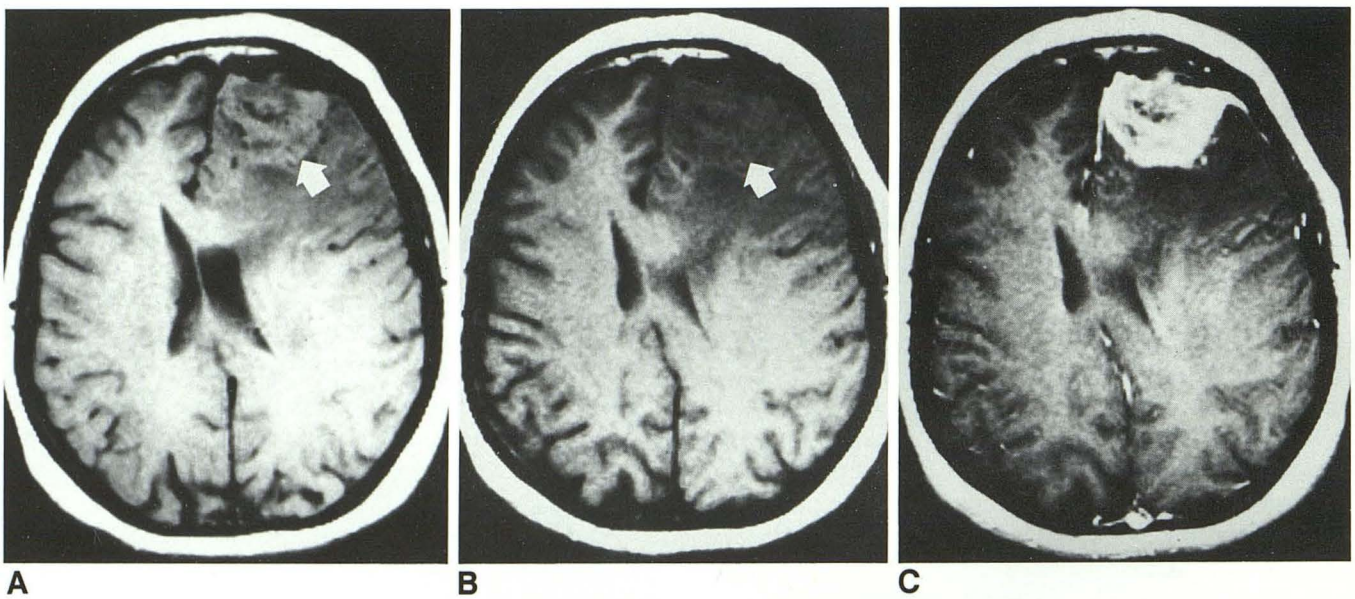

Fig. 3. Calcified frontal meningioma.

A, Postintravenous iodinated contrast-enhanced T1-weighted image (500/15/2) demonstrating the greater relative T1 shortening (hyperintense) within the matrix of the tumor, compared with *B* (*arrow*).

B, Twenty-four hour follow-up noncontrast axial T1-weighted image (500/15/2) revealing low intensity in the region of the poorly defined tumor (*arrow*) after clearing of the iodinated contrast media (calcifications proven on prior CT).

C, Immediate post-GD-enhanced T1-weighted image (500/15/2) illustrating the typical intense enhancement of tumor.

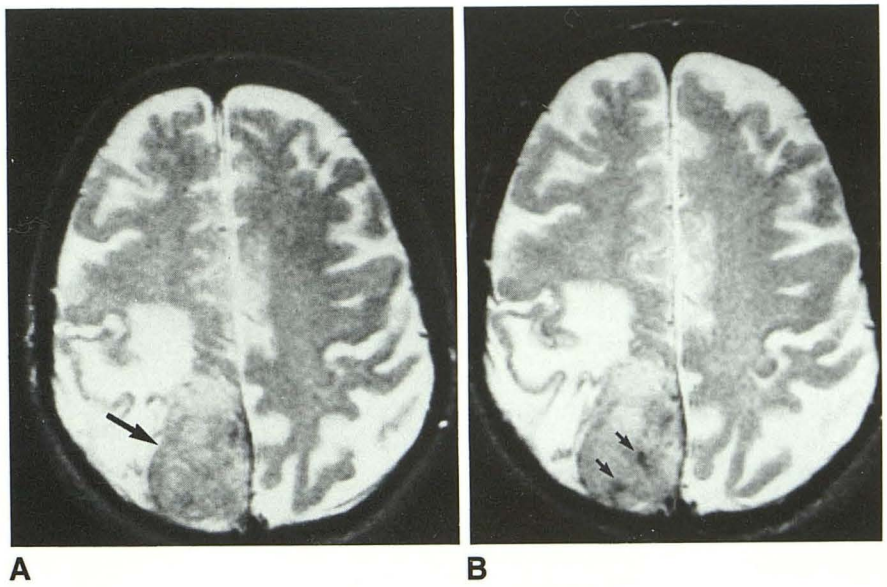

Fig. 4. Parietal convexity meningioma.

A, Precontrast T2-weighted image (2500/80/1) demonstrating the tumor mass (*arrow*).

B, T2-weighted postintravenous iodinated contrast-enhanced image (2500/80/1) illustrating several discrete areas of T2 shortening (hypointense) that were not present on the precontrast images (*arrows*). Other more subtle intensity changes within the tumor matrix are believed to be due to the slight difference in angulation between the two scans. (Note: the patient had a diagnostic postcontrast CT examination to follow the MR).

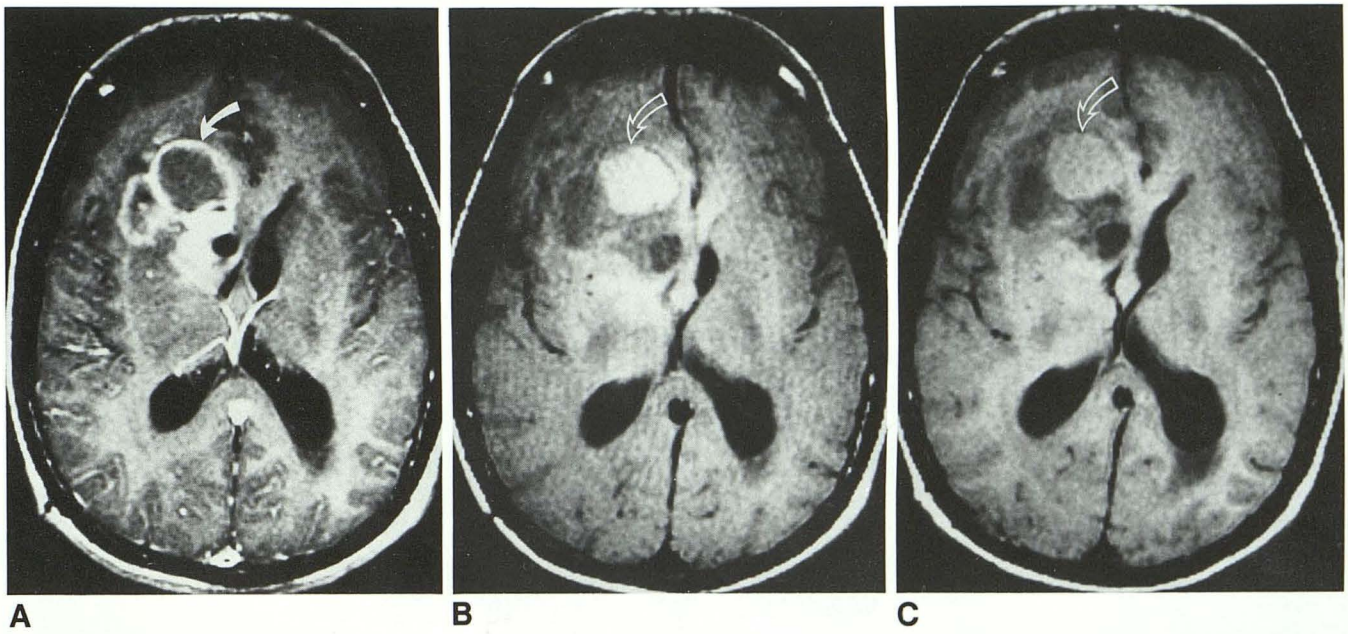

Fig. 5. Glioblastoma multiforme.

A, Gd-DTPA-enhanced axial T1-weighted image (500/15/2) illustrating the multicystic/necrotic right hemispheric mass (*arrow*).

B, Two-hour delay, postintravenous iodinated contrast-enhanced T1-weighted image (500/15/2) demonstrating definite T1 shortening (hyperintense) within one of the cystic/necrotic components of the tumor (*arrow*).

C, Forty eight-hour follow-up noncontrast T1-weighted image (500/15/2) showing the complex nature of the tumor (*arrow*), and the reduction in intensity after clearing of the iodinated contrast media (compare with *B*).

trast demonstrated T1 shortening (hyperintensity) compared to the precontrast examination within a portion of the cystic-necrotic area of the tumor (Fig. 5). This individual had the MR scan through the abnormal cystic area between 1 and 2 hours after the iodinated contrast administration, equating with a delayed study.

The last cranial patient studied had known diffuse metastatic carcinoma of the prostate. The tumor had spread to the dura and showed, after intravenous iodinated contrast administration, that the tumor was isointense with gray matter on T1-weighted images. As a result, the tumor lost conspicuity as compared to its natural hypointense state on the follow-up T1-weighted, noncontrast MR image (Fig. 6).

A subsequent post-Gd-DTPA examination immediately after the iodinated contrast acquisition in all cases of cranial tumor showed typical intense enhancement of the neoplasia that was far greater in degree than that observed with the iodinated contrast.

The in vitro imaging of three, full-strength iodinated contrast agents (Omnipaque, Isovue, Renografin) in the clinical 1.5-T MR unit showed marked T1 shortening (hyperintense) with reference to sterile water and normal saline (Fig. 7*A*). Only two of the agents (Isovue and Renografin) showed T2 shortening (hypointense) (Fig. 7*B*). Selected iodinated contrast media studied revealed a concentration dependent effect on both T1 and T2 times (Figs. 7*C* and 7*D*).

To obtain a more fundamental understanding of the causes for the observed changes in image contrast and relaxation rates, the most powerful agent, Renografin was selected for further examination. Figures 8 and 9 show the effect of increasing concentration of each of the chemical components of Renografin on R1 or R2, respectively. The T1 relaxation influence of the *N*-methyl-glucamine component is essentially equivalent to that of the sodium diatrizoate at both field strengths, however the salt (diatrizoate meglumine) causes greater T1 changes than either component alone. The T1 influence of Renografin-76, as supplied by the manufacturer, is even greater than any of the components or the salt (diatrizoate meglumine) since Renografin-76 contains additional diatrizoic acid. The T2 relaxation influence of the *N*-methyl-glucamine is much less than that of the sodium diatrizoate at both field strengths. The Renografin-76 shows a much larger increase in relaxation rate (R2) than the individual components. Both the sodium diatrizoate and diatrizoate meglumine show increased T2 influence compared to *N*-methyl-glucamine.

Discussion

Whenever consecutive diagnostic studies are being performed on the same individual, there should always be a concern that one examination might have a more or less profound effect upon the interpretation of some other test. The assumption that there should not be a relationship between conventional iodinated radiologic contrast agents to T1 and T2 relaxation times in

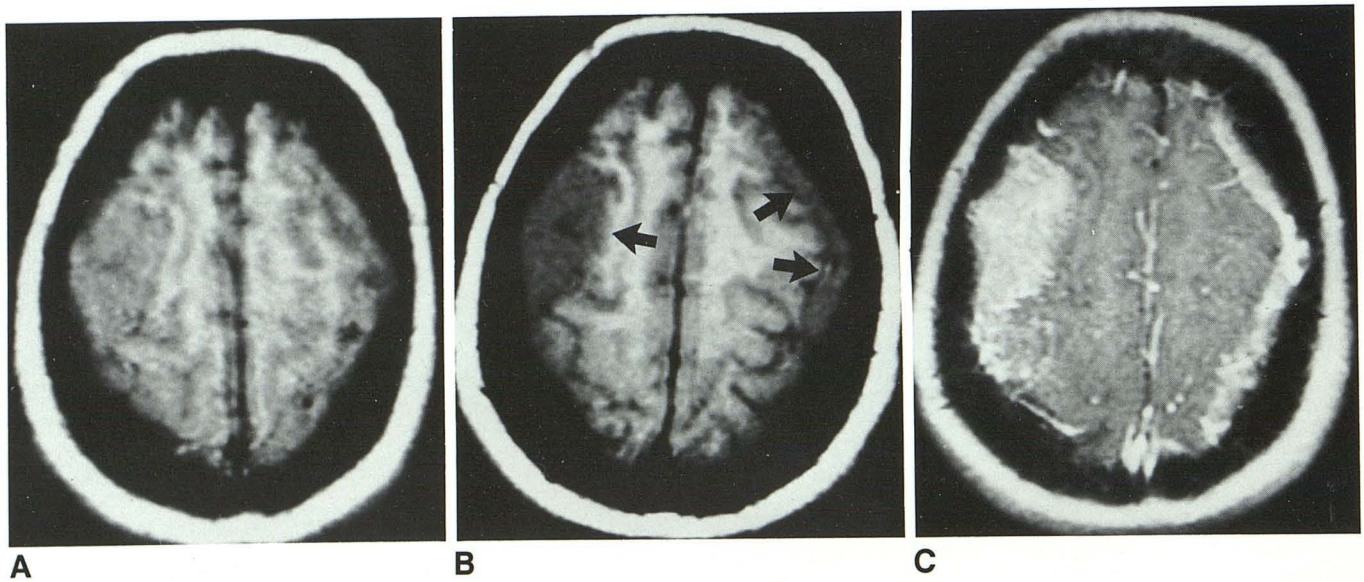

Fig. 6. Dural extension of metastatic carcinoma of the prostate.

A, Postintravenous iodinated contrast-enhanced T1-weighted acquisition (500/15/2) revealing enhancement of the tumor to isointensity with surrounding brain and illustrating potential of iodinated contrast agents to mask the presence of cranial lesions.

B, Forty-eight hour follow-up noncontrast T1-weighted image (500/15/2) showing bilateral low intensity extraaxial tumor relative to adjacent brain after clearing of the iodinated contrast media (*arrows*) (compare with *A*).

C, T1-weighted image (500/15/2) after the administration of Gd-DTPA demonstrating the typical intense enhancement of the dural tumor. This acquisition was performed immediately after the series in *B*.

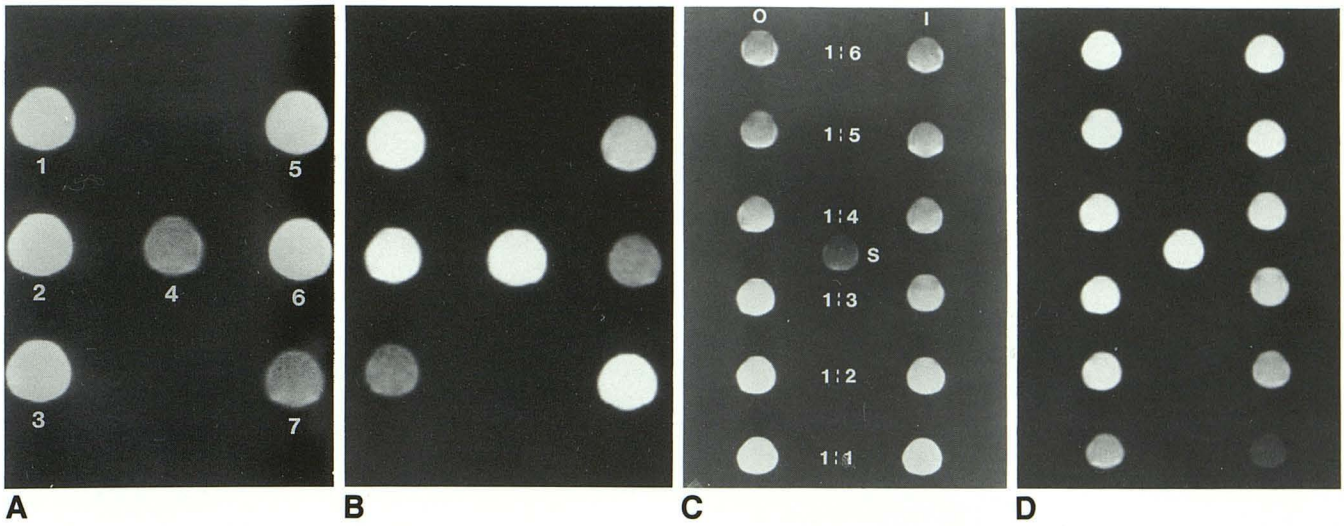

Fig. 7. 1. 5 T spin-echo in vitro images of three iodinated contrast agents demonstrating enhanced proton relaxation and a general concentration dependence.

A, T1-weighted (500/15/2) image composite set of three undiluted iodinated contrast agents as compared to normal saline and sterile water. A universal fast T1 relaxation rate is seen for all iodinated contrast media: *1*, Omnipaque-180; *2*, Omnipaque-300; *3*, Isovue-300; *4*, sterile water; *5*, Reno M-60; *6*, Renografin-76; *7*, normal saline.

B, T2-weighted (2500/80/1) image composite of identical samples in *A*. A fast T2 relaxation rate is seen for iodinated contrast samples *3*, *5*, and *6*.

C, T1-weighted (500/15/2) image composite of serial dilutions of Isovue-300 (*I*) and Omnipaque-300 (*O*) showing the effect of concentration upon T1 relaxation rate compared to normal saline (*S*). The general fast relaxation rate for both agents is noted.

D, T2-weighted (2500/80/1) image composite of identical samples in *C* showing the effect of the concentration of iodinated contrast media on the T2 relaxation time. The general fast relaxation rate for both agents is noted, being slightly more pronounced for *I* than for *O* at a given concentration.

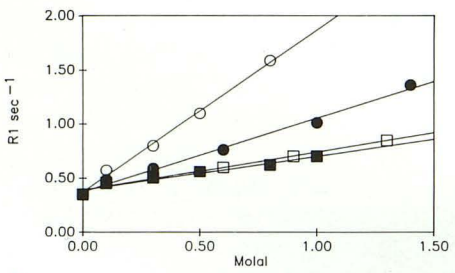

8

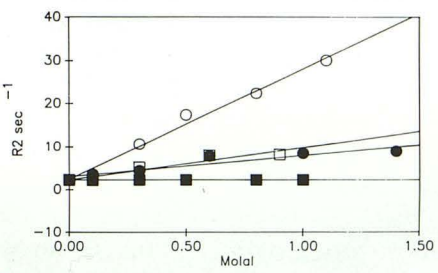

9

Fig. 8. Effect of concentration on the spin-lattice relaxation rate (R1 = 1/T1) for Renografin-76 and components at 2 T: (○) Renografin-76; (●) diatrizoate meglumine; (□) sodium diatrizoate; and (■) *N*-methyl-glucamine.

Fig. 9. Effect of concentration on the spin-spin relaxation rate (R2 = 1/T2) for Renografin-76 and components at 2 T: (○) Renografin-76; (●) diatrizoate meglumine; (□) sodium diatrizoate; and (■) *N*-methyl-glucamine.

clinical MR does not hold true. Simple in vitro testing proves this assumption to be incorrect. In vivo evaluation confirms that visible effects in MR imaging are observed with ionic or nonionic iodinated contrast agents that have been administered within 2 hours of the MR study. Alterations in MR signal intensities were seen either after direct intrathecal instillation, or following intravenous injection in subjects whose blood-brain barrier was disrupted or absent secondary to cranial neoplasia.

Figure 10 compares the three different chemical structures for Omnipaque, Isovue, and Renografin. Examination of the molecular structures of each contrast agent reveals that each possesses an iodinated aromatic ring as well as polar, hydrophilic chains that extend away from the hydrophobic aromatic region. These hydrophilic hydroxy (OH)-containing portions of the molecule can hydrogen-bond to water. The larger the number of hydroxyl moieties in the iodinated contrast agent, the larger the aqueous solvation shell that

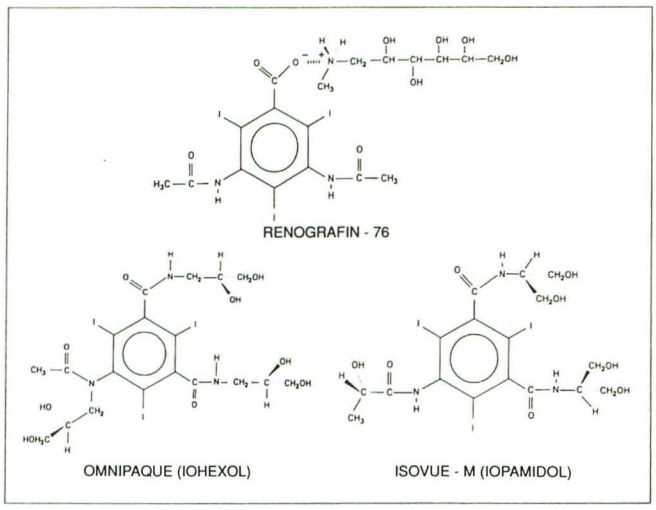

Fig. 10. Chemical structure of the ionic contrast agent, Renografin-76, and the nonionic contrast agents, Omnipaque and Isovue.

forms around the molecule. Consequently, the effective molecular weight and, correspondingly, the molecular correlation (tumbling) time increases (tumbling slows).

Renografin-76 is an ionic agent whereas the Isovue and Omnipaque are nonionic radiographic contrast agents. It was initially expected that an enhanced ability of Renografin to bind water molecules would explain the greater observed relative affects on the T1 and T2 relaxation times because of chemical exchange (4). Consequently, the *N*-methyl-glucamine portion of the ionic salt would have been most important for the observed effects due to its ability to hydrogen bond and exchange protons rapidly. However, the results indicate that *N*-methyl-glucamine has little or no effect on the observed T2 relaxation times over the concentration range studied. In addition, the effects upon the longitudinal or spin-lattice relaxation rate (R1), while present, are not large over the concentration range studied in vitro.

The primary differences between the three iodinated contrast agents in regard to their MR effects are nevertheless apparently explained in their ability to hydrogen bond to water. The agent containing the ionic salt bridge and hydrophilic groups, Renografin-76, is the best relaxation agent. Thus, it is expected and observed that agents able to bind water molecules and enhance exchange rates will increase relaxation rates more strongly. The increased T1 effect of Isovue compared to Renografin-76 or Omnipaque may be due to a more complicated relaxation mechanism. The primary structural difference between the nonionic agents, Isovue and Omnipaque, is in the appendant side chains to the aromatic ring (Fig. 10). Isovue has one methylene (CH_2) less, thereby positioning the hydroxyl groups relatively closer to the polarizable iodinated aromatic ring. Thus hydrogen-bonded waters in Isovue appear to be effected more strongly than similar waters bound to Omnipaque since they are further from the aromatic ring (3, 5). Consequently, both T1 and T2 relaxation times are decreased for Isovue compared to Omnipaque. The most significant relaxation effects observed with Renografin-76 may also be due to combined relaxation mechanisms. Clearly more work, out of the scope of this paper, is required to completely explain the observed relaxation effects and the primary relaxation mechanism(s) for these agents.

The observed T1 and T2 shortening effects of both ionic and nonionic iodinated contrast agents will sometimes have important implications in practical MR imaging. With the clinical intention being the attainment of the most accurate diagnosis in the least amount of time, thus reducing morbidity, hospitalization time and overall medical costs, the battery of diagnostic tests tend to follow one another (or even be superimposed) with increasing rapidity. In regard to MR, such a diagnostic barrage may not be the ideal triage pattern, and imaging strategies may need to be altered because of the complications outlined above. For example, if a patient has had an immediately preceding radiologic examination in which iodinated contrast agents were administered (ie, CT, myelogram, angiogram, etc), a delay period (6–24 hours) appears to be warranted to allow the contrast to clear the body. This is also true for MR examinations of the urinary tract after iodinated contrast media have recently been injected, or for situations where vicarious excretion of iodinated agents by anatomic structures such as the gallbladder might alter the MR signal. In addition, interventional procedures, in which concentrated volumes of iodinated contrast agents have been directly instilled into closed spaces or body cavities, will certainly reveal a visible MR signal alteration acutely following the procedure.

The importance of these visible changes in MR signal characteristics becomes obvious when the appearance of a tissue or lesion deviates unsuspectedly from its precontrast state. For instance, the tumors in this series, after iodinated contrast enhancement, revealed intrinsic signal character-

istics which, in any other setting, would have been interpreted as a complication such as hemorrhage, calcification, or perhaps abnormal flow phenomena. The intrathecal/intraventricular alterations in signal seen in these subjects likewise might have been misinterpreted as hemorrhage within the CSF, which was not the case. Consideration must be given to cases that, in the past, may have been interpreted as variably abnormal founded on altered signal characteristics but that were actually caused by the antecedent administration of iodinated contrast media.

Perhaps a more worrisome observation is that of enhancement of a lesion(s) to isointensity with surrounding cerebral tissue. This consideration leads to the conclusion that there is a real possibility of lesion masking by iodinated contrast agents in MR imaging of the CNS.

Based upon these in vivo and in vitro studies, it is recommended that all subjects having MR examinations of any part of the body be questioned as to the possibility of recent administration of iodinated contrast agents via any route. Depending upon the clinical situation, the presence of possible superimposed MR effects induced by the iodinated contrast agents should be taken into account when interpreting the images, or perhaps a delay in the MR study might be considered to allow the iodinated agent to clear the body. The end result should be a more precise representation and understanding of the true MR signal of the normal or pathologic tissue, and thus a more accurate rendering of the radiologic diagnosis will result.

References

1. Gunther H. *NMR spectroscopy: an introduction.* New York: John Wiley and Sons, 1980:218–224
2. Ernst RR, Bodenhausen G, and Wokaun A. *Principles of nuclear magnetic resonance in one and two dimensions.* Oxford, England: Clarendon Press, 1987:202–209
3. Shaw D. *Fourier transform N.M.R. spectroscopy.* New York: Elsevier, 1984:249–291
4. Daskiewicz OK, Hennel JW, Lubas B, Szczepkowski TW. Protein magnetic relaxation and protein hydration. *Nature* 1963;200:1006–1007
5. Ling GN. *In search of the physical basis of life.* New York: Plenum Press, 1984:437–462