

Are your **MRI contrast agents** cost-effective?

Learn more about generic **Gadolinium-Based Contrast Agents**.



FRESENIUS  
KABI

caring for life

**AJNR**

**Primary mucocele of the petrous apex: MR appearance.**

T L Larson and M L Wong

*AJNR Am J Neuroradiol* 1992, 13 (1) 203-204

<http://www.ajnr.org/content/13/1/203>

This information is current as  
of April 19, 2024.

## Primary Mucocele of the Petrous Apex: MR Appearance

Timothy L. Larson<sup>1</sup> and Matthew L. Wong<sup>2</sup>

**Summary:** Mucoceles of the petrous apex are rare. Their MR appearance varies depending on the degree of hydration or inspissation of the contents. Concise preoperative diagnosis is helpful, since mucoceles are better drained to the mastoids via an infralabyrinthine approach rather than the more risky middle cranial fossa approach used for cholesteatomas.

**Index terms:** Temporal bone, magnetic resonance; Mucocele

### Case Report

The patient is a 58-year-old woman who gave a 6-month history of right-sided tinnitus with some vertigo. Initially, the patient had significant vertigo that gradually subsided to occasional positional dizziness. The patient's physical examination was normal. The Dixie Hall type maneuvers were normal. The audiograms showed a slight right-sided high-frequency sensorineural hearing loss. The auditory brain stem response was abnormal on the right side and electronystagmography showed a right unilateral weakness consistent with peripheral vestibular dysfunction. Because of the abnormal auditory brain stem response, magnetic resonance (MR) imaging was obtained (Fig. 1). This showed a mass in the right petrous apex that was interpreted as being most consistent with a cholesteatoma.

Because of the possibility of a petrous apex cholesteatoma, the patient underwent a right middle cranial fossa approach. The geniculate ganglia was located and there was a large mucosal lined cyst just anterior to it involving the petrous apex. There was no evidence for a cholesteatoma. The area of the cyst was then exteriorized to the mastoid. The patient had an uneventful post-op course.

### Discussion

A rather large variety of processes and lesions can involve the petrous apex. They include meningiomas, chordomas, hemangiomas, chemodectoma, osteomyelitis, petrous apicitis, carotid aneurysm, metastases, cholesteatoma, cholesterol granuloma, and mucoceles, along with numerous other rare lesions. Pseudolesions, such as

asymmetric pneumatization with asymmetric fat distribution, should also be considered (1, 2).

Computed tomography (CT) is frequently the initial diagnostic study performed. Of the above lesions, cholesteatoma, cholesterol granuloma, and mucoceles would be expected to have a similar expansile erosive appearance without appreciable enhancement. A concise preoperative diagnosis would be helpful as we manage cholesteatomas through a middle cranial fossa approach. Cholesterol granulomas and mucoceles are better drained to the mastoids via an infralabyrinthine approach. This minimizes the risk of a post-operative cerebrospinal fluid leak.

Cholesterol granulomas have a fibrous lining that contains blood, hemosiderin, chronic inflammatory cells, blood vessels, fibrous tissue, and cholesterol crystals. Grossly, this appears as brownish liquid glistening with cholesterol crystals. Obstruction of ventilation is theorized to be the cause of repetitive cycles of hemorrhage and granulation tissue formation. Cholesteatomas on the other hand are solid lesions that have a capsule of stratified squamous lining and contain desquamated keratin. Grossly, this appears as a whitish friable material. Mucoceles have a lining of thin cuboidal epithelium and contain mucous. The appearance of the mucous is variable depending on whether it remains hydrated or becomes inspissated.

The cholesterol granuloma is the only lesion of the three that is readily differentiable by its MR appearance. It shows high signal intensity both on T1- and T2-weighted sequences. The areas within the lesion not showing these characteristics may show enhancement with gadolinium. These latter areas are related to granulation tissue within the lesion (3).

Cholesteatomas and mucoceles are not readily differentiable based on their CT and MR appearance. Latack et al (4), reporting on the appearance of cholesteatomas, described two lesions

Received February 26, 1991; revision requested May 15; revision received August 5; final acceptance September 6.

<sup>1</sup> 1229 Madison, Suite 900, Seattle, WA 98104. Address reprint requests to T. L. Larson.

<sup>2</sup> 901 Boren, #711, Seattle, WA 98104.

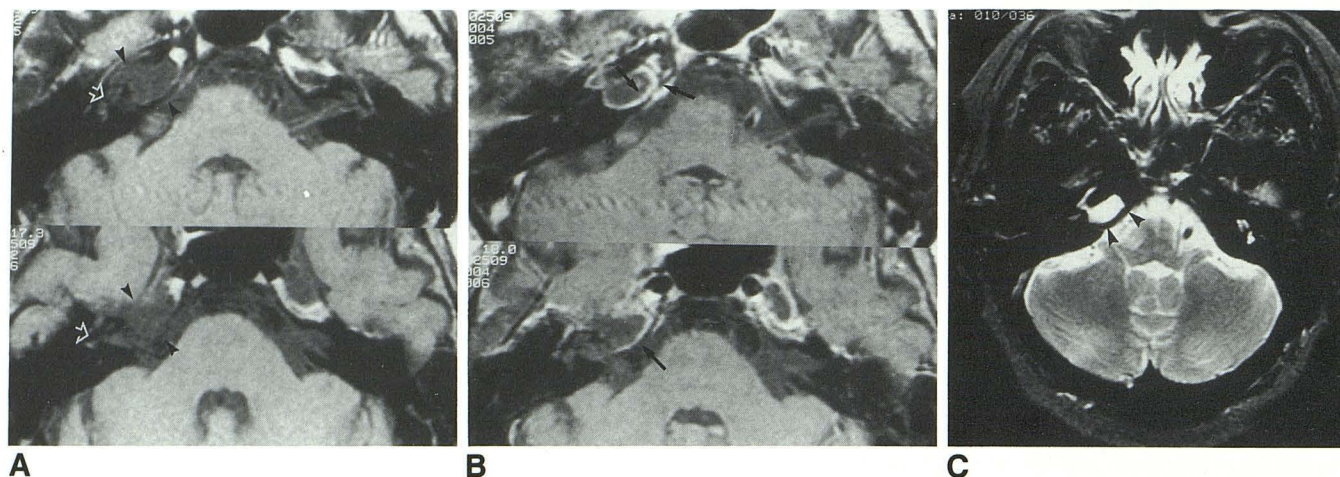


Fig. 1. Axial MR images obtained through the temporal bones.

A, Preinfusion T1-weighted (800/25/4) images showed a mass of near uniform low signal intensity in the right temporal bone (arrowheads). Note the close relationship to the membranous labyrinth and internal auditory canal (open arrows).

B, Postcontrast T1-weighted (800/25) images show apparent rim enhancement (particularly anteromedially) felt to be related to the dura (arrows).

C, T2-weighted axial images (2800/85/1) show uniform bright signal intensity to the lesion (arrowheads).

that were of diminished signal intensity on T1-weighted sequences and one that showed high signal intensity on T1-weighted images. All were of high intensity on T2-weighted images. Martin et al (5), reporting on the MR appearance of cholesteatomas of the middle ear, consistently noted low signal intensity on T1 sequences and high signal intensity on T2 sequences. Surrounding regions of enhancement were felt to be secondary to inflammatory and/or granulation tissue.

Mucoceles of the petrous apex are extremely rare. To our knowledge, the MR appearance has not been reported. There are only two other case reports in the literature. De Loshier et al (6) described the CT appearance as one of an erosive, sharply margined mass at the petrous apex. Osborn and Parkin (7) described a case, imaged by plain films and temporal bone tomograms, as showing a lytic lesion with sclerotic margins at the petrous apex.

If mucoceles of the paranasal sinus can be chosen as an appropriate model, they have a variable MR appearance, depending on the degree of hydration or inspissation of the contents. Van Tassel et al (8) reporting on the MR appearance of paranasal sinus mucoceles, noted a variable appearance depending on whether the mucocele contents were proteinaceous, hydrated, or inspissated. Theoretically, a mucocele of the petrous apex would be differentiable from a cholesteatoma if its contents were inspissated. This would result in lower T2 signal intensity than expected for a cholesteatoma.

The appearance of the mucocele in our patient presumably reflects predominantly hydrated mucocele contents rather than proteinaceous or inspissated contents. The pathologic specimen contained areas of fibrous connective tissue associated with fragments of bone and spaces lined by a single layer of cuboidal epithelium with uniform nuclei. There was no suggestion of active inflammation or neoplasm. It is unclear how the lesion relates to the patient's symptoms and findings. The follow-up is as of yet too short to know whether the surgical drainage will be of clinical benefit.

## References

1. Roland PS, Meyerhoff WL, Judge LO, Mickey BE. Asymmetric pneumatization of the petrous apex. *Otolaryngol Head Neck Surg* 1990;103:80-88
2. Haynes RC, Amy JR. Asymmetric temporal bone pneumatization: an MR imaging pitfall. *AJNR* 1988;9:803
3. Martin N, Sterkers O, Monpoint D, Julien N, Nahum H. Cholesterol granulomas of the middle ear cavities: MR imaging. *Radiology* 1989;172:521-525
4. Latack JT, Kartush JM, Kemink JL, Graham MD, Knake JE. Epidermoidomas of the cerebellopontine angle and temporal bone: CT and MR aspects. *Radiology* 1985;157:361-366
5. Martin N, Sterkers O, Nahum H. Chronic inflammatory disease of the middle ear cavities: Gd-DTPA-enhanced MR imaging. *Radiology* 1990;176:399-405
6. De Loshier HL, Parkins CW, Garek RR. Mucocele of the petrous apex. *J Laryngol Otol* 1979;93:177-180
7. Osborn AG, Parkin JL. Mucocele of the petrous temporal bone. *AJR* 1979;132:680-681
8. Van Tassel P, Lee Y, Jing B, DePena CA. Mucoceles of the paranasal sinuses: MR imaging with CT correlation. *AJR* 1989;153:407-412