Are your MRI contrast agents cost-effective?
Learn more about generic Gadolinium-Based Contrast Agents.
FRESENIUS KABI
caring for life

AJNR

Bilateral trigeminal schwannomas associated with von Recklinghausen disease.

K Yamada, T Ohta and T Miyamoto

AJNR Am J Neuroradiol 1992, 13 (1) 299-300
http://www.ajnr.org/content/13/1/299.citation

This information is current as of April 18, 2024.

Bilateral Trigeminal Schwannomas Associated with von Recklinghausen Disease

Kyozo Yamada,[1] Tomio Ohta,[1] and Takashi Miyamoto[1]

Summary: The authors present a case of von Recklinghausen disease and bilateral occurrence of tumors of cranial nerve V in a 47-year-old woman.

Index terms: Nerves, trigeminal (V); Nerves, neoplasms; Schwannoma

Although there have been many reported cases of bilateral acoustic schwannomas associated with von Recklinghausen disease (VRD), there have not, to our knowledge, been any reports concerning bilateral trigeminal schwannomas in VRD. Therefore, we report such a case.

Case History

A 47-year-old woman was admitted on February 7, 1990 with numbness of the left side of her face that had been present for 2 months. This numbness extended from the forehead to the jaw in the distribution of the trigeminal nerve. In 1983 and 1984, the patient had undergone the removal of subcutaneous tumors of the right side of the neck, in both axillae, and along the right flank. The histologic diagnosis of all these tumors was neurofibroma. The patient did not show cutaneous pigmentation, but was diagnosed as having VRD because of the occurrence of multiple neurofibromas. Her daughter also had subcutaneous fibromas and was diagnosed as VRD at another hospital. Neurologic examination showed hypesthesia in the left trigeminal nerve territory. The left masseter muscle was moderately atrophic, but showed good contraction. Other cranial nerves were all intact. Computed tomography (CT) scan demonstrated a low-density mass with ring enhancement extending from the left trigeminal ganglion into the lateral surface of the pons across the apex of the petrous temporal bone (Fig. 1A). Magnetic resonance (MR) imaging detected two abnormal masses. One extended from the left trigeminal ganglion into the lateral surface of the pons and the other at the pontine entry zone of the right trigeminal nerve. The left-sided tumor showed low intensity on T1-weighted image and high intensity on T2-weighted image. Both of these masses also showed ring enhancement with Gd-DTPA (Figs. 1B and 1C). After a left subtemporal craniotomy, the left-sided tumor was radically resected. The tumor was cystic and contained dark-brown fluid. After the fluid was evacuated, the tumor was cut into halves. The posterior pieces of the tumor were easily pulled out and the trigeminal nerve was identified at this point. During resection of the anterior portion of the tumor, some venous blood from the cavernous sinus appeared and the operation was stopped at this point. There remains the possibility of some residual tumor within the cavernous sinus. The histologic diagnosis was a schwannoma. The patient was discharged with no neurologic deficits but slight numbness on her left cheek. Follow-up MR 15 months after the operation showed no recurrence of the left-sided tumor and no apparent change of the right-sided tumor. At this time, she complained of very slight left cheek numbness, but no symptoms or signs along the right trigeminal nerve distribution.

Discussion

Trigeminal schwannomas account for 0.07% to 0.28% of intracranial tumors and 0.8% to 8% of intracranial schwannomas (1, 2). The first description of an intracranial trigeminal neurinoma was provided by Smith in 1849, and, since that time, approximately 250 cases have been reported (1). Although CT can demonstrate relatively small and asymptomatic tumors at the petrous apex, the preoperative characterization of such lesions still remains unsatisfactory (3). The reason is that small tumors near sella turcica, including the area of Meckel's cave, may not be detected because of beam hardening near the base of the skull and normal enhancement of the cavernous sinus (3, 4). The introduction of MR has led to improved diagnosis of small trigeminal schwannomas located in Meckel's cave or at the nerve entry site in the pons. In our patient, the presence of the right-sided tumor was established only by MR, although, in retrospect, the lesion was present on CT (Fig. 1A). The left-sided tumor

Received January 2, 1991; revision requested February 22; revision received August 26; final acceptance August 28.

[1] Department of Neurosurgery, Osaka Medical College, 2-7, Daigakumachi, Takatsuki, Osaka, Japan 569. Address reprint requests to K. Yamada.

AJNR 13:299–300, Jan/Feb 1992 0195-6108/92/1301-0299 © American Society of Neuroradiology

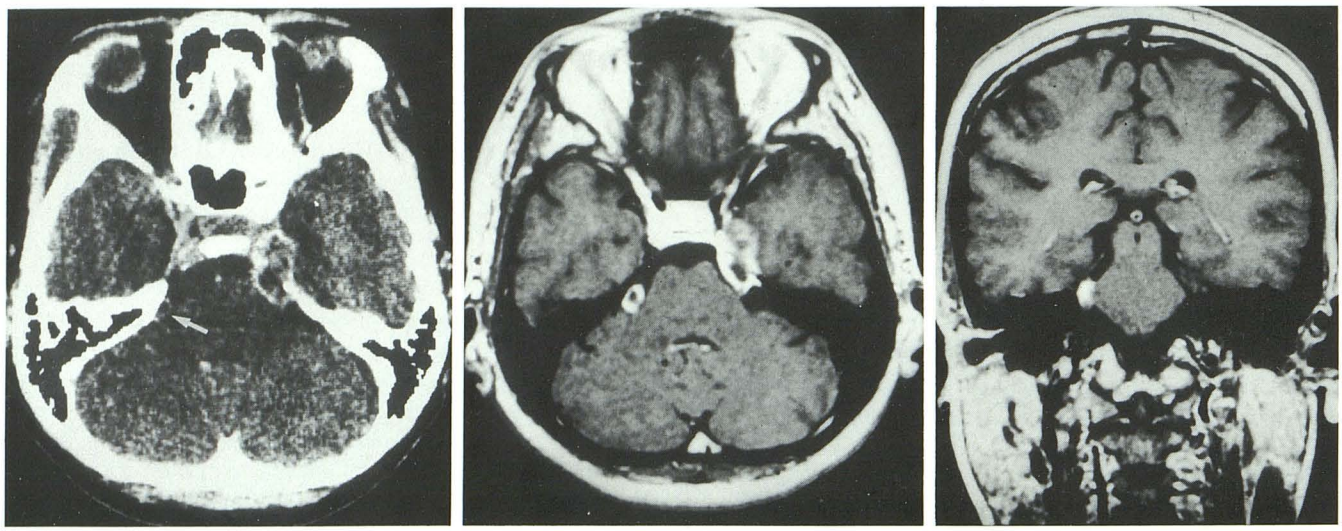

Fig. 1. *A*, Enhanced CT scan; a low-density mass with ring-enhancement located at the left trigeminal ganglion and extended to the lateral surface of the pons across the apex of the petrous temporal bone. Very tiny enhancement (arrow) was also found at the right pontine entry zone of the trigeminal nerve.

B, Axial scan magnetic resonance imaging; T1-weighted image (600/30/1, TR/TE/excitation) after intravenous injection of 0.1 mmol/kg Gd-DTPA. The mass was located along the left trigeminal nerve and extended to the lateral surface of the pons. The other mass, showing inner low-intensity surrounded by isointensity with ring enhancement, was located at the right pontine entry zone of the trigeminal nerve.

C, Coronal scan magnetic resonance imaging; T1-weighted image (600/30/1) after intravenous Gd-DTPA injection. The right-sided mass with enhancement effect was easily observed adjacent to the pons.

was cystic and showed a ring enhancement on both CT and MR.

There have been many reports concerning multiple intracranial tumors in patients with VRD. Vaquero et al (5) reported a case of simultaneous posterior and middle cranial fossa schwannomas. In their report, the origin of the middle fossa schwannoma was not identified and the eighth nerve was the origin of the posterior fossa schwannoma. Kasuya et al (6) reported the association of an orbital, trigeminal, and acoustic schwannoma on the same side in a patient with a "forme fruste" type of VRD that did not include the cutaneous pigmentations and multiple neurofibromas. Because our case shows bilateral trigeminal schwannomas and multiple neurofibromas without cutaneous pigmentations, we believe this case may be included in the central-neurofibromatosis (NF-2) category.

Rigamonti et al (7) reported atrophy of the ipsilateral masseter muscle in a patient with a trigeminal neurinoma detected by MR. Such muscle atrophy was also seen with our case on the left side, but the right-sided tumor was thought to be too small to cause masseter atrophy. Disturbance of the sensory division by a tumor may cause hypesthesia, but this loss of sensation is subjective and variable. The finding of ipsilateral masseter atrophy may thus be of value in the diagnosis of trigeminal schwannoma.

References

1. Pollack IF, Sekhar LN, Jannetta PJ, Janecka IP. Neurinomas of the trigeminal nerve. *J Neurosurg* 1989;70:737–745
2. McCormick PC, Bello JA, Post KD. Trigeminal Schwannoma. *J Neurosurg* 1988;69:850–860
3. Page RD, Lye HR. Trigeminal Schwannomas: has the "new technology" made any difference? *Br J Neurosurg* 1988;2:67–71
4. Embry BM, Pritchard R. Trigeminal neurilemmoma: appearance on magnetic resonance imaging. *South Med J* 1989;82:653–656
5. Vaquero J, Cabezudo JM, Leunda G, Carrillo R, Bravo G. Simultaneous posterior and middle cranial fossa neurinomas. *Acta Neurochir (Wien)* 1981;55:321–327
6. Kasuya H, Kadowaki H, Yato S, Kubo O, Kagawa M, Kitamura K. Forme fruste of von Recklinghausen's disease: unilateral association of an orbital neurinoma, a trigeminal neurinoma, and an acoustic neurinoma. *Neurosurgery* 1986;18:208–211
7. Rigamonti D, Spetzler RF, Shetter A, Drayer BP. Magnetic resonance imaging and trigeminal schwannoma. *Surg Neurol* 1987;28:67–70