

Are your MRI contrast agents cost-effective?

Learn more about generic Gadolinium-Based Contrast Agents.



**FRESENIUS
KABI**

caring for life

AJNR

Cerebral arteriovenous malformation causing epistaxis.

L N de Tilly, R Willinsky, K TerBrugge, W Montanera, T Marotta and M C Wallace

AJNR Am J Neuroradiol 1992, 13 (1) 333-334

<http://www.ajnr.org/content/13/1/333.citation>

This information is current as
of April 18, 2024.

Cerebral Arteriovenous Malformation Causing Epistaxis

L. Noel de Tilly,¹ R. Willinsky,¹ K. TerBrugge,¹ W. Montanera,¹ T. Marotta,¹ and M. C. Wallace²

Summary: We present an unusual case of epistaxis due to a right frontal arteriovenous malformation and underscore the need to follow a strict protocol in the angiographic work-up for possible embolization of epistaxis.

Index terms: Arteriovenous malformations, cerebral; Epistaxis; Cerebral angiography, indications

Epistaxis can be life threatening and may not respond to conventional conservative measures such as packing. In our institution, between 1984 and 1991, we have treated 65 patients with embolization who had epistaxis that did not stop with nasal packing, with a success rate of 90%. This case report illustrates an unusual example of epistaxis due to a right frontal arteriovenous malformation (AVM).

Case Report

A 53-year-old man had a 4-week history of intermittent epistaxis. Despite anterior and posterior nasal packing for 4 days, he continued to bleed. The patient required transfusion with four units of blood. He had no history of previous nose bleeds and he was not being given anticoagulants. There was no family history of epistaxis and he had no skin telangiectasias. A left carotid angiogram showed a micro AVM (nidus less than 1 cm) (Figs. 1A, 1B, and 1C) on the undersurface of the right gyrus rectus. It was fed by an orbitofrontal branch of the right anterior cerebral artery and drained into two cortical veins that emptied into the superior sagittal sinus. In addition, a venous network was also opacified in the nasal fossa. Superselective angiography was attempted to further define the morphology of the AVM. However, we were unable to catheterize selectively the feeding artery. The AVM was resected surgically without complication through a right frontal craniotomy. Since the removal of the AVM, the patient has not experienced any further epistaxis. A control angiogram showed no residual AVM and disappearance of the nasal venous network (Fig. 1D).

Discussion

Nasal packing is the first line of treatment in epistaxis; however, during the past decade, embolization has become the treatment of choice in those that do not respond to packing. Between 1981–1988, we treated 40 patients by embolization. Most cases were idiopathic and occurred in patients over 50 years of age, probably related to hypertension. The other causes included coagulopathy, juvenile nasopharyngeal angiofibroma, Rendu-Osler-Weber syndrome, vascular malformation of the nasal cavity, and trauma (1). Epistaxis can also result from a biopsy of an unknown vascular nasal mass or a rupture of a cavernous aneurysm (2) or a carotid cavernous fistula leaking into the sphenoid sinus (3). A case report of a petrous internal carotid aneurysm causing epistaxis by rupturing into the adjacent eustachian tube reminds one to also consider the middle ear as a source of such bleeding (4).

We know of only one other report of a brain AVM resulting in epistaxis (5). In this previous report, the malformation was located in the right parietal lobe and drained partially to the face through orbital and nasoethmoidal veins via the cavernous sinus. Epistaxis occurs in 85% of patients with Rendu-Osler-Weber syndrome (6). Twenty-eight percent of these patients have associated brain AVMs (7, 8). However, in Rendu-Osler-Weber syndrome the epistaxis is caused by nasal telangiectasias, not the brain AVM.

Venous communication between cortical veins of the frontal lobe and the nasal mucosa could be the cause of the nasal bleeding in our patient. Such a communication is possible through the foramen caecum. This ostium, located in the midline between the frontal bone and crista galli, can transmit a small emissary vein that connects

Received March 26, 1991; accepted and revision requested May 31; revision received July 25, final acceptance August 7.

¹ Department of Radiological Sciences, The Toronto Hospital, Western Division, University of Toronto, 399 Bathurst Street, Toronto, Ontario, Canada M5T 2S8. Address reprint requests to R. Willinsky.

² Surgery Division of Neurosciences Department, The Toronto Hospital, Western Division, Toronto, Ontario, Canada M5T 2S8.

AJNR 13:333–334, Jan/Feb 1992 0195-6108/92/1301-0333 © American Society of Neuroradiology

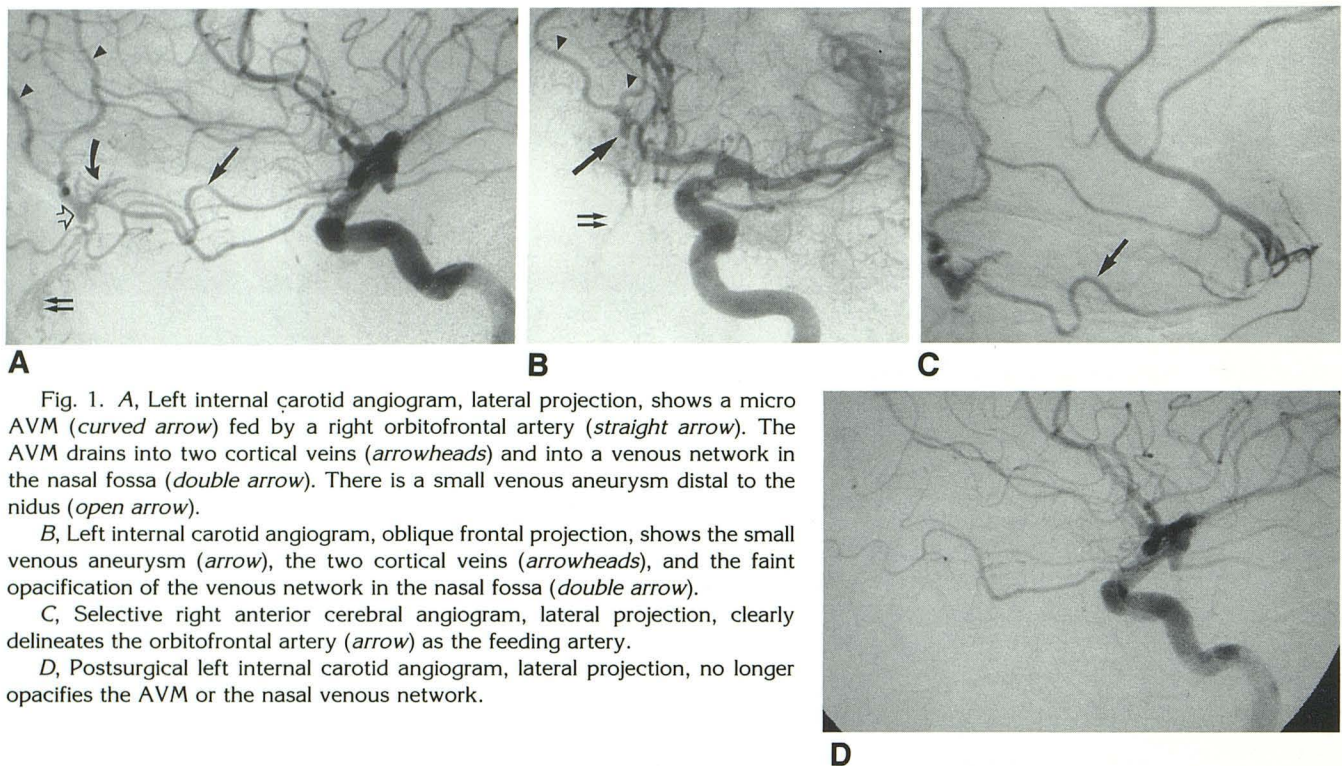


Fig. 1. A, Left internal carotid angiogram, lateral projection, shows a micro AVM (curved arrow) fed by a right orbitofrontal artery (straight arrow). The AVM drains into two cortical veins (arrowheads) and into a venous network in the nasal fossa (double arrow). There is a small venous aneurysm distal to the nidus (open arrow).

B, Left internal carotid angiogram, oblique frontal projection, shows the small venous aneurysm (arrow), the two cortical veins (arrowheads), and the faint opacification of the venous network in the nasal fossa (double arrow).

C, Selective right anterior cerebral angiogram, lateral projection, clearly delineates the orbitofrontal artery (arrow) as the feeding artery.

D, Postsurgical left internal carotid angiogram, lateral projection, no longer opacifies the AVM or the nasal venous network.

the veins in the nose with the rostral end of the superior sagittal sinus (9). The anterior aspect of the superior sagittal sinus is an inconstant structure. The small emissary vein previously described is more commonly present when the rostral aspect of the superior sagittal sinus is well formed. The existence of this connection has, however, been questioned by others (10).

This case report illustrates the need to follow a strict protocol in the angiographic work-up for possible embolization of epistaxis. Our protocol includes the study of both internal carotid arteries, both internal maxillary arteries, and both facial arteries. Adherence to this protocol will avoid overlooking unusual causes of epistaxis.

References

1. Marotta T, et al. Presented at the Annual Meeting of the Canadian Association of Radiologists, Quebec City, October 1989.
2. Gelbert F, Reizine D, Stecken J, Ruffennacht D, Haffont J, Merland JJ. Epistaxis grave par rupture de la carotide interne dans le sinus sphenoidal: traitement endovasculaire. *J Neuroradiol* 1986;13:163-171
3. Wilson CB, Markesbery W. Traumatic carotidocavernous fistula with fatal epistaxis: report of a case. *J Neurosurg* 1966;24:111-113
4. Willinsky R, Lasjaunias P, Pruvost P, Boucherat M. Petrous internal carotid aneurysm causing epistaxis: balloon embolization with preservation of the parent vessel. *Neuroradiology* 1987;29:570-572
5. Frayne TA, Boldt DW. Massive epistaxis caused by cerebral arteriovenous fistula. *J Laryngol Otol* 1979;93:1127-1129
6. Lasjaunias P, Berenstein A. *Surgical neuroangiography*. Vol 2. New York: Springer-Verlag, 1987:379-383
7. Roman G, Fisher M, Perl DP, Poser CM. Neurological manifestations of hereditary hemorrhagic telangiectasia (Rendu-Osler-Weber disease): report of two cases and review of the literature. *Ann Neurol* 1978;4:130-144
8. Willinsky R, Lasjaunias P, TerBrugge K, Burrows P. Multiple cerebral arteriovenous malformations (AVM's): review of our experience from 203 patients with cerebral vascular lesions. *Neuroradiology* 1990;32:207-210
9. Kapp JP, Schmidek HH. *The cerebral venous system and its disorder*. Orlando, FL: Grune & Stratton, 1984:3-23
10. Kaplan H, Browder A, Browder J. Nasal venous drainage and the foramen cecum. *Laryngoscope* 1973;83:327-329