

Are your **MRI contrast agents** cost-effective?

Learn more about generic **Gadolinium-Based Contrast Agents**.



FRESENIUS
KABI

caring for life

AJNR

Partial albinism with immunodeficiency: a rare syndrome with prominent posterior fossa white matter changes.

J Brismar and H A Harfi

AJNR Am J Neuroradiol 1992, 13 (1) 387-393

<http://www.ajnr.org/content/13/1/387>

This information is current as of April 17, 2024.

Partial Albinism with Immunodeficiency: A Rare Syndrome with Prominent Posterior Fossa White Matter Changes

Jan Brismar¹ and Harb A. Harfi²

Purpose: To describe our experience in infants with partial albinism and immunodeficiency (PAID), a rare, recently recognized, probably autosomal recessive disorder. **Patients and Methods:** Five infants suffering from this disease were examined with CT of the brain and four of these patients also underwent MR. Four of the five children also underwent follow-up CT or MR exams. **Results:** Three of the patients followed with serial examinations demonstrated a rapid progress of white matter changes together with a loss of brain tissue over a few months. In all four patients subjected to follow-up, the posterior fossa white matter structures were severely involved during the course of the disease. **Conclusions:** This syndrome should be added to the list of demyelinating diseases, and should be kept in mind when white matter changes are prominent in the posterior fossa.

Index terms: Immune deficiency; Degenerative brain disease; Demyelinating disease; White matter, abnormalities; Cerebellum, atrophy

AJNR 13:387-393, January/February 1992

In 1978, Griscelli et al (1) presented two unrelated patients with partial albinism associated with repeated pyogenic infections due to profound immunologic abnormalities. A similar clinical picture of partial albinism and decreased resistance to infections also characterizes the Chédiak-Higashi syndrome (2) where, however, the impaired host defense mechanisms is due to defective granulocytes. Since the original report, Griscelli has seen another six patients with partial albinism and immunodeficiency (PAID) for a total of eight patients from six families (C. Griscelli 1990, personal communication).

During the last 3 years, five patients with PAID underwent neuroradiologic evaluation at our institution. Four of these children were studied with both computed tomography (CT) and magnetic resonance (MR) imaging, the fifth infant only with

CT. The results of these studies form the basis for this report.

Materials and Methods

Between June 1988 and December 1990, 11 children from four families were diagnosed as suffering from PAID. Details of the immunologic, clinical, and neurologic findings in these patients will be published elsewhere (H. A. Harfi, B. Hainau, R. Sabbah, and J. Brismar, manuscript in preparation).

Five of these patients were examined with CT of the brain and four were also imaged with brain MR. Relevant clinical data on these five patients are summarized in Table 1. Clinical diagnosis was suggested in all cases by ash-blond hair, a fair complexion, and the history of multiple infections. Diagnosis was confirmed by microscopy of skin biopsy and hair (showing characteristic melanin clumping in the hair shafts, and heavily pigmented melanocytes loaded with melanin granules, respectively) (1), by the presence of immunologic abnormalities, and by the absence of the granulocyte abnormalities seen in the Chédiak-Higashi syndrome.

For CT, 10-mm thick contiguous axial slices were obtained using either a GE 9800 (GE Medical Systems, Milwaukee, WI) or Picker 1200SX (Picker International, Highland Heights, OH) scanner. Contrast medium (Ultravist, 2 mL/kg body weight) was given intravenously in three of the patients. The MR studies were performed with a Picker Vista 1.5 T device using 7-mm thick, T1-weighted (600/20/2; TR/TE/exitations) and dual echo T2-weighted

Received March 11, 1991; revision requested May 29; revision received June 28; final acceptance July 11.

¹ Department of Diagnostic Radiology, King Faisal Specialist Hospital and Research Centre, P.O. Box 3354, Riyadh 11211, Saudi Arabia. Address reprint requests to J. Brismar.

² Section of Allergology & Clinical Immunology, Department of Pediatrics, King Faisal Specialist Hospital and Research Centre, Riyadh 11211, Saudi Arabia.

AJNR 13, 387-393, Jan/Feb 1992 0195-6108/92/1301-0387
© American Society of Neuroradiology

TABLE 1: Clinical history and findings in five patients with PAID

Case No.	Age at Admission	Sex	Family History	Parental Consanguinity	Clinical History on Admission	Clinical Findings on Admission
1	11 mo	Male	3 1st cousins same disease	1st cousins	Diagnosed due to family history. Delayed development.	Grayish-silvery hair. Hepatosplenomegaly. CNS: hypotonia, increased reflexes.
2	16 mo	Female	None	1st cousins	Last month, attacks of myoclonic fits, with loss of consciousness.	Fair, partly depigmented skin. Grayish-golden hair. During 3-mo hospital stay developed hypotonia, severe psychomotor retardation.
3	12 mo	Female	None	1st cousins	Recurrent fever since 2.5 mo and pancytopenia.	Fair, grayish-silvery hair. Hepatosplenomegaly. Developed seizures, retardation and respiratory failure.
4	16 mo	Male	One parental aunt, one sibling same disease	Double 1st cousins	Accidentally found axillar lymphadenopathy: histiocytosis.	Mink-silvery hair. Extensive lymphadenopathy. Papular skin lesions. Infiltrates in liver, spleen and one kidney. Neurologically normal.
5	5 yr	Female	One sister died at 7 mo in similar picture	1st cousins	Episodes of fever, anemia, hepatosplenomegaly since age 2 yr. Last year, 3 episodes of relapsing neurologic symptoms leaving sequelae.	Grayish-golden hair, partly depigmented skin. Comatose with increased tone and reflexes, clonus, pos. Babinski sign.

(2000/40,80/2) axial slices, gapped 0-2.5 mm (depending on head size), and T1-weighted sagittal slices.

Both the CT and the MR studies were evaluated for ventricular dilatation, for widening of sulci, and for increased white matter T2 signal, all subjectively graded as either absent (N), slight (+), moderate (++) or severe (+++). From MR, white matter changes were evaluated separately for four regions: the supratentorial subcortical white matter, the cerebellar white matter, the internal capsule and allied central structures, and the pons and brain stem. CT studies were evaluated for white matter abnormalities only for the two former regions.

Results

The results in our five patients are summarized in Table 2. In one of the infants (case 1) the CT on admission only showed slight widening of the sulci and fissures, and slight accentuation of the normally seen posterior fossa white matter low density (Fig. 1); no further neuroradiologic examinations were performed.

In three of the children, white matter changes were present on the initial CT examination; in one of them (case 5), marked, very irregular subcortical white matter changes were found and also swelling of the pons (Figs. 2A-2C), in the other two (cases 2 and 4) only the cerebellar white matter was affected (Figs. 3A and 3B). In one of these two latter infants (case 2), MR the following day (Figs. 4A and 4B) confirmed that the white matter changes were indeed limited to the cerebellum.

In the fifth patient (case 3), the initial CT only showed increased density within the left thalamus (Fig. 5A); 3.5 months later, MR showed severe generalized white matter disease (Figs. 5B-5D), another 2 months later loss of brain tissue was obvious (Fig. 5E). A rapid progress of the white matter changes was also seen in two of the other three patients that were followed with serial examinations. In a 4-year-old girl (case 5), the initial irregular white matter changes and pontine swell-

TABLE 2: Findings at CT and MR of the brain in five patients with PAID

Case No.	Age at onset of neurologic symptoms or signs	Age at neuroimaging	CT/MR	"Atrophy"			White Matter Changes			Pons, basal ganglia
				Sulci, fissures	Ventricles	Posterior Fossa	Subcortical white matter	Central white matter	Posterior fossa white matter	
1	6 mo	11 mo	CT	++	N ^a	N	N		N	
2	15 mo	16 mo	CT	++	++	N	N		+	
		+1 day	MR	++	++	N	N	N	++	N
		+1 week	MR	++	+++	N	+ ^b	+	++	N
		+2 weeks	CT	++	++ ^c	N	N		++	
		+5 weeks	CT	++	++	++	+++		N	
		+3 weeks	CT	+++ ^d	++	++	+++		++	
3	9 mo	12 mo	CT	+	+ ^e	N	N		N	Thalamic bleed
		+3.5 mo	MR	+	+	N	++	++	+++	+++
		+2 mo	CT	++	+	N	++		+++	
		+2 weeks	CT	++	++	+	++		+	Multiple new central bleeds
4	Neurologically normal	17 mo	CT	N	N	N	N		++	
		+1 mo	MR	N	N	N	++	+	++	+
		+1 mo	CT	N	N	N	N		+	
5	4 yr	5 yr	CT	N	N	N	+++ ^f		N	- ^g
		+6 weeks	CT	+	+	++	++		++	
		+5 mo	CT	N	N	+	++		+	
		+1 mo	MR	N	N	N	+++	++	++	++
		+6 weeks	CT	N	N	N	+++		++	
		+6 mo	CT	++	++	++	++		++	

^a N, absent.

^b Only immediately periventricular, thought to indicate active hydrocephalus; ventriculo-peritoneal shunt was inserted.

^c After shunting.

^d Large bilateral extracerebral fluid collections.

^e Only one temporal horn.

^f Marked, very irregular white matter changes.

^g Brainstem markedly swollen, of decreased attenuation, deforming quadrigeminal cistern and 4th ventricle. Normal at subsequent examinations.

ing subsided and periventricular and posterior fossa white matter low density was seen on sequential CT examinations over a 6-month period (Figs. 2D and 2E); 2 months later, a marked progress to severe generalized white matter disease was seen, associated with ventricular compression from brain swelling (Figs. 2F-2H). Another 6 months later, pronounced atrophy was present. In case 2, high T2 intensity zones around the lateral ventricles appeared between two MR examinations obtained one week apart. Since the ventricular size also increased, the findings were interpreted as active hydrocephalus and a ventriculo-peritoneal shunt was inserted. Over the next 2 months, this patient progressed to severe generalized white matter changes and marked atrophy (Figs. 4C and 4D). In case 4, the initial CT only showed posterior fossa white matter changes; 4 weeks later, marked supratentorial, mainly periventricular, white matter disease was

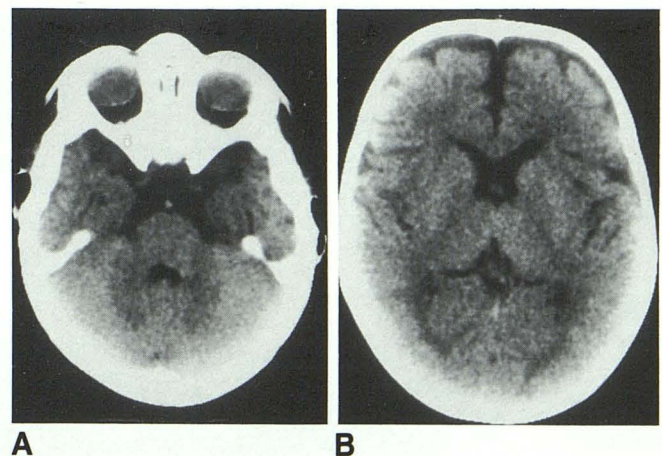


Fig. 1. Case 1, 11-month-old boy with PAID; delayed development. A and B, CT shows widened sulci, and questionable accentuation of the white matter low density in the cerebellar hemispheres.

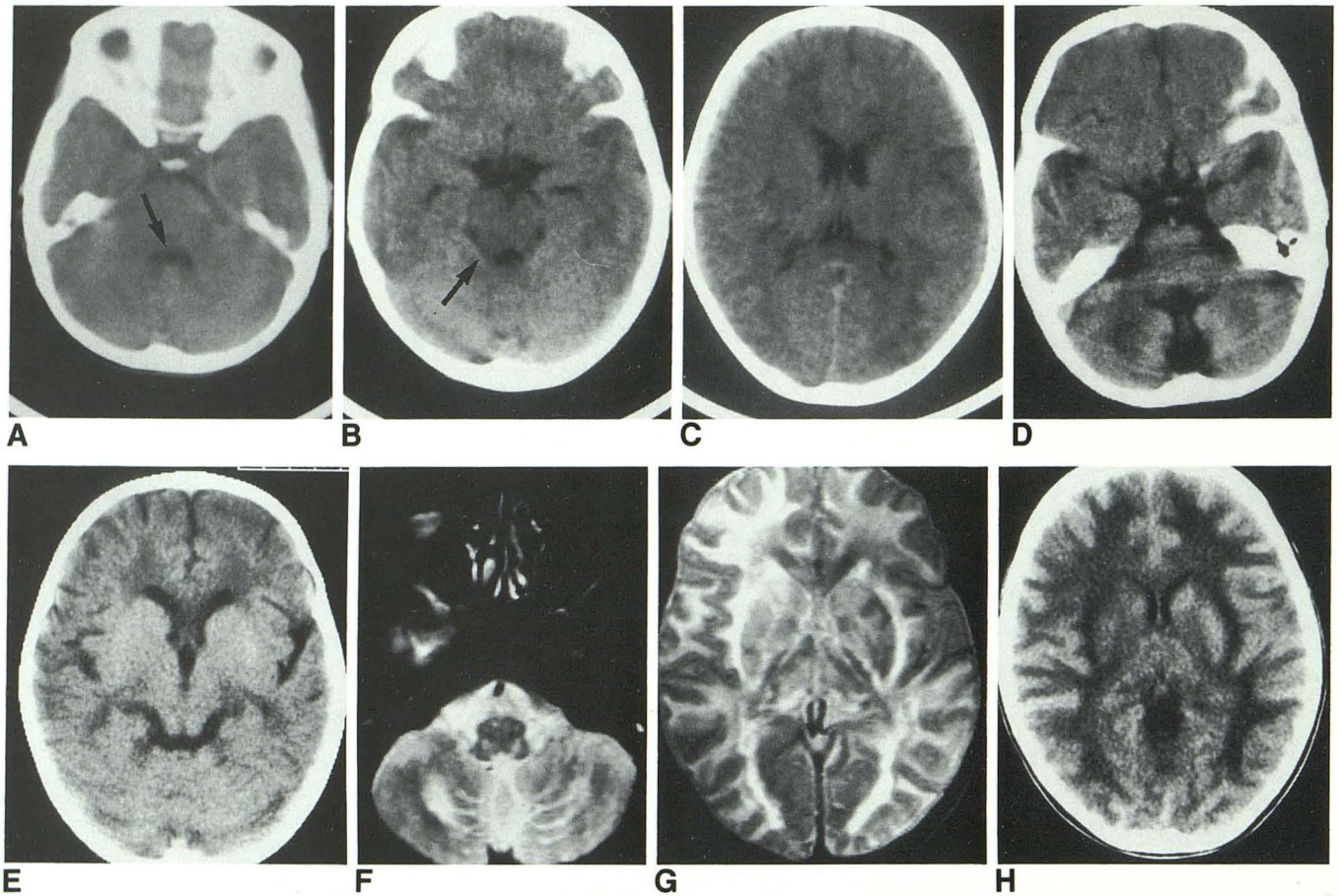


Fig. 2. Case 5, 5-year-old girl with PAID; 1 year history of episodes of relapsing neurologic symptoms leaving sequelae. A, B, and C, CT at an outside hospital shows swollen brain stem and pons with deformity of 4th ventricle and quadrigeminal cistern (arrows) and irregular supratentorial white matter low density. D and E, CT 6 weeks later shows atrophic changes and white matter low density both supra- and infratentorially. F and G, MR (T2-weighted), and H, CT after another 6 and 7 months, respectively, show severe generalized white matter disease. Note that ventricles and sulci are no longer prominent.

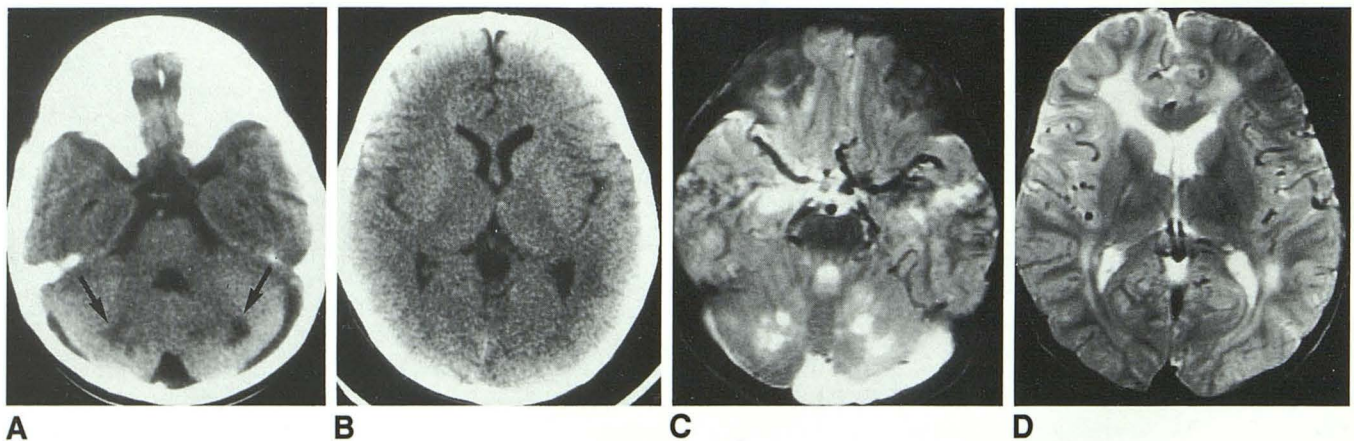


Fig. 3. Case 4, 17-month-old boy with PAID; neurologically normal, examined because of fair complexion and family history. A and B, Initial CT is normal except for low density lesions in cerebellar hemispheres (arrows). C and D, MR (T2-weighted) 1 month later shows generalized white matter changes, sparing the peripheral subcortical white matter.

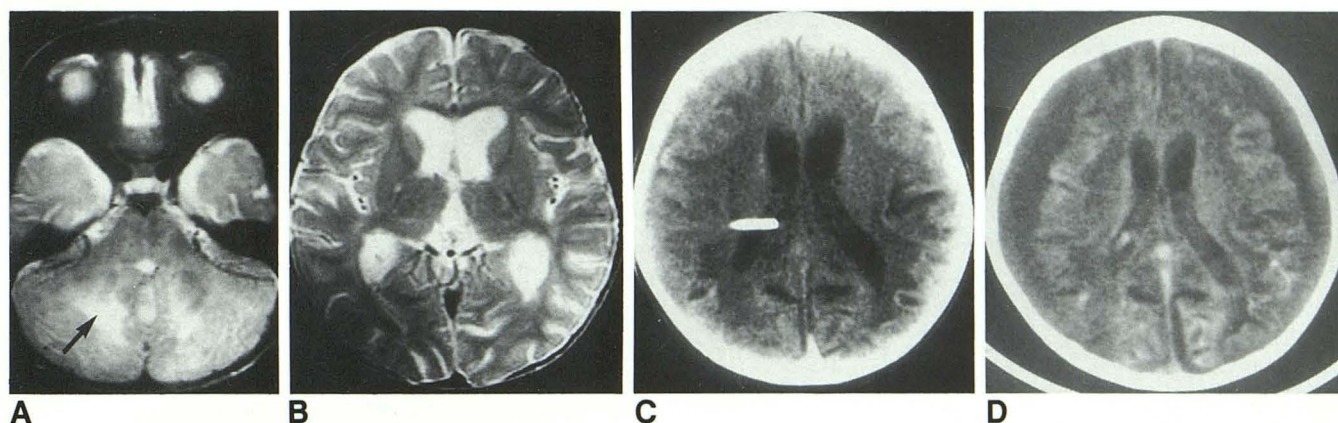


Fig. 4. Case 2, 16-month-old girl with PAID; 1 month history of attacks of myoclonic fits with unconsciousness
 A and B, Initial MR (T2-weighted) shows widened sulci and ventricles and extensive white matter changes in the posterior fossa (arrow).

C, Follow-up CT after 7 weeks shows marked generalized white matter disease.
 D, After another 2 weeks marked loss of brain tissue.

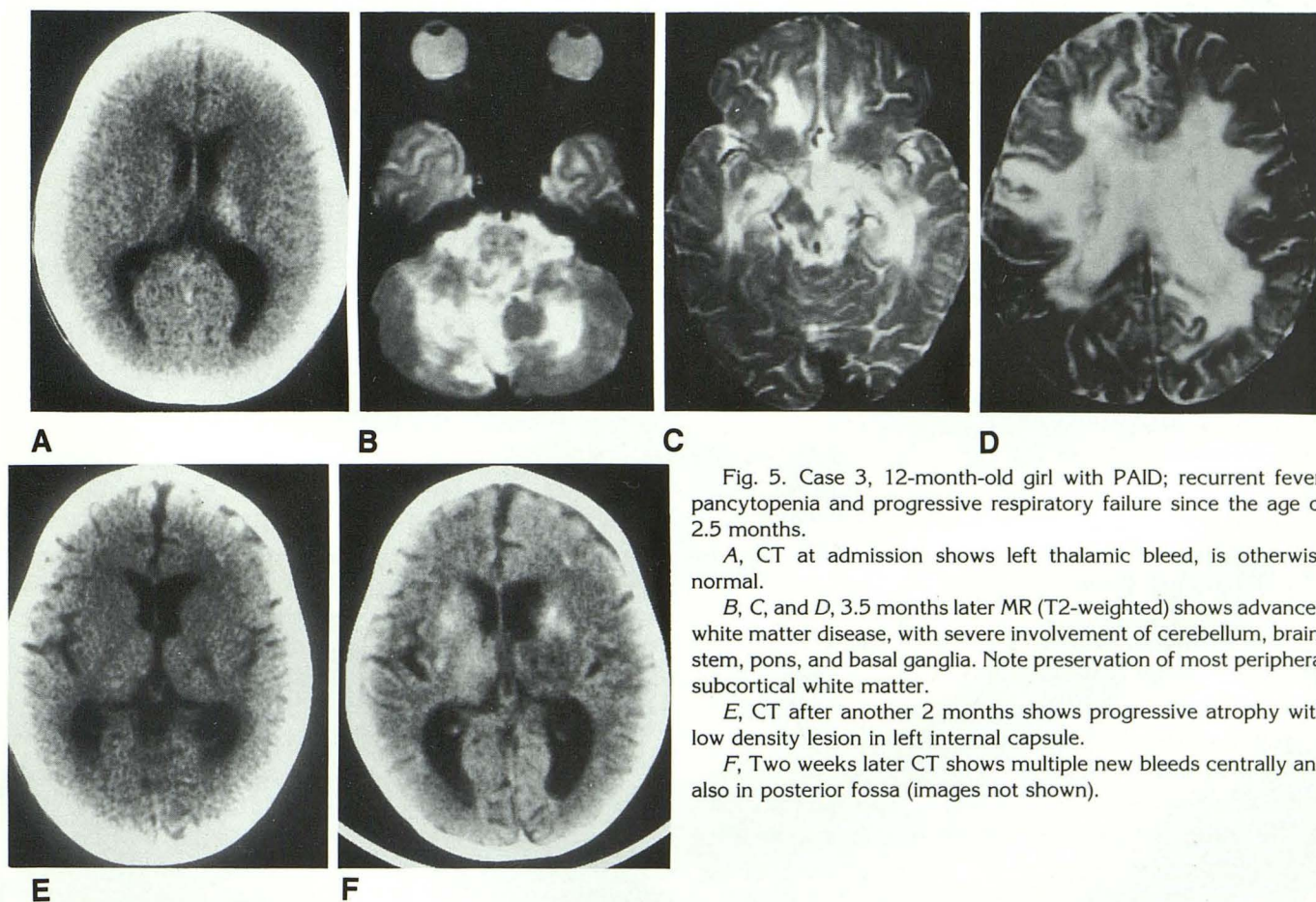


Fig. 5. Case 3, 12-month-old girl with PAID; recurrent fever, pancytopenia and progressive respiratory failure since the age of 2.5 months.

A, CT at admission shows left thalamic bleed, is otherwise normal.

B, C, and D, 3.5 months later MR (T2-weighted) shows advanced white matter disease, with severe involvement of cerebellum, brainstem, pons, and basal ganglia. Note preservation of most peripheral subcortical white matter.

E, CT after another 2 months shows progressive atrophy with low density lesion in left internal capsule.

F, Two weeks later CT shows multiple new bleeds centrally and also in posterior fossa (images not shown).

seen at MR (Figs. 3C and 3D). However, the apparent progression in this patient may be due to differences in imaging modality, since a repeat

CT 4 weeks later was essentially unchanged from the initial CT study; no further studies have been performed.

The findings in our patients indicate a pattern of development of white matter disease, that is progressive from predominantly posterior fossa involvement, to involvement of the periventricular white matter and finally to severe generalized white matter disease associated with marked loss of brain tissue. While slight to moderate prominence of ventricles and sulci was initially present in three of the children (cases 1, 2, and 3), marked loss of brain substance was found in all three patients followed for more than 2 months.

Initially, it could not be established whether the thalamic hyperdensity present on the first CT in case 3 (Fig. 5A), was due to a bleed or to thalamic calcifications secondary to hypoxia. A follow-up CT 5 months later (Fig. 5E) showed a thalamic low density lesion in the same location indicating the cause to be a hemorrhage. Furthermore, multiple new high density lesions indicating additional hemorrhages were shown at a repeat CT another 2 weeks later (Fig. 5F).

Discussion

The genetic defect causing the PAID syndrome is unknown, but from the clinical and family study of our patients, the mode of inheritance seems to be autosomal recessive. All the cases reported so far have been of Arab origin. This may partly be due to the fact that a fair complexion and ash-blond hair is more readily diagnosed as abnormal in a population where dark hair and a darker complexion is the rule.

None of the previously reported two cases (1) had documented central nervous system (CNS) disease. Vici et al (3) recently described two brothers with hypopigmentation of skin and hair, and immunodeficiency. Unlike our patients, these boys also had agenesis of the corpus callosum and severe mental retardation in association with other anomalies. The Chédiak-Higashi syndrome (2, 4) combines central and peripheral neurologic disease, partial albinism, and immunodeficiency. A major difference between the PAID syndrome and the Chédiak-Higashi syndrome is the presence of giant lysosomal granules in all leukocytes in the latter disease, a feature not found in the PAID syndrome.

The association of CNS disease with immunodeficiency also occurs in ataxia telangiectasia (5). In this disease premature graying of the hair also is frequent (6); this feature has been considered related to vitiligo (7). Ataxia telangiectasia usually presents when the child starts to walk; at this point gait and all truncal movements are ataxic.

Ataxia has not been present in any of the PAID patients.

The association, as observed in our patients, between multiple immunodeficiencies, partial albinism, and CNS changes is not yet clear. The immunodeficiency and the pigment changes are both present at birth and may be caused by a genetic defect involving the embryonic development of the immune system as well as of the melanocytes. The CNS changes, however, develop later as a progressive demyelination with eventual loss of brain tissue. Demyelination is seen in many inherited neurometabolic disorders. The myelin might have been defective from the beginning, or may have been destroyed by toxic metabolites caused by a metabolic block.

However, demyelination is also a common finding in different CNS infections, also of slow virus type (8). Subacute sclerosing panencephalitis (9), radiologically manifesting as white matter disease, is caused by an altered host response to remaining measles virus in children who typically had a measles infection before 2 years of age. Progressive multifocal leucoencephalopathy (10) is caused by an opportunistic infection by the commonly occurring papovavirus, usually in patients with reduced host resistance. Many similar diseases are known to affect animals (8). Recently, changes of skin and hair pigmentation have also been observed associated with acquired immunodeficiency and demyelinating CNS disease in AIDS patients (7).

In all these conditions, it is difficult to differentiate between the damage caused by the virus and that due to an antiviral or possibly autoimmune response. In our immunodeficient patients with PAID, it is possible that the demyelination might be secondary to some opportunistic low-virulent infection. The results from the neuroimaging in our patients suggests that the PAID syndrome radiologically has several different stages. In the initial stage (case 5), diffuse white matter disease was seen supratentorially; in addition, the brain stem was swollen (Figs. 2A–2C). This could be consistent with an acute infectious episode. After that, a quiescent stage follows that may last for many months (cases 4 and 5; Figs. 3, 2D, and 2E). A stage of acute white matter swelling may then occur (case 5; Figs. 2F and 2G)—perhaps triggered by a repeat infection—followed by a loss of white matter (cases 1, 2, and 5; Figs. 1, 4C, and 4D).

The posterior fossa white matter changes in our patients with PAID were more prominent than what we have seen in other neurometabolic dis-

orders. PAID syndrome should be considered when white matter changes are seen predominantly in the cerebellar hemispheres, and also in young children who demonstrate rapidly progressive white matter disease.

References

1. Griscelli C, Durandy A, Guy-Grand D, Daguillard F, Herzog C, Prunieras M. A syndrome associating partial albinism and immunodeficiency. *Am J Med* 1978;65:691-702
2. Wolff SM, Dale DC, Clark RA, Root RK, Kimball HR. The Chédiak-Higashi syndrome: studies of host defenses. A NIH conference. *Ann Intern Med* 1972;76:293-306
3. Vici CD, Sabetta G, Gambarara M, et al. Agenesis of the corpus callosum, combined immunodeficiency, bilateral cataract, and hypopigmentation in two brothers. *Am J Med Genet* 1988;29:1-8
4. Blüme RS, Wolff SM. The Chédiak-Higashi syndrome: studies in four patients and a review of the literature. *Medicine (Baltimore)* 1972;51:247-280
5. Waldmann TA. Immunological abnormalities in ataxia-telangiectasia. In: Bridges BA, Harnden DG, eds. *Ataxia-telangiectasia: a cellular and molecular link between cancer, neuropathology, and immune deficiency*. Chichester, England: John Wiley & Sons, 1982:37-51
6. McFarlin DE, Strober W, Waldmann TA. Ataxia-telangiectasia. *Medicine (Baltimore)* 1972;51:281-314
7. Duvic M, Rapini R, Hoots WK, Mansell PW. Human immunodeficiency virus-associated vitiligo: expression of autoimmunity with immunodeficiency. *J Am Acad Dermatol* 1987;17:656-662
8. Wege H, Dörries R, Massa P, Watanabe R. Autoimmunity and immune pathological aspects of viral disease. In: Cohen IR, ed. *Perspectives on autoimmunity*. Boca Raton, FL: CRC Press, 1988: 111-133
9. Graves MC. Subacute sclerosing panencephalitis. *Neurol Clin* 1984;2:267-280
10. Brooks BR, Walker DL. Progressive multifocal leucoencephalopathy. *Neurol Clin* 1984;2:299-314