

Are your **MRI contrast agents** cost-effective?

Learn more about generic **Gadolinium-Based Contrast Agents**.



FRESENIUS
KABI

caring for life

AJNR

**Lysosomes, peroxisomes and mitochondria:
function and disorder.**

L E Becker

AJNR Am J Neuroradiol 1992, 13 (2) 609-620

<http://www.ajnr.org/content/13/2/609.citation>

This information is current as
of April 18, 2024.

Lysosomes, Peroxisomes and Mitochondria: Function and Disorder

Laurence E. Becker¹

From the Department of Pathology (Neuropathology), University of Toronto and The Hospital for Sick Children, Toronto, Ontario, Canada

Enzyme defects localized to lysosomes, mitochondria, and peroxisomes produce significant neurologic disease. Diseases affecting primarily gray matter are largely due to enzyme defects of lysosomes producing disruption of catabolic pathways and storage within neurons of lipid, carbohydrate, mucopolysaccharide, or glycogen. The degree of metabolic product accumulation, the specificity of cell type, anatomic localization of neuronal involvement, and maturation level of the brain determine the nature of the neuropathology. From this heterogeneous group, specific diseases have been selected to illustrate characteristic patterns of pathology. Metabolic diseases affecting primarily white matter are the leukodystrophies. The metabolically defined leukodystrophies now include metachromatic leukodystrophy, Krabbe disease, adrenoleukodystrophy (ALD), Canavan disease, and Pelizaeus-Merzbacher disease. However, other leukodystrophies are also included in the differential diagnosis: Alexander disease, Cockayne syndrome, sudanophilic leukodystrophy. Metabolic disorders that affect gray and white matter to approximately the same extent include diseases whose enzymatic defects have been localized to mitochondria or peroxisomes. Apart from Leigh encephalopathy and focal cerebral ischemic lesions, the patterns of pathology associated with disorders of mitochondrial enzymes have not been established with a significant degree of certainty due to the evolving understanding of the molecular biology of these conditions. Similarly, many peroxisomal

disorders require further biochemical clarification. Neonatal ALD and Zellweger syndrome are examples of well-defined diseases produced by peroxisomal enzyme defects. Many other metabolic diseases are associated with neurological manifestations without evidence of abnormal neuroimaging or gross neuropathology. The emphasis of this chapter is on patterns of pathology in the metabolically better defined diseases in order to provide the basis for correlation with neuroimaging.

Introduction

The spectrum of disorders caused by a metabolic abnormality is wide (1, 2). Most inherited metabolic diseases are related to enzyme defects within lysosomes, but recent advances emphasize abnormalities of mitochondria and peroxisomes. Understanding the role that organelle pathology plays in the pathogenesis of muscle, nerve, neuron, oligodendroglia, or astrocyte disturbance is essential for the elucidation of metabolic disorders (1). Abnormality of organelles leads to cellular dysfunction and organ failure. It is the abnormal organ that imaging modalities can identify. In the brain, patterns of pathology can be recognized, but these patterns are complicated by the differing stages of the disease and the age of the child. In broad general terms, four patterns of pathologic involvement emerge: involvement primarily of gray matter, involvement primarily of white matter, involvement of both gray and white matter, and no recognizable involvement of either gray or white matter (no recognizable gross neuropathology).

¹ Address reprint requests to Dr L. E. Becker, Department of Pathology, The Hospital for Sick Children, 555 University Avenue, Toronto, Ontario, Canada M5G 1X8.

Metabolic Diseases Affecting Primarily Gray Matter

Those disorders that primarily affect gray matter are largely due to lysosomal enzyme defects. Lysosomal enzymes are synthesized in the cytoplasm and transported into the cisternae of the endoplasmic reticulum where they are packaged into primary lysosomes by the Golgi apparatus. Fusion with autophagic vacuoles creates secondary lysosomes where the enzymes (hydrolases) degrade the contents of the autophagic vacuoles (1). The lysosomes are the garbage disposals of the cell. In lysosomal storage diseases, there are deficiencies of specific catabolic enzymes that result in the accumulation of undigested material (Table 1). This product, usually lipid, carbohydrate, or mucopolysaccharide, interferes with cell function resulting in the eventual death of these abnormal cells. The affected organs or cell types within them will be disturbed by the disruption of specific metabolic pathways characteristic of the target cells. The gross manifestation of these metabolic abnormalities will depend on the cells affected. Most often the brain becomes atrophic with disorders of lysosomal function.

TABLE 1: Lysosomal disorders

Storage diseases
Lipidoses
Gaucher disease
Niemann-Pick disease
Fabry disease
GM ₁ Gangliosidosis
GM ₂ Gangliosidosis (Tay-Sachs)
Neuronal ceroid lipofuscinosis
Haltia Santavouri disease
Jansky-Bielschowsky disease
Batten disease
Mucopolysaccharidoses
I Hurler/Scheie (formerly V)
II Hunter
III Sanfilippo
IV Morquio
VI Maroteaux-Lamy
VII Sly
Mucopolipidoses
I-IV Mucopolipidoses
Mannosidosis
Fucosidosis
Glycogenoses
II Pompe disease
Leukodystrophies
Metachromatic leukodystrophy
Krabbe leukodystrophy

Lipidoses

The lipid storage diseases are rare. Some have an identified enzyme defect, such as absence of hexosaminidase in Tay-Sachs disease, and others have no detectable enzyme defect, such as the group of neuronal ceroid lipofuscinosis. In Tay Sachs disease for example, GM₂ ganglioside accumulates in neurons without demonstrable selectivity for any particular group of neurons. In the early stages of Tay Sachs, there may be megalencephaly (3) due to ganglioside storage. As the ganglioside interferes with intracellular function, the neurons begin to crumble (4). The consequence of neuronal deterioration and death is cortical atrophy with widened sulci, narrowed gyri, and dilated ventricles. The optic nerves and cerebellum are also atrophic, since part of the neuronal death is axonal deterioration and secondary demyelination. Secondary demyelination may be prominent and can be confused with diseases that produce primary demyelination, such as the leukodystrophies.

Most of the lipidoses are diagnosed by enzymatic assay in white blood cells. The group of ceroid lipofuscinosis, of which Batten disease is one example, cannot be diagnosed enzymatically. Diagnosis is based, instead, on electron microscopic identification of characteristic curvilinear or fingerprint inclusions found in white blood cells, or skin, or conjunctival biopsy (5). In Batten disease, brain atrophy may be present but it is mild and white matter changes are absent. Batten disease is a progressive childhood disorder occurring between 5 and 10 years of age, associated with blindness followed by mental deterioration, dysarthria, seizures, and myoclonus.

Mucopolysaccharidoses

The accumulation of mucopolysaccharides (glycosaminoglycans) due to specific enzyme defects in their catabolism produces six well-recognized syndromes (Table 1) that are described in detail in textbooks of neuropathology (2). The enzymatic defects are related to failure to breakdown dermatan sulfate, heparan sulfate, or keratan sulfate. Although varying widely in severity, characteristic features are coarse facial appearance (gargoylism), some degree of skeletal manifestation (dysostosis multiplex), and multiple organ involvement. All the disorders except Morquio have dysostosis multiplex. Short stature is present in all except Scheie syndrome.

Hurler syndrome is the prototypical mucopolysaccharide storage disease in which there is a severe progression of disease leading to death by about 10 years of age. The children have short necks, progressive kyphosis, protuberant abdomens, hepatosplenomegaly, and umbilical and inguinal hernias. Mental retardation is a prominent feature of Hurler syndrome. Gross examination of the brain of such a patient reveals boggy, fluid-filled, opaque, and thickened meninges covering an atrophic cerebrum. The dura surrounding the brain may also be thickened to as much as 5 mm. On coronal sectioning, the ventricles are large (Figs. 1A and 1B). The perivascular spaces are grossly enlarged by accumulation of mucopolysaccharide-containing histiocytes surrounding the blood vessels, particularly in the centrum semiovale. In Hurler disease, cortical and cerebellar neurons are strikingly ballooned with lesser involvement of neurons in the brain stem. Electron microscopic studies show large intralysosomal accumulations of ganglioside, but little recognizable mucopolysaccharide. The lysosomal α -L-iduronidase deficiency produces mucopolysaccharide storage that interferes with ganglioside catabolism, resulting in prominent lipid accumulation within neurons (6). These neurons eventually degenerate, so brain atrophy becomes apparent.

Mucopolipidoses

The mucopolipidoses are a group of disorders that are associated with accumulation of both mucopolysaccharide and lipids within lysosomes as a result of a single enzyme defect affecting both catabolic pathways. This situation is different from that in mucopolysaccharidoses, where the accumulating mucopolysaccharide interferes

with lipid breakdown. Examples of the mucopolipidoses include I cell disease, fucosidosis, and mannosidosis. The brain in these disorders is grossly normal (2).

Glycogen Storage Disease

This is a heterogeneous group of disorders associated with deficiencies of enzymes involved in glycogen storage, synthesis, and degradation. Patients with glycogen storage disease can present with dysfunction of the liver, heart, muscle, or nervous system. Pompe disease is one glycogen storage disease that affects both the central nervous system (CNS) and muscle (2). Several forms of Pompe disease occur at different ages. The classic infantile form is associated with hypotonia, macroglossia, cardiomegaly, cardiac failure, and death by 1 year of age. In this form, the brain may be grossly normal, although, histologically, the neurons are markedly distended by accumulation of glycogen within lysosomes. Glycogen is present in many different types of neurons but is most prominent in the dorsal root ganglia, anterior horn cells, and motor nuclei of the brain stem. In later stages of Pompe disease, mild cortical atrophy may be discernible.

"Hypoxic-Ischemic" Encephalopathy

Particular metabolic disorders, such as those associated with defects of enzymes in the urea cycle and those producing metabolic acidosis and hypoglycemia, may be associated with a pattern of hypoxic-ischemic encephalopathy with extensive neuronal loss and astrogliosis manifesting as cortical atrophy.

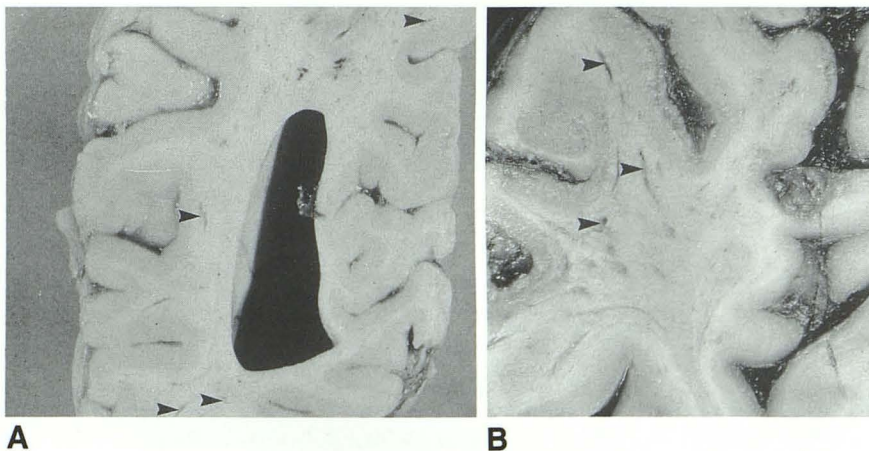


Fig. 1. Hurler disease; coronal views of specimen. Mucopolysaccharide deposition significantly enlarges the Virchow-Robin spaces. A, occipital, mild; B, frontal, severe.

Metabolic Diseases Affecting Primarily White Matter (Leukodystrophies)

Traditionally, diseases affecting white matter have been divided into the categories of myelinoclastic and dysmyelinating (7). In myelinoclastic diseases, the myelin sheath is intrinsically normal until it later succumbs to endogenous or exogenous myelinotoxic factors. Viral demyelinating diseases include subacute sclerosing panencephalitis (measles), subacute sclerosing rubella panencephalitis, progressive multifocal leukoencephalopathy (papova), and demyelination associated with HIV infection. Postinfectious demyelination, methotrexate/irradiation-induced demyelination, and multiple sclerosis also belong to the myelinoclastic category.

From a metabolic perspective, the interest is in dysmyelinating diseases where an intrinsic (inherited) enzyme deficiency results in disturbed formation, destruction, or turnover of essential components of myelin. Not discussed in this presentation are metabolic diseases with focal demyelination: cerebrotendinous xanthomatosis, Bassen-Kornzweig syndrome, and aminoacidurias (maple syrup urine disease, phenylketonuria) (2).

In myelinoclastic demyelination, the pattern of damage lacks symmetry. The lesions are sharply demarcated, *irregularly involve subcortical arcuate or U fibers*, and tend to spare the cerebellar white matter. In contrast, in dysmyelination, the pattern of abnormal myelination is symmetrical in both hemispheres, tends to have diffuse margins, *sparing the U fibers*, and consistently involves the cerebellar white matter.

The leukodystrophies are a heterogeneous group of diseases that have in common extensive degenerative changes within CNS white matter. They are sometimes referred to as dysmyelinating disorders (Table 2). As biochemical abnormalities are identified, the leukodystrophies become more accurately classified. Those disorders with defined biochemical abnormalities include metachromatic leukodystrophy, Krabbe disease, ALD, Canavan disease, and Pelizaeus-Merzbacher disease. Dysmyelination disorders in which the enzyme defects have not been determined are characterized largely by clinico-pathologic observations, ie, Alexander disease, Cockayne disease, and sudanophilic leukodystrophy.

Metachromatic Leukodystrophy

In metachromatic leukodystrophy, the pattern of demyelination is a classical symmetrical pat-

tern with sparing of U fibers (Fig. 2), diffuse margins, and involvement of the cerebellum.

Metachromatic leukodystrophy is associated with a deficiency of arylsulfatase-A. Defects of this catabolic enzyme result in failure of the myelin to be properly broken down and reutilized, resulting in accumulation of ceramide sulfatide. Disorders of arylsulfatase-A deficiency have been classified on the basis of clinical manifestations into late infantile, juvenile, and adult groups.

The most common is the late infantile form that presents between 1 and 2 years of age with motor signs of peripheral neuropathy followed by deterioration in intellect, speech, and coordination. Within 2 years of onset, there is evidence of severe white matter dysfunction: quadriplegia, blindness, and decerebrate posturing. The brain tends to be atrophic and the ventricles dilated. The white matter takes on a dull, chalky, white

TABLE 2: Leukodystrophies

Name	Distinguishing Gross Characteristics
Metachromatic LD	
Krabbe disease	Fine calcification of basal ganglia
Adrenal LD	Severe loss of myelin Occipital then frontal involvement
Alexander disease	Large brain Frontal then occipital involvement Periventricular contrast enhancement
Canavan disease	Large brain Subcortical arcuate fibers selectively involved
Pelizaeus-Merzbacher LD	Leopard skin demyelination
Cockayne syndrome	Leopard skin demyelination Large deposits of calcium, basal ganglia and centrum ovale
Sudanophilic LD	
Others	

Note.—LD = leukodystrophy.

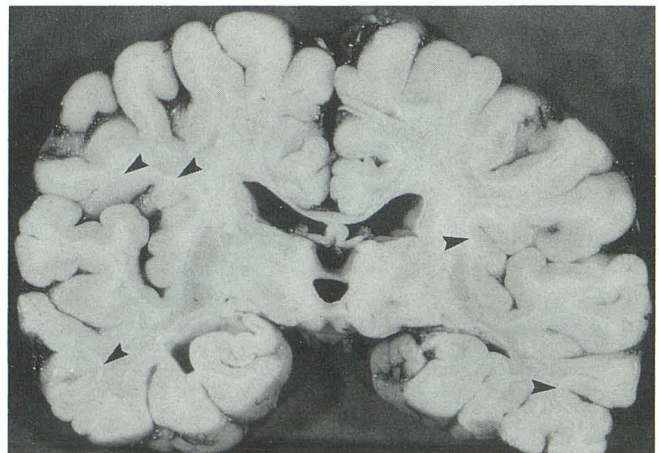


Fig. 2. Metachromatic leukodystrophy. Coronal section with symmetrical demyelination and sparing of U fibers.

to gray color. The cerebellum is often small and firm with atrophy of the folia.

Histologically, axonal damage and loss are usually severe in demyelinated areas. Astrogliosis is prominent in areas of demyelination. Within the white matter are numerous granular bodies that are clearly metachromatic and represent the accumulation of the sulfatide. In the juvenile and adult forms, the metachromatic sulfatide also accumulates within neurons, producing both demyelination and modest neuronal storage (8).

Krabbe Disease

The pattern of demyelination in Krabbe disease is one of classic dysmyelination (Fig. 3).

Clinical onset in Krabbe disease is early, between 3 and 5 months of age, usually associated with intermittent fevers, seizures, feeding problems, hyperirritability, and, eventually, psychomotor regression. Death usually occurs by 2 years of age. Finely stippled deposits of calcium are present in the basal ganglia and can be demonstrated by computed tomography (CT) (9). The defect in Krabbe disease is a deficiency of lysosomal galactosylceramidase I (10).

In affected patients, the brain is small with evidence of cerebral atrophy. The sectioned cerebrum has the typical appearance of leukodystrophy with discoloration of the centrum ovale and corona radiata and preservation of the subcortical arcuate fibers. The ventricles are dilated.

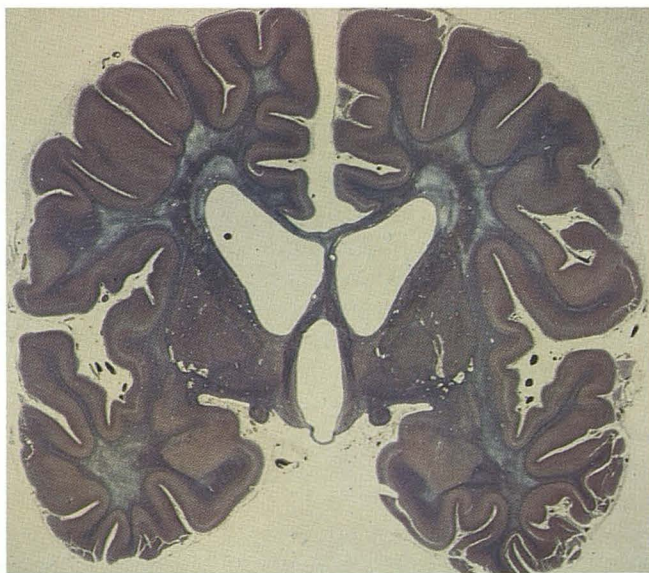


Fig. 3. Krabbe disease. Coronal section with symmetrical demyelination indicated by diminished blue staining. The ventricles are dilated. (Phosphotungstic acid hematoxylin, $\times 1$).

In severely affected areas, the white matter may be a fibrous mesh with occasional small cystic areas. The cerebellar white matter is also affected, but to a lesser degree.

The histologic features are typical, showing a prominent loss of myelin with astrogliosis, and the diagnostic accumulation of clusters of globoid and epithelioid cells present throughout the areas of demyelination.

Adrenoleukodystrophy

The pattern of demyelination in classical ALD is similar to metachromatic and Krabbe leukodystrophy, except that the demyelination is more severe with early and prominent occipital involvement (Figs. 4A and 4B). ALD is inherited as an X-linked condition and manifests in four clinical forms (11): classical ALD, adrenomyeloneuropathy, neonatal ALD, and symptomatic heterozygotes. Because of confusion and inappropriate application of the term Schilder disease, it is best avoided (1). In classical ALD, symptoms usually begin in the first decade of life. The course is somewhat prolonged with death occurring between 1 and 9 years after onset. Relapsing and remitting courses have been reported. Behavioral disturbances are the most frequent initial presentation, leading to seizures, visual loss, corticospinal tract involvement, and, eventually, spastic quadraparesis. The biochemical abnormality is the accumulation of very long chain fatty acids that are normally degraded in peroxisomes (12, 13).

At autopsy, there is usually evidence of cerebral atrophy and ventricular dilatation. However, the cerebral cortex is normal and the abnormalities are restricted to white matter. In the early phases of the disease, the changes are most severe in the occipital regions. As the disease progresses, the demyelination moves from the occipital to the parietal and posterior temporal lobes. These regions are firm and appear gelatinous and brown in the unfixed state. The demyelination is extensive and very complete compared to some of the other leukodystrophies where there are some small areas of myelin preservation. The demyelination tends to be symmetrical posteriorly but is asymmetrical in the frontal lobes. Secondary degeneration of the corticospinal tracts causes a gray, shrunken appearance of the posterior limb of the internal capsule, the cerebral peduncles, pons, and pyramids. The cerebellar white matter is involved.

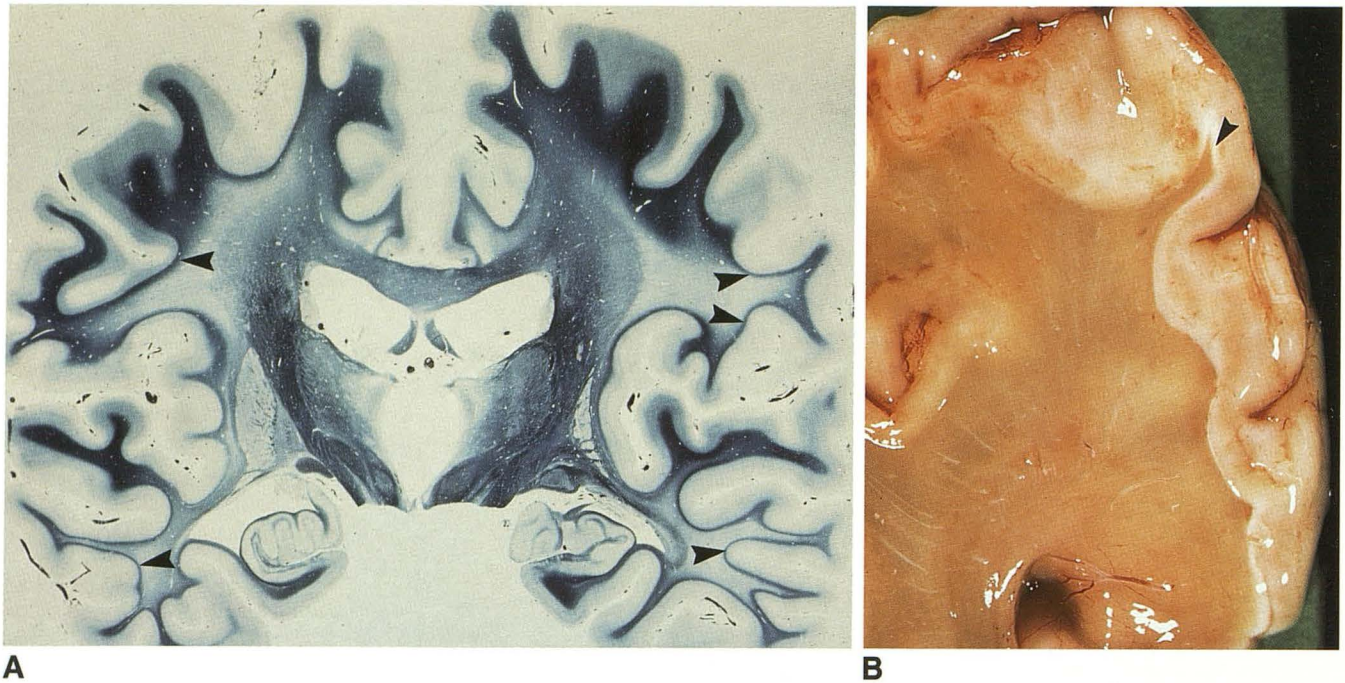


Fig. 4. Classical ALD. A, Coronal section with demyelination (decreased blue staining) and preservation of U fibers (arrowheads). B, Unfixed coronal section of the occipital lobe with extensive demyelination and incomplete preservation of U fibers (arrowhead). (Loyez, X1).

Histologically, the cortex is normal. The changes are confined to white matter, which shows a complete loss of myelin, extensive astrogliosis, and preservation of subcortical white matter. In ALD, there is also a prominent inflammatory reaction with accumulation of perivascular inflammatory cells.

Alexander Disease

Alexander disease is a rare disease reported in infants, juveniles, and adults. No enzyme defect has been identified in this disorder. In infants, there is psychomotor retardation and megalencephaly often associated with hydrocephalus, spasticity, and seizures.

At autopsy, the brain weight is increased and only on coronal sectioning is the soft, gray, often collapsed white matter apparent, especially in the frontal lobes (Fig. 5A). The cortex is usually white and firm. The lateral and third ventricles may be dilated. The outlines of the basal ganglia are sometimes indistinct but no gross abnormality of brain stem, cerebellum, or spinal cord is apparent.

Microscopically, the diagnostic feature is a massive deposition of Rosenthal fibers composed of dense intermediate glial fibrillary acidic protein filaments confined to the cytoplasm of astrocytes (14). The Rosenthal fibers accumulate around

blood vessels, beneath the pial surface, and around the ependymal lining of the ventricles (Fig. 5B). Accumulation of Rosenthal fibers around blood vessels may disrupt the blood-brain barrier, producing periventricular frontal enhancement on CT (15) (Figs. 5C and 5D). Disruption of the ependymal surface, particularly in the region of the aqueduct, leads to narrowing of the aqueduct and subsequent ventricular dilation.

Canavan Disease

Canavan disease, or spongy degeneration of the nervous system, is an autosomal recessive condition occurring in Jewish infants. Recently, Matalon (16) has described an aspartoacylase deficiency with *N*-acetyl aspartic aciduria in patients with Canavan disease. Typically, the onset is in the first 6 months of life and is characterized by apathy, loss of motor activity, and hypotonia.

Megalencephaly is conspicuous. The brain is heavier than normal. On coronal sections, the white matter is demyelinated, soft, gelatinous, and gray, with the texture of a wet sponge. In contrast to other leukodystrophies, the demyelination of Canavan disease preferentially involves the U fibers. The occipital lobes are more involved than the frontal and parietal lobes, which in turn are more affected than the temporal lobes. The

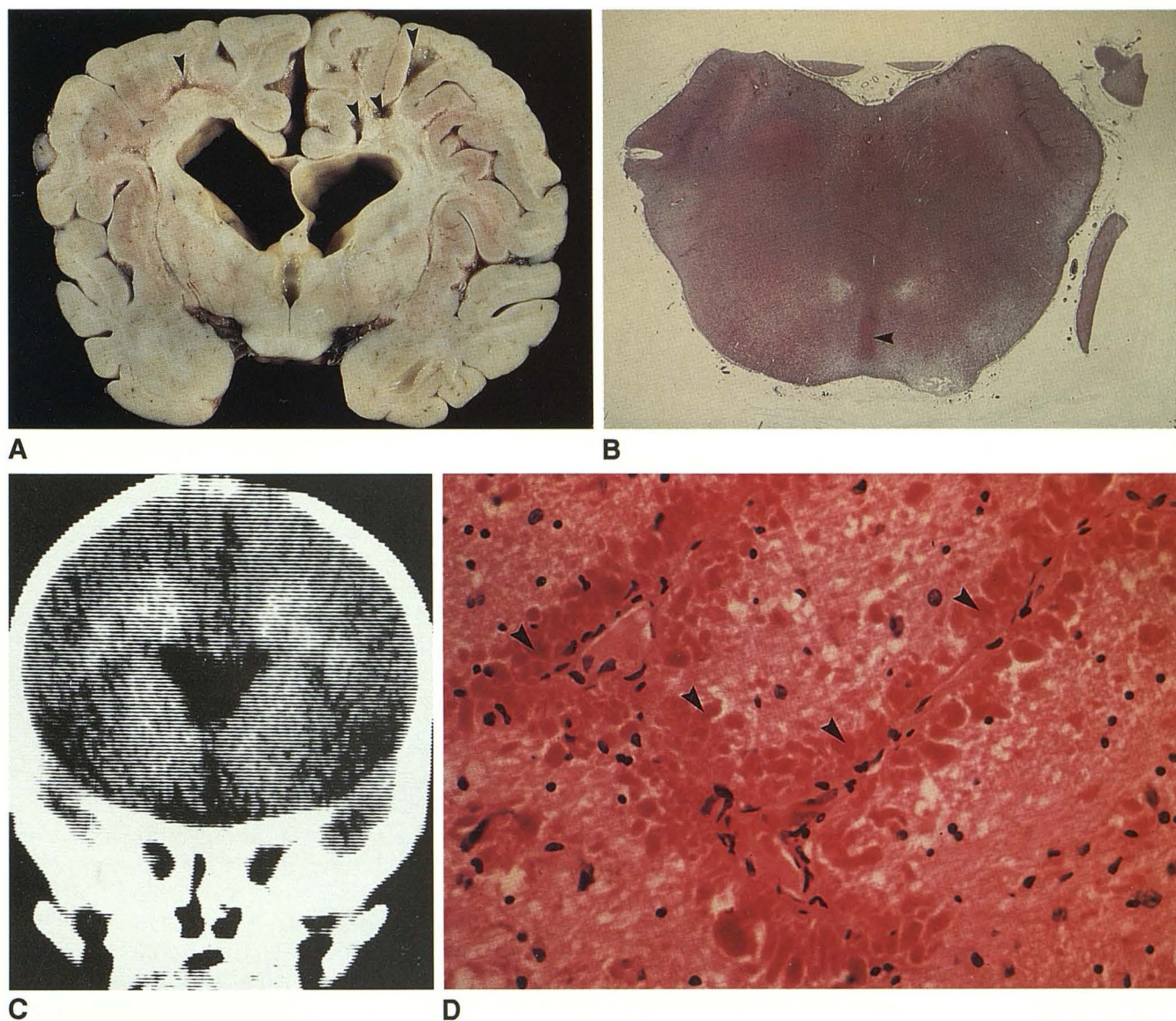


Fig. 5. Alexander disease. A, Coronal section with prominent demyelination and focal cavitation (*arrowheads*). B, Ventricles are dilated due to secondary aqueductal stenosis (*arrowhead*) from proliferation of Rosenthal fibers. C, CT with frontal periventricular enhancement. D, Accumulation of red Rosenthal fibers (*arrowheads*) around blood vessels. (Hematoxylin and eosin, $\times 640$).

globus pallidus tends to be severely affected with the brain stem and spinal cord less involved. The cerebellum is atrophic (17).

Microscopically, there is prominent spongy change with demyelination and proliferation of astrogliosis (Fig. 6). Alzheimer-type II astrocytes are present.

Pelizaeus-Merzbacher Disease

The classical form of Pelizaeus-Merzbacher disease becomes clinically manifest in the first decade of life. It is a slowly progressive X-linked recessive disorder that is characterized by nystag-

mus, intermittent shaking movements of the head, ataxia, choreoathetoid movements, and psychomotor retardation. Recently, Koeppen (18) found a severe deficiency of myelin lipids with a lack of proteolipid apoprotein (lipophilin). The genetic defect has been localized to the X chromosome (19).

The brain and cerebellum are atrophic with large ventricles, normal cortex, patchy demyelination, and variable astrogliosis. In the areas around blood vessels, the myelin tends to be better preserved, creating a "tigroid" or "leopard-skin" pattern of demyelination. Microscopically, there is evidence of demyelination with accumu-

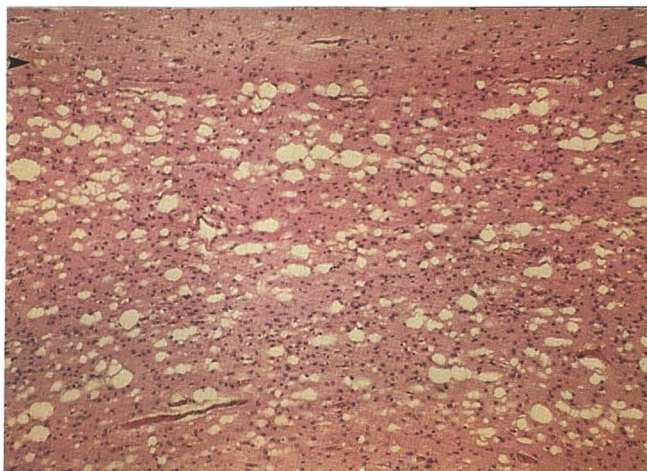


Fig. 6. Canavan disease. Prominent spongiosis of white matter involving the U fibers. The gray-white matter junction (arrowheads) is at the top. (Hematoxylin and eosin, $\times 400$).

lation of lipid-laden macrophages. Axons tends to be well preserved (2).

Cockayne Syndrome

Cockayne syndrome occurs in late infancy, has an autosomal recessive pattern of inheritance, and is associated with dwarfism, deafness, cataracts, retinal pigmentation, optic atrophy, thickened skull, and mental deficiency. No enzymatic defect has been discerned.

On neuropathologic examination, the brain is consistently small and the leptomeninges are diffusely thickened (20). The optic nerves are atrophic. Coronal section shows a gritty texture correlating with the extensive calcification, especially in the basal ganglia (Figs. 7A and 7B). The ventricular system may be moderately dilated, with an atrophic cortical mantle and reduced white matter. The cerebellum is also atrophic.

Microscopically, there is a "leopard skin" pattern of demyelination seen in the white matter (Fig. 7C) and there is cerebral calcification. In some areas, the calcification is in the vessel walls, whereas, in other areas, the calcification appears to be unrelated to blood vessels (2).

Sudanophilic Leukodystrophies

The term sudanophilic leukodystrophies applies to those leukodystrophies that cannot be classified in any other way radiologically, biochemically, or pathologically (2, 21). Pathologically, the pattern of demyelination is that of a dysmyelination process without evidence of dis-

tinguishing diagnostic features such as metachromatic substance seen in metachromatic leukodystrophy, epithelioid cells seen in Krabbe disease, Rosenthal fibers seen in Alexander disease, or spongy change seen in Canavan disease. As the biochemistry and molecular biology of these conditions becomes clarified, these conditions will be moved out of the group of sudanophilic leukodystrophies into a more specific and appropriate category.

Metabolic Disorders That Affect Gray and White Matter

Most metabolic disorders affect gray and white matter, although one may be more affected than the other. Those diseases where gray or white involvement is the predominant feature have already been discussed under those headings. In other conditions, gray and white matter are affected more equally. Disorders associated with defects of enzymes in mitochondria and peroxisomes best fit into this category. Not discussed are galactosemia, Menke disease, and Wilson disease, which also affect gray and white matter (2).

Mitochondrial Disorders

Mitochondria are membranous cytoplasmic organelles that are bounded by an outer membrane and lined by a folded inner membrane (cristae). Their number ranges from a few to several thousand in each cell. Because mitochondria in living cells move and change their shape, the form seen by electron microscopy is highly variable. Their core is filled with a finely granular matrix.

Mitochondria trap chemical energy that is released by the oxidation of amino acids, fatty acids, and glucose in a form, adenosine triphosphate (ATP), that is easily utilized by the cell. The major source of energy is glucose. Glycolytic enzymes break down glucose to form pyruvic acid which is then oxidized to acetyl coenzyme A. Further oxidations through the Krebs' tricarboxylic acid cycle (citric acid cycle) lead to the end products of carbon dioxide and water. Through the electron transfer system of cytochromes, the energy released is chemically fixed as ATP. The enzymes of the Krebs cycle and the cytochrome-electron transfer system are located in the mitochondria. The energy stored in ATP is later released by ATPases that lie in strategic locations throughout the cell, such as the cell membrane (22, 23).

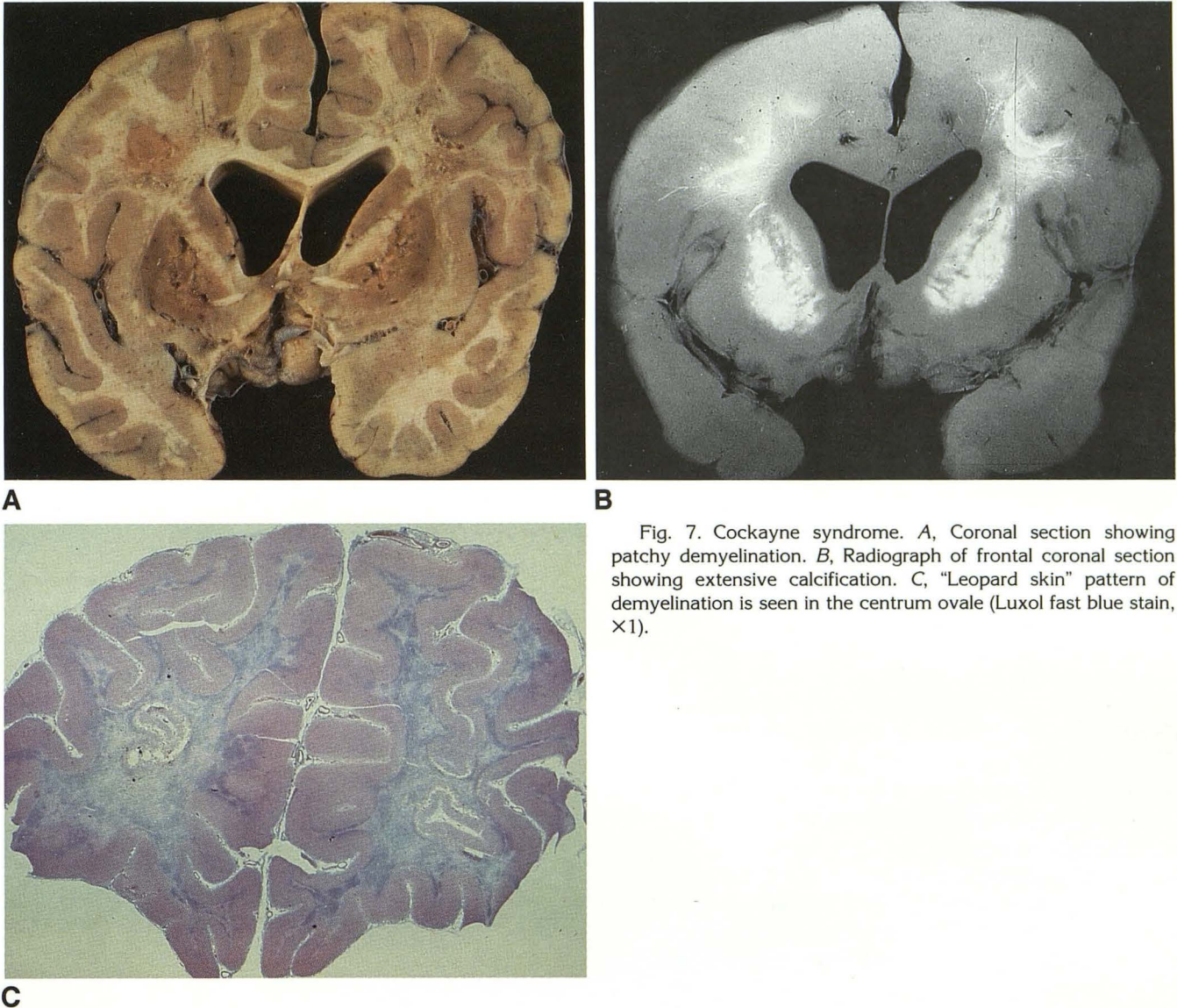


Fig. 7. Cockayne syndrome. *A*, Coronal section showing patchy demyelination. *B*, Radiograph of frontal coronal section showing extensive calcification. *C*, "Leopard skin" pattern of demyelination is seen in the centrum ovale (Luxol fast blue stain, $\times 1$).

Clinical demonstration of lactic acidosis usually focuses medical attention on the mitochondria. Although the spectrum of clinical presentations is wide (Table 3) and the degree of overlap is significant, three syndromes of mitochondrial dysfunction have emerged: myoclonic epilepsy with ragged-red fibers (MERRF), mitochondrial encephalopathy, lactic acidosis, and stroke-like syndromes (MELAS), and Kearns-Sayre syndrome (KSS). The recognition of mitochondrial diseases is relatively recent so that insight and understanding of this group of disorders is in a state of flux. Consistent reliable correlations between clinical syndromes, neuroimaging diagnoses, pathologic diagnoses, and biochemical determinations have not been firmly established.

Pathologically, the patterns of damage in the brain are related to cerebral infarction, often in the occipital lobes (MELAS), or to a more diffuse degenerative process occurring as an end stage of mitochondrial dysfunction called Leigh disease or subacute necrotizing encephalomyelopathy. Leigh disease is not caused by a single enzyme defect; it can occur as a result of a defect of almost any of the mitochondrial enzymes (2). Leigh disease is characterized pathologically by spongiosis, demyelination, astrogliosis, and capillary proliferation with consistent anatomical involvement of the midbrain (periaqueductal gray matter and substantia nigra), pons (tegmentum), and medulla (tegmentum, cranial nerve nuclei in the floor of the fourth ventricle and inferior olivary

TABLE 3: Selected mitochondrial encephalopathies^a

Manifestations	MERRF	MELAS	KSS
Muscle weakness	+	+	+
Dementia	+	+	+
Short stature	+	+	+
Deafness	+	+	+
Lactic acidosis	+	+	+
Ragged-red fibers	+	+	+
Spongy degeneration	+	+	+
Myoclonus	+	-	-
Seizures	+	+	-
Ataxia	+	-	+
Vomiting	-	+	-
Blindness	-	+	-
Hemiparesis	-	+	-
Ophthalmoplegia	-	-	+
Retinitis pigmentosa	-	-	+
Heart block	-	-	+
Elevated CSF protein	-	-	+

^a Adapted from Di Mauro et al (22).

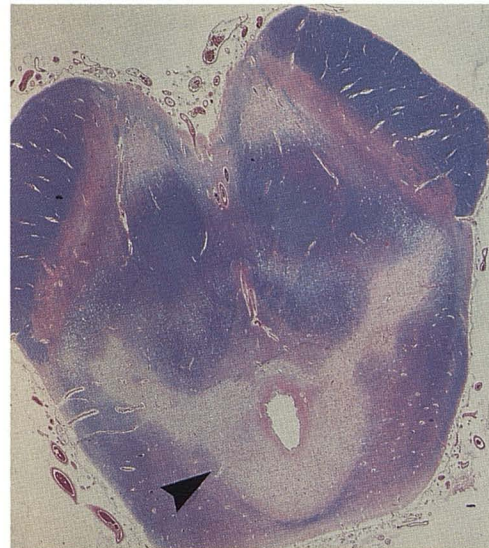
Note.—+ = present; - = absent; CSF = cerebrospinal fluid; for other abbreviations refer to text.

nuclei), cerebellum, basal ganglia, thalamus, and spinal cord (posterior columns) (Fig. 8A).

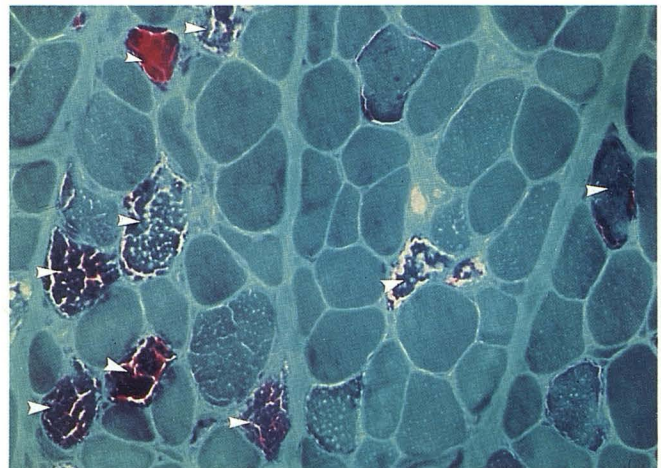
A diagnosis of mitochondrial disorder is most convincingly established by a combination of consistent clinical, radiologic, pathologic, biochemical, and molecular abnormalities. Since mitochondrial abnormalities are usually generalized, a muscle biopsy is one of the early steps in the diagnostic process (24). In a positive muscle biopsy, ragged-red fibers are demonstrated with a special stain: Gomori's modified trichrome (Fig. 8B). Electron microscopy has demonstrated a spectrum of mitochondrial abnormalities (Fig. 8C), with disturbances of mitochondrial number, size, shape, cristae patterns, and recognition of inclusions. The presence of morphologically abnormal mitochondria is an indication for extensive biochemical and molecular investigation aimed at defining the precise enzymatic defect, so that this group of conditions can be understood, enabling more effective treatment for the child.

Peroxisomal Disorders

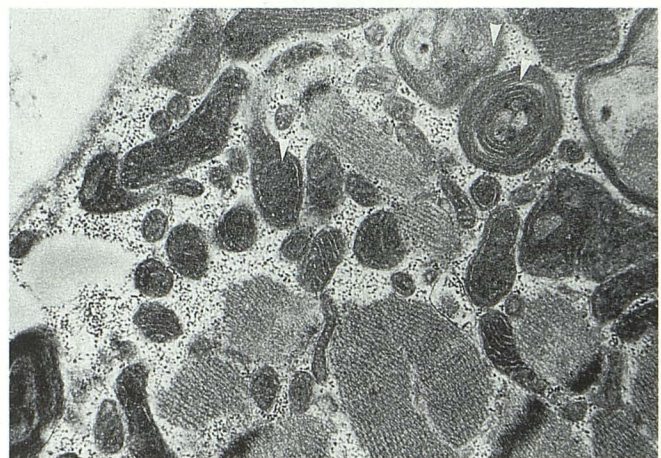
Enzyme deficiencies located in peroxisomes have assumed importance only recently (25). Morphologically, peroxisomes have been described as microbodies measuring 0.2–1.0 μm and limited by a single membrane filled with a homogeneous matrix. A peroxisome by definition



A



B



C

Fig. 8. Mitochondrial cytopathy. A, Periaqueductal demyelination (arrowhead) and spongiosis in Leigh disease. (Luxol fast blue, $\times 4$). B, Ragged-red fibers in muscle (arrowheads) (Gomori's modified trichrome, $\times 400$). C, Abnormal mitochondria (arrowheads). (Electron micrograph, $\times 34,000$).

contains a minimum of one oxidase to form hydrogen peroxide and one catalase to decompose it, but it may have more than 40 enzymes, the nature of which depend on the cell type. Only some of the enzymatic defects of peroxisomes are related to well-defined clinical disorders (Table 4). From a pathologic and neuroimaging point of view, both neonatal ALD and Zellweger syndrome are of interest. Other syndromes will become better defined as insights into enzymatic defects develop.

In neonatal ALD, the striking findings are in white matter, where there is severe and almost complete loss of myelin from the centrum semi-ovale. Neonatal ALD is similar to classical ALD in respect to the severity of demyelination and to the prominent involvement of the occipital lobes. Neonatal ALD is unlike classical ALD, in that it may show subtle polymicrogyric changes in the cortex (1).

In peroxisomal disorders such as Zellweger syndrome, there is an unusual combination of abnormalities: neuronal migration, suggesting an effect of peroxisomal enzyme dysfunction on brain maturation, and an active process of demyelination consistent with an ongoing dysfunction of peroxisomes.

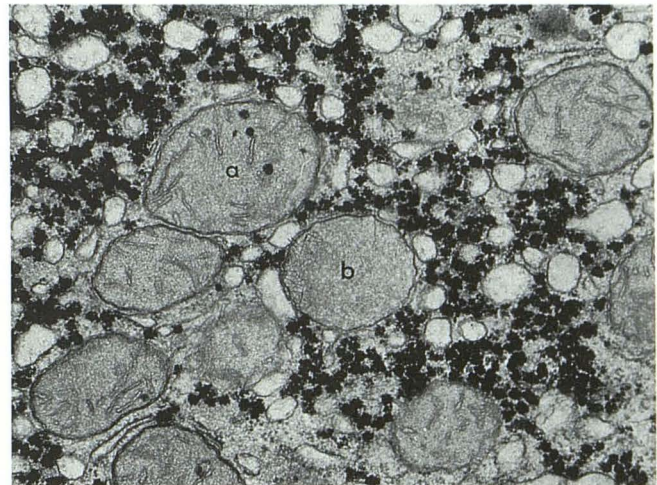
In Zellweger syndrome, the gray matter shows prominent polymicrogyria together with neuronal heterotopia, olivary dysplasia, and subependymal cysts (Fig. 9). The white matter shows mild demyelination and astrogliosis (26, 27). Other findings in Zellweger syndrome include dysmorphic facies (high forehead, low nasal bridge, epicanthal folds), ocular findings (cataract, optic atrophy, retinitis pigmentosa), and calcific stippling of the patella.

Metabolic Neurologic Diseases with No Gross Neuropathology

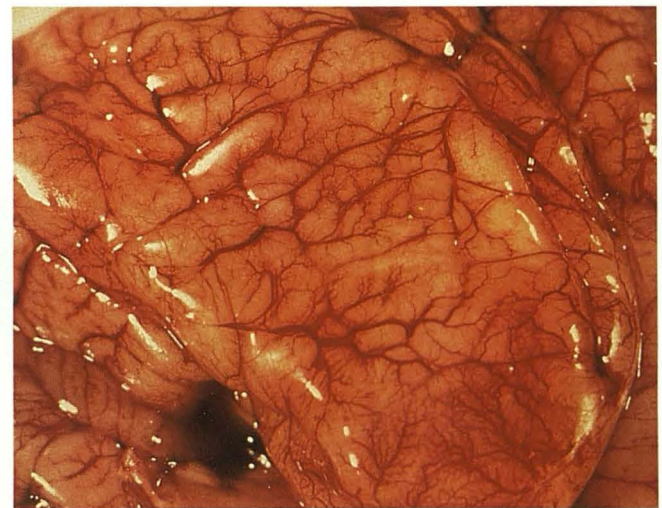
There are many metabolic disorders in which there are definite neurologic clinical manifestations but no apparent gross pathologic abnormalities. Not surprisingly, these conditions may also appear normal on diagnostic neuroimaging. These conditions include Lesch-Nyhan syndrome; Wolman disease; Morquio syndrome; Sly disease; mucopolipidosis I, II, III, IV; fucosidosis; mannosidosis; and others. In these conditions, the defect lies at the neurotransmitter/biochemical level, interfering with cellular function but preserving cell structure.

TABLE 4: Peroxisomal disorders

Reduction of peroxisomal number and function
Zellweger syndrome
Neonatal ALD
Infantile Refsum disease
Hyperpipecolic acidemia
Normal number of peroxisomes but decreased enzymatic activity
Pseudo-Zellweger syndrome
Rhizomelic chondrodysplasia punctata
Normal number of peroxisomes and single enzymatic defect
Acatlasemia
Sex-linked ALD



A



B

Fig. 9. Zellweger syndrome. A, Liver showing many mitochondria (a) and rare peroxisomes (b). (Electron micrograph, $\times 40,000$). B, The brain shows prominent polymicrogyria.

Conclusions

The subject of metabolic disease is extremely broad. Many disorders with precise enzyme defects have nonspecific and nondiagnostic pat-

terns of pathology. A few have fairly characteristic patterns. The gross patterns of neuropathology associated with lysosomal enzyme defects are cortical atrophy and leukodystrophy. Those associated with mitochondrial enzyme defects are Leigh disease (periventricular demyelination and gliosis, basal ganglia spongiosis) and focal infarction. The gross patterns of neuropathology associated with peroxisomal enzyme defects are polymicrogyria and leukodystrophy. However, as we see more enzymatic variations of these rare disorders presenting at different stages of disease progression, even the known patterns become less precise diagnostically and more suggestive of a wide differential diagnosis. Because our understanding of the pathogenesis of many metabolic disorders is still evolving, better correlation between biochemistry, morphology, and imaging is needed to enhance the definition of these conditions. In metabolic diseases, it is important to correlate the biochemical defect with the pattern of pathology in order to be certain that the correct diagnostic label has been attached to the pattern.

Acknowledgment

The paper was prepared with the assistance of Libby Duke.

References

1. Becker LE. Organelle pathology in metabolic neuromuscular disease: an overview. *Can J Vet Res* 1990;54:1-14
2. Becker LE, Yates A. Inherited metabolic disease. In: Davis RL, Robertson DM, eds. *Textbook of neuropathology*. 2nd ed. Baltimore: Williams & Wilkins, 1990:331-427
3. DeMeyer W. Megalencephaly in children: clinical syndromes, genetic patterns, and differential diagnosis from other causes of megalencephaly. *Neurology* 1972;22:634-643
4. Terry RD, Weiss M. Studies in Tay-Sachs disease. II. Ultrastructure of the cerebrum. *J Neuropathol Exp Neurol* 1963;22:18-55
5. Arsenio-Nunes ML, Goutières F, Aicardi J. An ultramicroscopic study of skin and conjunctival biopsies in chronic neurologic disorders of childhood. *Ann Neurol* 1981;9:163-173
6. Suzuki K. Ganglioside patterns of normal and pathological brain. In: Aronson SM, Volk BW, eds. *Inborn disorders of sphingolipid metabolism*. Oxford, England: Pergamon Press, 1967:215-226
7. Poser CM. Leukodystrophy and the concept of dysmyelination. *Arch Neurol* 1961;4:323-332
8. Haltia T, Palo J, Haltia M, et al. Juvenile metachromatic leukodystrophy: clinical, biochemical, and neuropathological studies in nine new cases. *Arch Neurol* 1980;37:42-46
9. Feanny ST, Chuang SH, Becker LE, et al. Intracerebral periventricular hyperdensities: a new CT sign on Krabbe globoid cell leukodystrophy. *J Inherited Met Dis* 1987;10:24-27
10. Kobayashi T, Goto I, Yamanaka T, et al. Infantile and fetal globoid cell leukodystrophy: analysis of galactosylceramide and galactosylsphingosine. *Ann Neurol* 1988;24:517-522
11. Moser HW, Moser AB, Kawamura N, et al. Adrenoleukodystrophy: studies of the phenotype, genetics and biochemistry. *Johns Hopkins Med J* 1980;147:217-224
12. Tsuji S, Sano T, Argia T, et al. Increased synthesis of hexacosanoic acid (C26:0) by cultured skin fibroblasts from patients with adrenoleukodystrophy (ALD) and adrenomyeloneuropathy (AMN). *J Biochem* 1981;90:1233-1240
13. Singh I, Moser HW, Moser AB, et al. Adrenoleukodystrophy: impaired oxidation of long chain fatty acids in cultured skin fibroblasts and adrenal cortex. *Biochem Biophys Res Commun* 1981;102:1223-1229
14. Borrett D, Becker LE. Alexander's disease: a disease of astrocytes. *Brain* 1985;108:367-385
15. Farrell K, Chuang S, Becker LE. Computed tomography in Alexander's disease. *Ann Neurol* 1984;15:605-607
16. Matalon R, Michals K, Sebesta D, et al. Aspartoacylase deficiency and N-acetylaspartic aciduria in patients with Canavan disease. *Am J Med Genet* 1988;29:463-471
17. Adachi M, Schneck L, Cara J, et al. Spongy degeneration of the central nervous system (van Bogaert & Bertrand type: Canavan's disease). *Hum Pathol* 1973;4:331-347
18. Koeppen AH, Ronca NA, Greenfield EA, et al. Defective biosynthesis of proteolipid protein in Pelizaeus-Merzbacher disease. *Ann Neurol* 1987;21:159-170
19. Willard HF, Riordan JR. Assignment of the gene for myelin proteolipid to the X chromosome: implication for X-linked myelin disorders. *Science* 1985;230:940-942
20. Moosy J. The neuropathology of Cockayne's syndrome. *J Neuropathol Exp Neurol* 1967;26:654-660
21. Black DN, Booth F, Watlers GV, et al. Leukodystrophy among native Indian infants in northern Quebec and Manitoba. *Ann Neurol* 1988;24:490-496
22. Di Mauro S, Bonilla E, Zeviani M, et al. Mitochondrial myopathies. *Ann Neurol* 1985;17:521-538
23. Di Mauro S, Trevison C, Hays AP. Disorders of lipid metabolism in muscle. *Muscle Nerve* 1980;3:369-388
24. Carofoli E. Mitochondrial pathology: an overview. *Ann NY Acad Sci* 1986;488:1-18
25. Moser HW. New approaches in peroxisomal disorders. *Dev Neurosci* 1987;9:1-18
26. Volpe JJ, Adams RD. Cerebro-hepato-renal syndrome of Zellweger: an inherited disorder of neuronal migration. *Acta Neuropathol (Berl)* 1972;20:175-198
27. Vamecq J, Draye J-P, Van Hoof, et al. Multiple peroxisomal enzymatic deficiency disorders: a comparative biochemical and morphologic study of Zellweger cerebrohepatorenal syndrome and neonatal adrenoleukodystrophy. *Am J Pathol* 1986;125:524-535