

Are your **MRI contrast agents** cost-effective?

Learn more about generic **Gadolinium-Based Contrast Agents**.



FRESENIUS
KABI

caring for life

AJNR

Enhancement of gray matter in anterior spinal infarction.

D P Friedman and A E Flanders

AJNR Am J Neuroradiol 1992, 13 (3) 983-985

<http://www.ajnr.org/content/13/3/983.citation>

This information is current as
of April 18, 2024.

Enhancement of Gray Matter in Anterior Spinal Infarction

David P. Friedman and Adam E. Flanders

Summary: The authors present a case of distal spinal cord infarction in a 76-year-old man; the pattern of enhancement in the conus medullaris and lumbar enlargement are consistent with infarction as indicated by the clinical history.

Index terms: Spinal cord, infarction; Spinal cord, magnetic resonance

There are relatively few descriptions of distal spinal cord infarction in the MR literature (1–4) and only two include contrast-enhanced scans [2, 3]. In this report, we analyze a case of distal spinal cord infarction in the distribution of the anterior spinal artery; there is excellent correlation between the pattern of enhancement and the angioarchitecture of the cord.

Case Report

A 76-year-old man had an uneventful repair of an infrarenal abdominal aortic aneurysm in July 1990. Six months later, he developed intermittent lower extremity weakness and back pain. A diagnosis of spinal stenosis was made, and he was treated with epidural steroid injections. After the last epidural injection, he noted transient radicular pain and weakness. The patient then experienced a syncopal episode; upon regaining consciousness, he had a flaccid paraplegia with absent deep tendon reflexes but preserved proprioception and vibration sense. A clinical diagnosis of an anterior cord syndrome was made. The differential diagnosis included infarction, myelitis, demyelination, intramedullary tumor, and an epidural compressive lesion. A post-gadolinium sagittal T1-weighted image revealed hypointensity and swelling of the distal thoracic cord and conus medullaris without enhancement (Fig. 1A). Sagittal T2-weighted scans showed hyperintensity in a comparable location. Follow-up postcontrast T1-weighted images obtained 3 weeks later revealed enhancement of the periphery of the central gray matter of the lumbar enlargement, with sparing of the posteromedial margin near the posterior horns (Figs. 1B and 1C). The gray matter of the distal thoracic cord enhanced in a more uniform fashion (Fig. 1D). The aortic graft was normal in appearance. Thorough medical evaluation of the patient revealed

essential thrombocythemia and severe anemia, the latter secondary to cecal angiodysplasia.

Discussion

Spontaneous anterior spinal cord infarction is an uncommon clinical entity that primarily affects individuals with severe atherosclerotic disease or aortic dissection. Other etiologies include syphilis, vasculitis, disk herniation, cervical subluxation, and hypotension (1, 5). We postulate that the blood supply to the lower cord in this patient was tenuous, and with the added stress of his anemia, thrombocythemia, and hypotensive episode, a watershed type of infarction occurred. The patient was probably having episodes of spinal claudication prior to admission. Parenthetically, epidural anesthetic injection has been implicated in cases of anterior spinal artery infarction (6).

The anterior spinal artery supplies approximately 70% of the blood to the cord, including all of the gray matter except for the posterior horns, and the corticospinal tracts. It does this in a centrifugal fashion via numerous central (sulcal) arteries that traverse the anterior median fissure and alternately penetrate the cord to the right or left. Within the interior of the cord there are no anastomoses, and the central penetrating vessels are essentially end arteries. The paired posterior spinal arteries supply approximately 30% of the cord, including the posterior horns, posterior columns, and a peripheral rim of white matter. They do this in a centripetal fashion via numerous peripheral perforating arteries that are richly connected by anastomotic channels (7, 8). The periphery of the gray matter is at the border zone of these centrifugal and centripetal circulations.

The intrinsic arterial supply to the cord is directly proportional to the cross-sectional area of the gray matter, which is most abundant in the thoracolumbar segment. The central gray

Received July 26, 1991; accepted after revision on October 28.

Both authors: Department of Radiology, Jefferson Medical College and Thomas Jefferson University Hospital, 10th and Sansom Streets, Room #1069—Main Building, Philadelphia, PA 19107. Address reprint requests to Dr Friedman.

AJNR 13:983–985, May/June 1992 0195-6108/92/1303-0983 © American Society of Neuroradiology

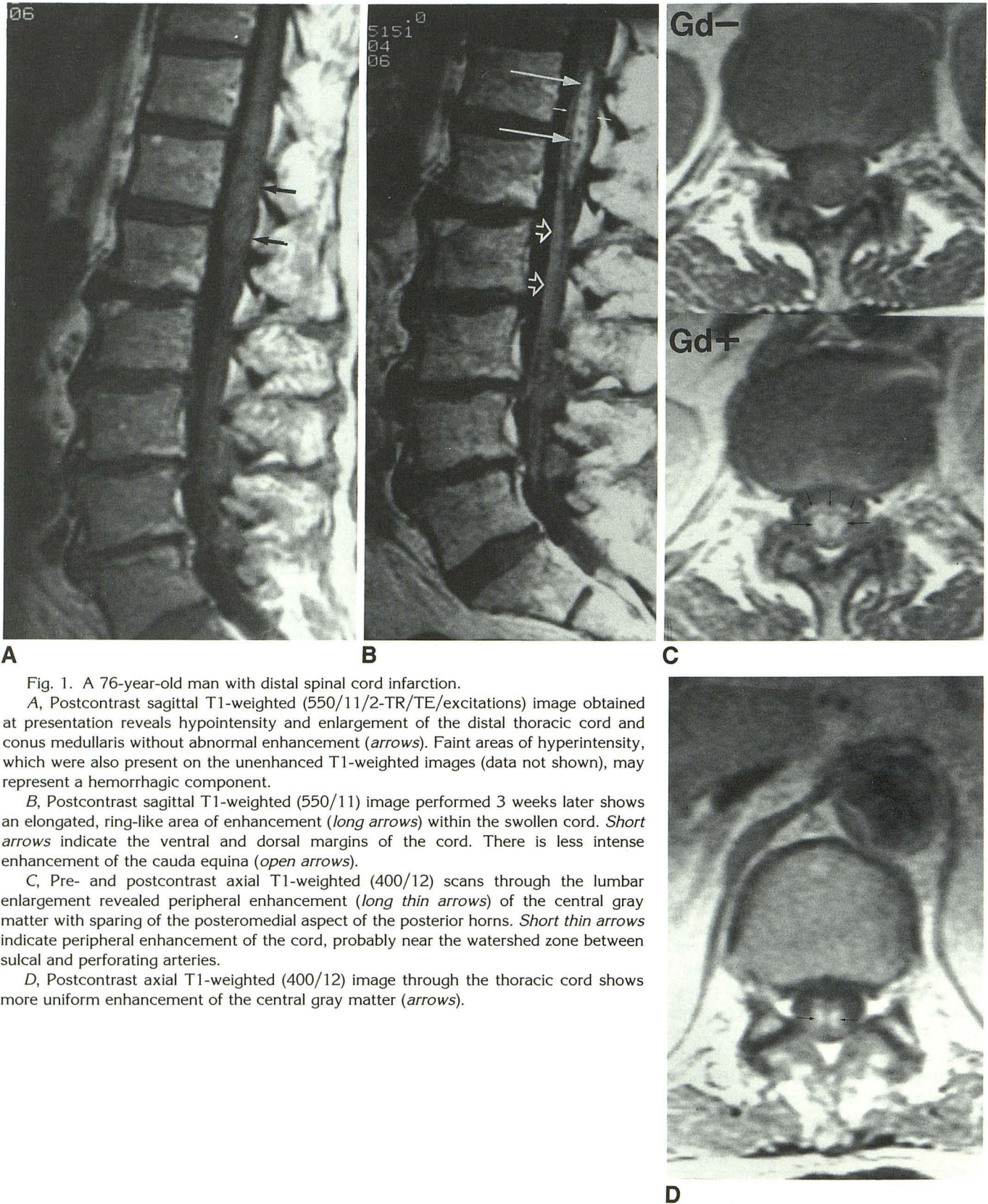


Fig. 1. A 76-year-old man with distal spinal cord infarction.

A, Postcontrast sagittal T1-weighted (550/11/2-TR/TE/excitations) image obtained at presentation reveals hypointensity and enlargement of the distal thoracic cord and conus medullaris without abnormal enhancement (*arrows*). Faint areas of hyperintensity, which were also present on the unenhanced T1-weighted images (data not shown), may represent a hemorrhagic component.

B, Postcontrast sagittal T1-weighted (550/11) image performed 3 weeks later shows an elongated, ring-like area of enhancement (*long arrows*) within the swollen cord. *Short arrows* indicate the ventral and dorsal margins of the cord. There is less intense enhancement of the cauda equina (*open arrows*).

C, Pre- and postcontrast axial T1-weighted (400/12) scans through the lumbar enlargement revealed peripheral enhancement (*long thin arrows*) of the central gray matter with sparing of the posteromedial aspect of the posterior horns. *Short thin arrows* indicate peripheral enhancement of the cord, probably near the watershed zone between sulcal and perforating arteries.

D, Postcontrast axial T1-weighted (400/12) image through the thoracic cord shows more uniform enhancement of the central gray matter (*arrows*).

matter has a much higher metabolic rate than white matter and consequently receives five times more blood flow (7, 8). Hence, due to the angioarchitecture and metabolic demands of the gray matter, its peripheral margin should be most vulnerable to hypoperfusion and disruption of the blood-cord barrier. This probably explains the peripheral pattern of enhancement seen in the thoracolumbar segment; moreover, the lack of enhancement of the posteromedial aspect of the posterior horns can be attributed to preserved posterior spinal artery supply (Fig. 1C). These considerations suggest that this pattern of enhancement will not be seen in other disease states. The central gray in the lower thoracic cord enhanced more uniformly (Fig. 1D); it is possible that the spatial resolution was not adequate to resolve an enhancing margin in this area of relative sparse gray matter, or that such a margin did not exist at this location.

The patient apparently sustained ischemic injury to the cauda equina, as modest but definite enhancement of intradural roots was seen on the follow-up study (Fig. 1B). The blood supply to the cauda equina includes multiple small

branches from lumbar, iliolumbar, and lateral sacral arteries, as well as the terminal portion of the anterior spinal artery (7, 8). Additional cases will be required to determine if enhancement of the cauda equina is a frequent concomitant of anterior spinal infarction.

References

1. Mawad ME, Rivera V, Crawford S, Ramirez A, Breitbart W. Spinal cord ischemia after resection of thoracoabdominal aortic aneurysms: MR findings in 24 patients. *AJNR* 1990;11:987-991
2. Casselman JW, Jolie E, Dohaene I, Meeus L, St.-Jan AZ. Gadolinium-enhanced MR imaging of infarction of the anterior spinal cord. *AJNR* 1991;12:561
3. Dillon WP, Norman D, Newton TH, Bolla K, Mark A. Intradural spinal cord lesions: Gd-DTPA-enhanced MR imaging. *Radiology* 1989;170:229-237
4. Brown E, Virapongse C, Gregorios JB. MR imaging of cervical spinal cord infarction. *J Comput Assist Tomogr* 1989;13:920-922
5. Sandson TA, Friedman JH. Spinal cord infarction: report of 8 cases and review of the literature. *Medicine* 1989;68:282-292
6. Adriani J, Naragi M. Paraplegia associated with epidural anesthesia. *Southern Med J* 1986;79:1350-1355
7. Lazorthes G, Gouaze A, Zadeh JO, et al. Arterial vascularization of the spinal cord. *J Neurosurg* 1971;35:253-269
8. Herren RY, Alexander L. Sulcal and intrinsic blood vessels of human spinal cord. *Arch Neurol Psychiatry* 1939;41:678-687