

Are your **MRI contrast agents** cost-effective?

Learn more about generic **Gadolinium-Based Contrast Agents**.



FRESENIUS  
KABI

caring for life

**AJNR**

**Herpes zoster ophthalmicus with orbital  
pseudotumor syndrome complicated by optic  
nerve infarction and cerebral granulomatous  
angiitis: MR-pathologic correlation.**

F J Lexa, S L Galetta, D M Yousem, M Farber, J C Oberholtzer  
and S W Atlas

This information is current as  
of April 19, 2024.

*AJNR Am J Neuroradiol* 1993, 14 (1) 185-190  
<http://www.ajnr.org/content/14/1/185>

# Herpes Zoster Ophthalmicus with Orbital Pseudotumor Syndrome Complicated by Optic Nerve Infarction and Cerebral Granulomatous Angiitis: MR-Pathologic Correlation

Frank J. Lexa,<sup>1</sup> Steven L. Galetta,<sup>2</sup> David M. Yousem,<sup>1</sup> Martha Farber,<sup>3</sup> J. Carl Oberholtzer,<sup>4</sup> and Scott W. Atlas<sup>1</sup>

**Summary:** The authors describe a 41-year-old woman with herpes zoster ophthalmicus and extensive intracranial and orbital involvement as documented by MR and pathologically. MR showed all of the lesions that led to the ophthalmoplegia and pseudotumor syndrome, the periaxial infarct of the distal optic nerve, pontine infarcts, and granulomatous angiitis of the meningeal vessels. MR is useful in both detection and monitoring of the disease.

**Index terms:** Orbits, magnetic resonance; Vasculitis; Nerves, optic (II)

We describe a patient with herpes zoster ophthalmicus and an orbital pseudotumor syndrome manifesting as right eye proptosis, ophthalmoplegia, and optic nerve dysfunction. Magnetic resonance (MR) imaging demonstrated extensive inflammation of the orbital structures with enhancement of the right optic nerve sheath complex as well as intrinsic enhancement of the right optic nerve head suggesting acute infarction. Although subsequent MR showed resolution of the orbital inflammation, abnormal parenchymal signal was seen in the pons and right hemispheric white matter with abnormal meningeal enhancement. Necropsy examination confirmed pontine and optic nerve infarctions as well as granulomatous angiitis of the leptomeningeal arteries. We conclude that MR is useful for identifying the wide array of inflammatory and ischemic complications associated with herpes zoster ophthalmicus. Serial MR may document both the regression and progression of various aspects of this unusual disorder.

## Case Report

A 41-year-old white woman with a 4-year history of scleroderma, treated previously with D-penicillamine and

plasmapheresis, presented at another hospital with right periorbital pain of 5 days' duration. Seven days after the onset of her pain, a right perinasal vesicular rash consistent with herpes zoster appeared (Fig. 1). Oral and topical steroid treatments were begun with incomplete pain relief. Twelve days after the onset of her symptoms, she was discharged. The next day, while applying her eye drops, she noted complete loss of vision in the right eye. Computed tomography (CT) of the head demonstrated an inflammatory mass involving the right globe and retrobulbar tissues. Intravenous acyclovir was begun, but the patient rapidly became encephalopathic and was transferred to this institution.

Initial examination revealed a right eye acuity of no light perception and 20/30 +2 acuity on the left. The right eye was chemotic with 3–4 mm of proptosis with complete ophthalmoplegia. The right pupil was dilated and unreactive to direct and consensual stimulation. Ocular motility on the left was full with normal pupil reactivity. There were 2–3+ cells in the right anterior chamber. Fundoscopy was remarkable only for cotton wool spots in both eyes. Initial lumbar puncture demonstrated: white blood cells, 13 cells/mm<sup>3</sup> (differential: polymorphonuclear cells, 31; lymphocytes, 63; and monocytes, 6), red blood cells, 10 cells/mm<sup>3</sup>, protein, 68 mg/dL; and glucose, 48 mg/dL (simultaneous serum glucose 80 mg/dL).

Initial imaging evaluation included a 1.5-T MR study (Signa, General Electric Medical Systems, Milwaukee, WI). Images through the head were obtained using spin-echo technique with short TR/short TE (T1-weighted), long TR/short TE (proton density-weighted) and long TR/long TE (T2-weighted). Images were also obtained in the axial and coronal planes after intravenous injection of paramagnetic contrast (0.1 mL/kg, gadolinium-DTPA, Berlex, NJ). High-resolution pre- and postenhancement coronal and axial T1-weighted images were obtained through the orbits using a surface coil. The orbital images demonstrated uveal-scleral thickening of the right globe, ill-defined soft tissue throughout the right pre- and postseptal soft tissues, and right rectus muscle and tendon enlargement. The optic nerve

Received November 19, 1991; revision requested March 18, 1992; revision received April 8 and accepted July 8.

<sup>1</sup> Department of Radiology, Neuroradiology Section, The Hospital of the University of Pennsylvania, 34th and Spruce Streets, Philadelphia, PA 19104. Address reprint requests to Dr Lexa at the above address.

<sup>2</sup> Department of Neurology, The Hospital of the University of Pennsylvania, 34th and Spruce Streets, Philadelphia, PA 19104.

<sup>3</sup> Department of Pathology, Scheie Eye Institute, Philadelphia, PA 19104.

<sup>4</sup> Department of Pathology, The Hospital of the University of Pennsylvania, 34th and Spruce Streets, Philadelphia, PA 19104.

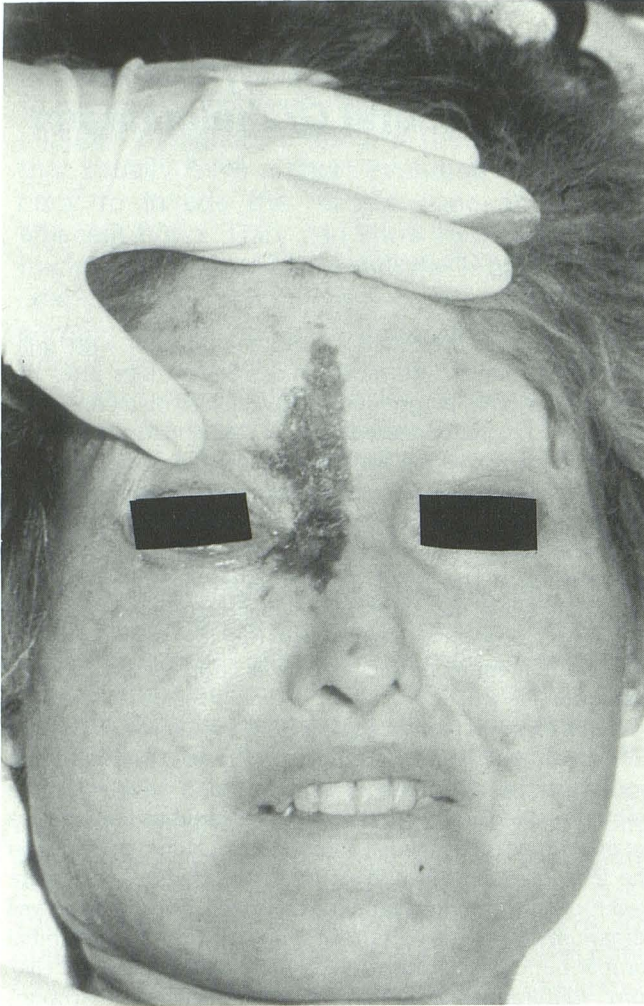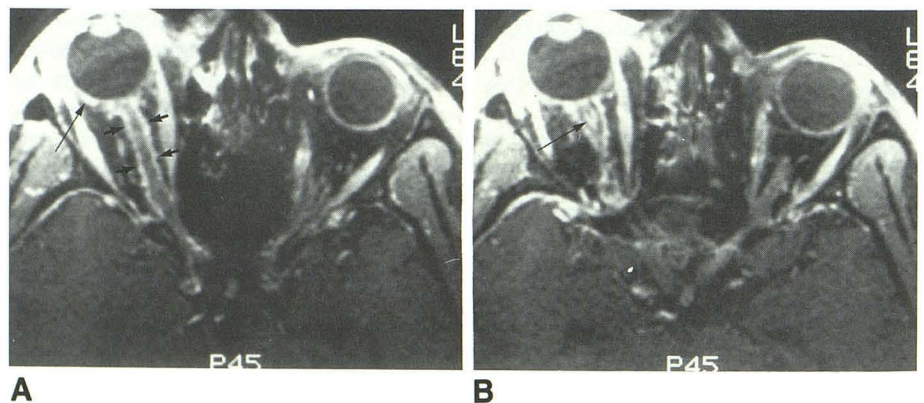


Fig. 1. Perinasal vesicular rash of herpes zoster.

sheath complex showed abnormal peripheral enhancement, particularly prominent about the nerve head, with slight enhancement within the nerve head itself (Figs. 2A and 2B). There was also abnormal intracranial meningeal enhancement (Fig. 3) as well as an area of high signal in the rostral right pons at the level of the fifth nerve nucleus (Fig. 4).

Fig. 2. A Post-gadolinium MR with fat saturation, using spoiled, gradient-recalled technique, 46/6 (TR/TE) with a 30° flip angle, demonstrates abnormal peripheral enhancement of the right optic nerve (*short arrows*), with abnormal thickening and enhancement of the posterior globe (*long arrow*).

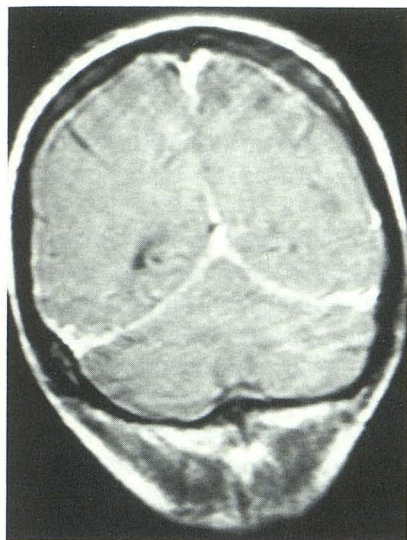
B, A second image from the same series demonstrates additional enhancement within the optic nerve (*arrow*), in the distribution of the periaxial infarction. Both images demonstrate enlargement of the right medial and lateral recti muscles and tendon insertions consistent with pseudotumor.



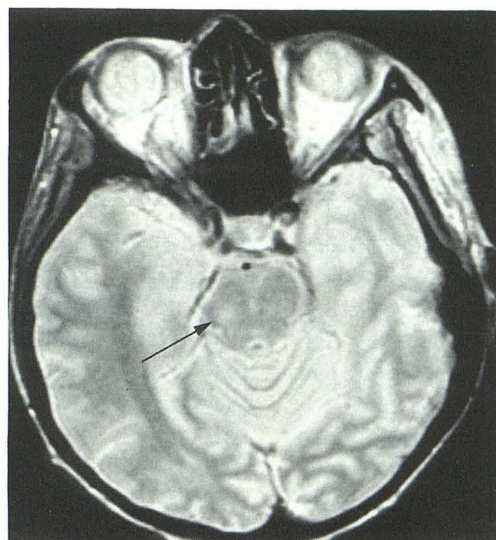
On intravenous acyclovir (6 mg/kg/day) the chemosis and proptosis slowly resolved but the patient became progressively more encephalopathic and then comatose with Cheyne-Stokes respirations. The left leg became flexed and externally rotated with loss of withdrawal to noxious stimuli on the left. Repeat cerebrospinal fluid (CSF) analysis revealed: white blood cells, 62 cells/mm<sup>3</sup> (91% lymphocytes); red blood cells, 3 cells/mm<sup>3</sup>; glucose, 57 mg/dL; and protein of 148 mg/dL. Hepatitis and human immunodeficiency virus screens were negative. CSF-VDRL serology was not reactive. CSF cytologic and microbiologic examinations were negative. Eleven days into this admission, repeat CT and MR showed improvement in the orbital inflammation, but new right hemispheric swelling and sulcal effacement. There was abnormal falcine and tentorial enhancement as well as new abnormal high signal intensity in the left pons. Intravenous corticosteroids were added to the acyclovir regimen. In the final 2 days of life her mental status had improved and she was able to follow simple commands. The patient's course, however, was complicated by pneumonia, sepsis, gastrointestinal bleeding, and pulmonary hemorrhage, the latter probably related to a uremic platelet syndrome. Four weeks after the onset of her symptoms, the patient died of a massive pulmonary hemorrhage.

#### Pathologic Examination

At necropsy there was herpetic dermatitis in the distribution of the first division of the right trigeminal nerve. The gross neuropathologic examination disclosed small bilateral subdural hematomas that were felt to be incidental. Despite a normal appearance on gross inspection, microscopic examination of the leptomeninges showed granulomatous angiitis. Inflammatory infiltrate, consisting of epithelioid histiocytes, lymphocytes, and occasional plasma cells predominantly involved the adventitia of blood vessels (Fig. 5A). There was segmental vasculitic involvement of the large arteries of the anterior circulation as well as of the distal middle cerebral arteries bilaterally. No intraparenchymal angiitic involvement was found. Viral inclusion bodies were not seen on light microscopy and specific antisera stains for varicella-zoster were negative. No evi-



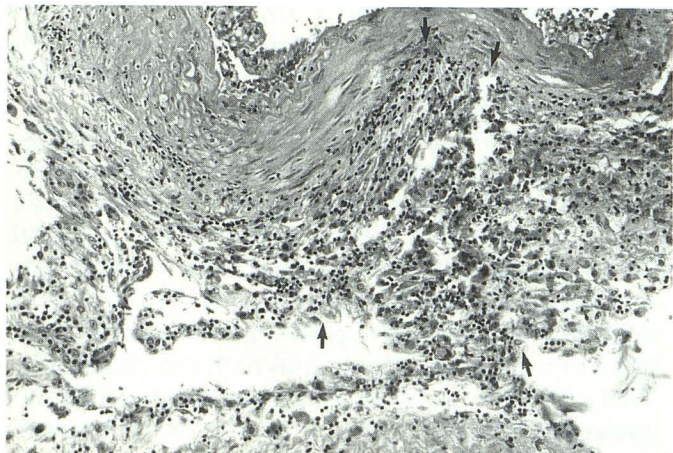
3



4

Fig. 3. Post-gadolinium image, 600/16, in the coronal plane demonstrates diffuse abnormal meningeal enhancement.

Fig. 4. Axial 3000/35 image, shows abnormal high signal at the junction of the pons and mesencephalon on the right (arrow).



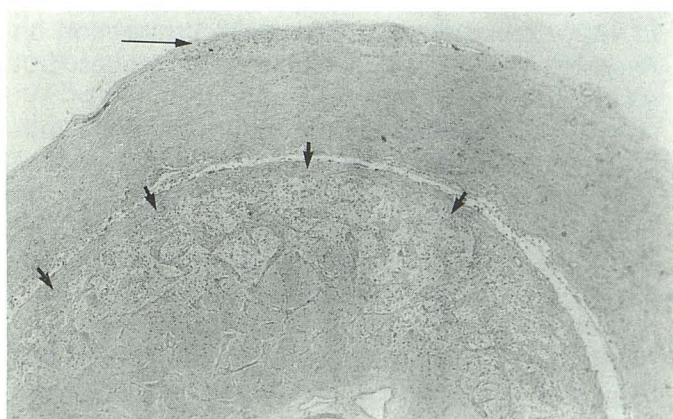5A



5B

Fig. 5. A, Histologic section demonstrates granulomatous angiitis of a leptomenigeal vessel, with inflammatory infiltrate of lymphocytes, histiocytes, and macrophages in the adventitia (arrows).

B, Histologic section through the right pons, demonstrates area of recent infarction (short arrows) with retraction bodies in the adjacent tissue (long arrow).



6

Fig. 6. Histologic section (original magnification 40X) through the optic nerve head demonstrates periaxial infarction of distal nerve (short arrows) with inflammation of the adventitia (long arrow).

dence of encephalitis or cerebritis was found. A microscopic intraparenchymal hemorrhage in the frontal cortex was seen with questionable lymphocytic infiltration of an overlying leptomenigeal vessel. Several scattered areas of subacute infarction were identified in the pons (Fig. 5B) and medulla, corresponding to the areas seen on MR.

The ophthalmic histopathologic examination also corresponded well to the MR findings, demonstrating a periaxial infarction of the right optic nerve and chronic inflammation in the right uveal tract and vitreous (Fig. 6). A retinal perivasculitis was also demonstrated. In the left retina, a small microinfarct of the nerve fiber layer was

seen. All fungal, viral, and bacterial cultures of the pathologic material were negative.

## Discussion

The varicella-zoster virus is a double-stranded DNA virus weighing  $80\text{--}100 \times 10^6$  daltons, with an enveloped icosahedral capsid measuring 200 nanometers (1). In temperate climates, primary infections—varicella or “chicken pox”—tend to occur in childhood during the spring, with 3 million cases a year in the United States (2). Seropositivity approaches 100% by age 60 in the native-born population of the United States (3, 4). Zoster eruptions are generally believed to represent a recrudescence of latent virus in sensory ganglia (5). In about 10% of herpes zoster cases the ophthalmic division of the trigeminal nerve is involved (6, 7). These patients are more likely to be elderly (7, 8) or immunosuppressed from a variety of etiologies including the acquired immunodeficiency syndrome (8–14).

The most commonly reported complication of herpes zoster is postherpetic neuralgia (7, 15, 16). However, ocular involvement is documented in 20%–71% of cases of herpes zoster ophthalmicus (6, 7, 16) and includes: keratoconjunctivitis (6, 16), ocular motor palsies (17–20), acute retinal necrosis (21–24), acute phthisis bulbi (20, 25), optic neuritis (26), and central retinal artery occlusion (27, 28).

Central nervous system (CNS) complications of herpes zoster may include an encephalitis, commonly observed in elderly or immunocompromised patients with disseminated lesions (1, 29–31). A more intriguing complication is the delayed contralateral hemiplegia that may occur without clinical evidence of encephalitis (usually about 1 month, but possibly up to 2 years, after the initial infection) (19, 32–34). This entity was first described by Baudoin (35) and is believed to result from granulomatous angiitis of the carotid system ipsilateral to the skin lesion. Concurrent varicella-zoster virus encephalitis and granulomatous angiitis has been reported (36) and a spectrum of manifestations between the two has been proposed (37).

Granulomatous arteritis is a form of vasculitis characterized by a mixed infiltrate of histiocytes, mononuclear cells, lymphocytes, and multinucleated giant cells (38). This vasculitic process is the likely cause of cerebral infarction observed in patients with the herpes zoster ophthalmicus-contralateral hemiplegia syndrome (39–45). Necrotizing angiitis without granulomatous features

has also been described (46, 47). Granulomatous angiitis of the CNS however, is not specific for varicella-zoster and can be seen in association with a variety of pathologic entities including Hodgkin disease, sarcoid, systemic lupus erythematosus, and giant cell (temporal) arteritis (48, 49).

The typical features of herpes zoster ophthalmicus associated granulomatous angiitis on angiography include segmental proximal narrowing of the intracranial internal carotid, the large arteries at the base of the brain, and the proximal portions of the middle (first 2 cm) and anterior (first 3 cm) cerebral arteries (40, 42, 46, 50, 51). Rarely, mycotic aneurysm formation may be observed (52). Granulomatous angiitis infarcts tend to be bland but they also may be hemorrhagic (53–57) and have been seen in both adults and children (58). Although clinical and angiographic features usually support involvement of the carotid branches ipsilateral to the involved cranial nerve, a more diffuse form with bilateral disease has been reported (45, 59).

On CT, herpes zoster ophthalmicus-related cerebral ischemia is typically associated with ipsilateral infarcts in the distribution of the middle cerebral artery (44, 45, 60, 61). However, bilateral involvement as well as a single case of contralateral-only infarction have been reported (37). In addition, infarcts of the posterior circulation have been reported with trigeminal herpetic infections. This has been ascribed to dissemination from the gasserian ganglion (62) or to anatomic variants with trigeminal supply to the posterior circulation branches (63, 64). A single previous report of MR in varicella-zoster demonstrated an infarction on long TR/long TE (T2-weighted) sequences, but gadolinium was not administered (62).

In 1976, Reyes et al first documented intranuclear virus-like particles in glial cells of a patient with granulomatous angiitis (66). Spread of the virus into the CNS may occur by more than one mechanism. Direct dissemination of varicella-zoster virus along nerve pathways was first postulated by Cope and Jones in 1954 (67). Intra-neuronal (68) and transsynaptic (69) spread has been well documented in humans and in animal models (70). The ophthalmic nerve gives branches which supply sensation to the internal carotid artery and its proximal ramifications. Mackenzie et al postulated that these branches allow viral particles to first spread to the adventitia of vessels with general dissemination occurring via the subarachnoid space (46). Supportive

evidence for this theory includes work by Linne-  
mann et al and Doyle et al who demonstrated  
herpes-like virions in smooth muscle cells of the  
outer layers of affected arteries with sparing of  
the endothelium (51, 71).

This case provides supporting evidence for  
several types of viral involvement, including  
spread into the pons at the level of the gasserian  
ganglion and cerebral infarction from granuloma-  
tous angiitis. The lesion in the right pons noted  
on MR is consistent with direct inflammatory  
involvement of the central pathways of the right  
fifth cranial nerve. Diffuse inflammation through-  
out the meninges and subarachnoid vessels sup-  
ports the theory that the virus can disseminate  
diffusely throughout the CSF either directly from  
the level of the gasserian ganglion or possibly  
from neural pathways to proximal intracranial  
vessels.

This case is instructive for several reasons. The  
association of herpes zoster ophthalmicus with  
orbital pseudotumor syndrome has been reported  
(17, 20), but is rare. Despite therapy there was  
rapid progression to encephalopathy and coma  
consistent with diffuse CNS involvement. MR at  
the height of ocular and CNS involvement was  
able to demonstrate all of the lesions that were  
later confirmed at necropsy, including the orbital  
inflammation that led to her ophthalmoplegia and  
pseudotumor syndrome, the periaxial infarct of  
the distal optic nerve, the pontine infarcts, as well  
as the granulomatous angiitis of the meningeal  
vessels which was manifest as abnormal menin-  
geal enhancement. Moreover, we were able to  
follow the regression of the orbital inflammation  
in response to treatment as well as the develop-  
ment of new lesions in the left pons. MR appears  
to be useful in the detection and monitoring of  
this unusual disease and its many complications.

## References

- Barnes DW, Whitley RJ. CNS diseases associated with varicella zoster virus and herpes simplex virus infection: pathogenesis and current therapy. *Neurol Clin* 1986;4:265-283
- Lisegang TJ. Diagnosis and therapy of herpes zoster ophthalmicus. *Ophthalmology* 1991;98:1216-1229
- Gershon AA, Steinberg SP. Antibody responses to varicella-zoster virus and the role of antibody in host defense. *Am J Med Sci* 1981;12:282-287 (as cited in Weller, ref. 4)
- Weller TH. Varicella and herpes zoster changing concepts of the natural history, control, and importance of a not-so-benign virus. Part I. *N Engl J Med* 1983;309:1362-1368
- Weller TH. Varicella and herpes zoster changing concepts of the natural history, control, and importance of a not-so-benign virus. Part II. *N Engl J Med* 1983;309:1434-1440
- Bucci FA, Salvia PV, Mauriello JA. Herpes zoster ophthalmicus. *Am Fam Physician* 1987;35:121-128
- Ragozzino MW, Melton LJ III, Kurland LT, Chu CP, Perry HO. Population-based study of herpes zoster and its sequelae. *Medicine* 1982;61:310-316
- Rogers RS III, Tindall JP. Geriatric herpes zoster. *J Am Geriatr Soc* 1971;19:495-504
- Reichman RC, Mazur MH, Whitely RJ. Herpes zoster-varicella infections in immunosuppressed patients. *Ann Intern Med* 1978;89:375-388
- Sandor E, Croxson TS, Millman A, Mildvan D. Herpes zoster ophthalmicus in patients at risk for AIDS. *N Engl J Med* 1984;310:1118-1119
- Cole EL, Meisler DM, Calabreses LH, Holland GN, Mondino BJ, Conant MA. Herpes zoster ophthalmicus and acquired immune deficiency syndrome. *Arch Ophthalmol* 1984;102:1027-1029
- Sandor EV, Croxson TS, Millman A, Mildvan D. Herpes zoster ophthalmicus in patients at risk for the acquired immune deficiency syndrome (AIDS). *Am J Ophthalmol* 1986;101:153-155
- Kestelyn P, Stevens AM, Bakkers E, Rouvroy D, Van de Perre P. Severe herpes zoster ophthalmicus in young African adults: a marker for HTLV-II seropositivity. *Br J Ophthalmol* 1987;71:806-809
- Pillai S, Mahmood MA, Limaye SR. Herpes zoster ophthalmicus, contralateral hemiplegia, and recurrent ocular toxoplasmosis in a patient with acquired immune deficiency syndrome-related complex. *J Clin Neurol Ophthalmol* 1989;9:229-235
- Murray BJ. Medical complications of herpes zoster in immunocompetent patients. *Postgrad Med* 1987;81:229-231, 233, 236
- Harding SP, Lipton JR, Wells JC. Natural history of herpes zoster ophthalmicus: predictors of post-herpetic neuralgia and ocular involvement. *Br J Ophthalmol* 1987;71:353-358
- Carmody RF. Herpes zoster ophthalmicus complicated by ophthalmoplegia and exophthalmos. *Arch Ophthalmol* 1937;18:707-711
- Archambault P, Wise JS, Rosen J, Polomeno RC, Auger N. Herpes zoster ophthalmoplegia: report of six cases. *J Clin Neuroophthalmol* 1988;8:185-191
- Marsh RJ, Dullely B, Kelly V. External ocular motor palsies in ophthalmic zoster: a review. *Br J Ophthalmol* 1977;61:677-682
- Amanat LA, Cant JS, Green FD. Acute phthisis bulbi and external ophthalmoplegia in herpes zoster ophthalmicus. *Ann Ophthalmol* 1985;17:46-51
- Forster DJ, Dugel PU, Frangieh GT, Liggett PE, Rao NA. Rapidly progressive outer retinal necrosis in the acquired immunodeficiency syndrome. *Am J Ophthalmol* 1990;110:341-348
- Culbertson WW, Blumenkranz MS, Depose JS, Stewart JA, Curtin VT. Varicella zoster virus is a cause of the acute retinal necrosis syndrome. *Ophthalmology* 1986;93:559-569
- Chess, J, Marcus DM. Zoster-related bilateral acute retinal necrosis syndrome as presenting sign in AIDS. *Ann Ophthalmol* 1988;20:431-438
- Browning DJ, Blumenkranz MS, Culbertson WW. Association of varicella-zoster dermatitis with acute retinal necrosis syndrome. *Ophthalmology* 1987;94:602-606
- Naumann G, Gass JDM, Font R. Histopathology of herpes zoster ophthalmicus. *Am J Ophthalmol* 1968;65:533-541
- Winward KE, Hamed LM, Glaser JS. The spectrum of optic nerve disease in human immunodeficiency virus infection. *Am J Ophthalmol* 1989;107:373-380
- Scharf Y, Kraus E, Zonis S. Optic neuropathy and central retinal artery occlusion in a case of herpes zoster ophthalmicus. *Ann Ophthalmol* 1987;19:77-78
- Hall S, Carlin L, Roach ES, McLean WT Jr. Herpes zoster and central retinal artery occlusion. *Ann Neurol* 1983;13:217-218
- Norris FH Jr, Leonards R, Calanchini PR, Calder CD. Herpes-zoster meningoencephalitis. *J Infect Dis* 1970;122:335-338

30. Jemsek J, Greenberg SA, Taber L, Harvey D, Gershon A, Couch RB. Herpes zoster-associated encephalitis: clinicopathologic report of 12 cases and review of the literature. *Medicine* 1983;62:81-96
31. Peterslund NA. Herpes zoster associated encephalitis: clinical findings and acyclovir treatment. *Scand J Infect Dis* 1988;20:583-592
32. Anastasopoulos G, Routsonis K, Ierodiakonou CS. Ophthalmic herpes zoster with contralateral hemiplegia. *J Neurol Neurosurg Psychiatry* 1958;21:210-212
33. Acers TE. Herpes zoster ophthalmicus with contralateral hemiplegia. *Arch Ophthalmol* 1964;71:371-376
34. Sigal LH. The neurologic presentation of vasculitis and rheumatologic syndromes. *Medicine* 1987;66:157-180
35. Baudoin E, Lantuejoul P. Les troubles dans le zona. *Gazette Des Hopitaux* 1919;92:1293-1295 (as cited in Sigal, ref. 34)
36. Blue MC, Rosenblum MI. Granulomatous angiitis of the brain with herpes zoster and varicella encephalitis. *Arch Pathol Lab Med* 1983;107:126-128
37. Reshef E, Greenberg S, Jankovic J. Herpes zoster ophthalmicus followed by contralateral hemiparesis: report of two cases and review of literature. *J Neurol Neurosurg Psychiatry* 1985;48:122-127
38. Cravioto H, Feigin I. Non-infectious granulomatous angiitis with a predilection for the nervous system. *Neurology* 1959;9:599-608
39. Gasperetti C, Song SK. Contralateral hemiparesis following herpes zoster ophthalmicus. *J Neurol Neurosurg Psychiatry* 1985;48:338-341
40. Walker RJ III, El Gammal T, Allen MB. Cranial arteritis associated with herpes zoster case report with angiographic findings. *Radiology* 1973;107:109-110
41. Rosenblum WI, Hadfield GM. Granulomatous angiitis of the nervous system in cases of herpes zoster and lymphosarcoma. *Neurology* 1972;22:348-354
42. Gilbert GJ. Herpes zoster ophthalmicus and delayed contralateral hemiparesis: relationship of the syndrome to central nervous system granulomatous angiitis. *JAMA* 1974;3:302-304
43. Gildea DH, Vafai A. Varicella-zoster. In: McKendall RR, ed. *Handbook of clinical neurology*. Viral Disease. Vol 12(56). New York: Elsevier. 1989:229-247
44. Verghese A, Sugar AM. Herpes zoster ophthalmicus and granulomatous angiitis: an ill-appreciated cause of stroke. *J Am Geriatr Soc* 1986;34:309-312
45. Herkes GK, Storey CE, Joffe R, Mackenzie RA. Herpes zoster arteritis, clinical and angiographic features. *Clin Exp Neurol* 1987;24:169-174
46. Mackenzie RA, Forbes GS, Karnes WE. Angiographic findings in herpes zoster arteritis. *Ann Neurol* 1981;10:458-464
47. Mackenzie RA, Ryan P, Karnes WE, Okazaki H. Herpes zoster arteritis: pathological findings. *Clin Exp Neurol* 1987;23:219-224
48. Koo EH, Massey EW. Granulomatous angiitis of the central nervous system: protean manifestations and response to treatment. *J Neurol Neurosurg Psychiatry* 1988;51:1126-1133
49. Younger DS, Hays AP, Brust JDM, Rowland LP. Granulomatous angiitis of the brain: an inflammatory reaction of diverse etiology. *Arch Neurol* 1988;45:514-518
50. Sato M, Nabeyama T, Ikeda H. A case of herpes zoster encephalitis complicated by sensory aphasia and contralateral hemiparesis. *Rinsho Shinkeigaku* 1971;11:365-372
51. Doyle P, Gibson G, Dolman CL. Herpes zoster ophthalmicus with contralateral hemiplegia: identification of cause. *Ann Neurol* 1983;14:84-85
52. O'Donohue JM, Enzmann DR. Mycotic aneurysm in angiitis associated with herpes zoster ophthalmicus. *AJNR* 1987;8:615-619
53. Menkes D, Bishara SN, Corbett AJ. Hemispheric infarction after herpes zoster ophthalmicus. *J Neurol Neurosurg Psychiatry* 1983;46:786-788
54. Eible RJ. Intracerebral hemorrhage with herpes zoster ophthalmicus. *Ann Neurol* 1983;14:591-592
55. Mossuto-Agatiello L, Iovine C, Kniahynicki C. Herpes zoster ophthalmicus and delayed ipsilateral intracerebral hemorrhage. *Neurology* 1987;37:1265-1265
56. Tojo K, Onozawa T, Toyohara K, Shimojo S, Sakai O. Herpes zoster ophthalmicus with delayed contralateral hemiparesis. *Jpn J Med* 1990;29:99-103
57. Rosenblum WI, Hadfield MG, Young HF. Granulomatous angiitis with preceding varicella zoster. *Ann Neurol* 1978;3:374-375
58. Liu GT, Holmes GL. Varicella with delayed contralateral hemiparesis detected by MRI. *Pediatr Neurol* 1990;6:131-134
59. Pratesi R, Freeman FR, Lowry JL. Herpes zoster ophthalmicus with contralateral hemiplegia. *Arch Neurol* 1977;34:640-641
60. Kuroiwa Y, Furukawa T. Hemispheric infarction after herpes zoster ophthalmicus: computed tomography and angiography. *Neurology* 1981;31:1030-1032
61. Hilt DC, Buchholz D, Krumholz A, Weiss H, Wolinsky JS. Herpes zoster ophthalmicus and delayed contralateral hemiparesis caused by cerebral angiitis: diagnosis and management approaches. *Ann Neurol* 1983;14:543-553
62. Powers JM. Herpes zoster maxillaris with delayed occipital infarction. *J Clin Neurol Ophthalmol* 1986;6:113-115
63. Geny C, Yulis J, Azoulay A, Brugieres P, Saint-Val C, Degos JD. Thalamic infarction following lingual herpes zoster. *Neurology* 1991;41:1846
64. Mayberg MR, Zervas NT, Moskowitz MA. Trigeminal projections to supratentorial pial and dural blood vessels in cats demonstrated by horseradish peroxidase histochemistry. *J Comp Neurol* 1984;223:46-56
65. Liu GT, Holmes GL. Varicella with delayed contralateral hemiparesis detected by MRI. *Pediatr Neurol* 1990;6:131-134
66. Reyes MG, Fresco R, Chokroverty S, Salud EQ. Viruslike particles in granulomatous angiitis of the central nervous system. *Neurology* 1976;26:797-799
67. Cope S, Jones AT. Hemiplegia complicating ophthalmic zoster. *Lancet* 1954;2:898-899
68. Reske-Nielsen E, Oster S, Pedersen B. Herpes zoster ophthalmicus and the mesencephalic nucleus: a neuropathologic study. *Acta Pathol Microbiol Immunol Scand (A)* 1986;94:263-269
69. Rostad SW, Olson K, McDougall J, Shaw C-M, Alvord EC. Transsynaptic spread of varicella zoster virus through the visual system: a mechanism of viral dissemination in the central nervous system. *Hum Pathol* 1989;20:174-179
70. Pavan-Langston D, Dunkel EC. Ocular varicella-zoster virus infection in the guinea pig: a new in vivo model. *Arch Ophthalmol* 1989;107:1068-1072
71. Linnemann C Jr, Alvira M. Pathogenesis of varicella-zoster angiitis in the CNS. *Arch Neurol* 1980;37:239-240