

Are your **MRI contrast agents** cost-effective?

Learn more about generic **Gadolinium-Based Contrast Agents**.



FRESENIUS
KABI

caring for life

AJNR

Balloon test occlusion of the internal carotid artery: change in stump pressure over 15 minutes and its correlation with xenon CT cerebral blood flow.

D W Barker, C A Jungreis, J A Horton, S Pentheny and T Lemley

This information is current as of April 19, 2024.

AJNR Am J Neuroradiol 1993, 14 (3) 587-590

<http://www.ajnr.org/content/14/3/587>

Balloon Test Occlusion of the Internal Carotid Artery: Change in Stump Pressure Over 15 Minutes and Its Correlation with Xenon CT Cerebral Blood Flow

David W. Barker,¹ Charles A. Jungreis,^{1,2} Joseph A. Horton,^{1,2} Susan Pentheny,¹ and Thomas Lemley¹

PURPOSE: To determine whether stump pressure changes significantly over time during temporary internal carotid artery (ICA) occlusion via an endovascular balloon, and to examine correlations between stump pressure changes and cerebral blood flow (CBF) as measured by xenon CT. **METHODS:** Seventy candidates for ICA sacrifice were evaluated preoperatively with a test occlusion of the cervical ICA using an endovascular balloon. Measurements of ICA stump pressure above the occlusive balloon through a distal lumen in the balloon catheter were made throughout the 15-minute test. During occlusion, CBF was measured with stable xenon CT techniques. Patients were then categorized according to CBF results. **RESULTS:** The stump pressure changed significantly ($P < .001$) during the occlusive period. On average, stump pressure increased 7.7 mmHg (12%). Patients determined by xenon CT to have an asymmetric decrease in CBF with balloon occlusion did not display the upward trend in stump pressures and were significantly different ($P = .013$) in that respect from patients who demonstrated either no CBF change or only minimal bilaterally symmetric decreases in CBF. **CONCLUSIONS:** Large overlaps among the groups prohibit the use of stump pressure changes as an accurate predictor of CBF or of stroke risk in an individual patient. However, these data suggest an autoregulatory mechanism in the cerebral circulation that evolves over a period of minutes in contrast to the traditional concept of cerebral autoregulation which is thought to occur in a matter of seconds.

Index terms: Arteries, carotid (internal); Cerebral blood flow; Computed tomography, xenon study; Interventional neuroradiology, provocative testing; Catheters and catheterization, balloons

AJNR 14:587-590, May/June 1993

Patients undergoing surgery for internal carotid artery (ICA) aneurysms or skull base tumors often require permanent occlusion of an ICA. Although the majority of patients tolerate the loss of one ICA, a significant percentage suffer either immediate or delayed neurologic deficits, presumably related to poor collateral circulation. To predict which patients will be unable to tolerate permanent ICA occlusion, we test patients preoperatively with temporary ICA occlusion using an endovascular balloon. This clinical test occlusion is coupled with a stable xenon computed tomography (CT) cerebral blood flow (CBF) measure-

ment (1-5). During the clinical 15-minute test period we have recorded serial stump pressures. The purpose of this study was to determine whether stump pressure changed significantly over time and to examine correlations between stump pressure changes and CBF as measured by xenon CT.

Materials and Methods

Following evaluation with CT, cerebral angiography, and a baseline neurologic exam, 70 carotid sacrifice candidates underwent a 15-minute test occlusion of the ICA. There were 41 men and 39 women with a mean age of 44 years (range, 2 to 68 years). Occlusion was achieved with a balloon-tipped 5-F double-lumen catheter (Swan-Ganz catheter, Baxter Healthcare, Santa Anna, CA or Occlusive Balloon catheter, Meditech, Watertown, MA) guided fluoroscopically to the ICA via the femoral artery. In this standard type of double-lumen catheter, one lumen is used for balloon inflation and the second lumen is a distal lumen extending beyond the balloon (Fig. 1). The distal lumen

Received May 7, 1991; accepted after revision July 3, 1992.

¹ Department of Radiology, Presbyterian University Hospital, Pittsburgh, PA 15213. Address reprint requests to Charles A. Jungreis, MD.

² Department of Neurological Surgery, Presbyterian University Hospital, Pittsburgh, PA 15213.

AJNR 14:587-590, May/Jan 1993 0195-6108/93/1403-0587

© American Society of Neuroradiology

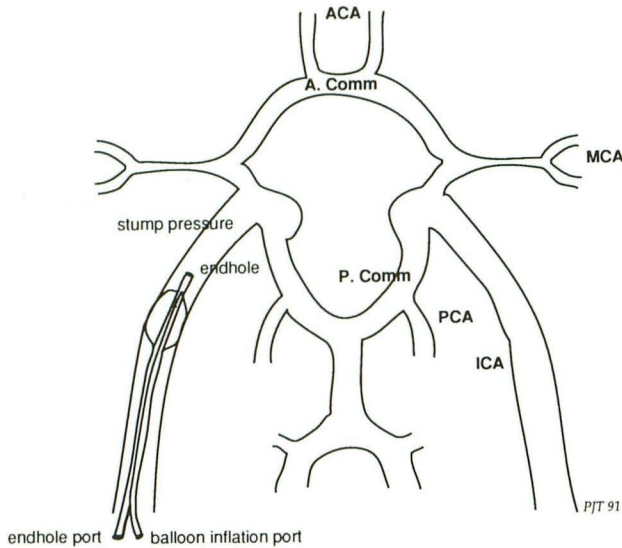


Fig. 1. Inflated balloon in the cervical portion of the ICA. One lumen of the catheter inflates the balloon, the other measures pressure in the carotid stump.

was connected to a pressure transducer and digital pressure monitor (Hewlett-Packard, Waltham, MA). Systemic (brachial) blood pressure was monitored with a Dinamap Automatic Sphygmomanometer (Critikon, Tampa, FL). After anticoagulation with intravenous heparin, the balloon was inflated. During the 15-minute clinical trial, systemic blood pressure, stump pressure (distal to the balloon), and neurologic status were monitored. Stump and systemic pressure readings were taken at either 2- or 3-minute intervals. Mean stump pressure change was determined by subtracting the initial pressure reading (taken just after balloon inflation) from the pressure reading taken at each successive time interval.

If the neurologic status remained stable during the test occlusion, the balloon was deflated and the patient was transported to the CT scanner. The balloon was then reinflated using the same volume and a two-level stable xenon CBF study was performed. Baseline CBF measurements were taken either before or after the balloon test, with sufficient time between the two exams to allow complete xenon washout. If any change in neurologic status occurred during occlusion, the balloon was immediately deflated and the study concluded. Such patients are not included in this report because no pressure or CBF data were accumulated.

The patients were next categorized into three groups according to xenon blood flow results (1). The first group of patients showed no change in CBF between baseline and occluded studies. The second group had small (usually less than 10 mL/100 gm/min) bilateral decreases in blood flow. The third group of patients had a unilateral decrease in CBF on the occluded side.

Results

On average, stump pressure increased 7.7 mmHg after 14 minutes of occlusion (Fig. 2).

With an average stump pressure of 62 mmHg immediately after balloon inflation, this represents an increase of 12%. Change in stump pressure was statistically significant ($P < .001$, one-sample Student *t* test). Change in stump pressure was independent of change in systemic blood pressure (Pearson correlation coefficient = 0.05).

Xenon CT CBF categorization of the 70 patients was as follows: 41 were group I (no decrease in CBF), 17 group II (mild bilateral decrease), and 12 group III (unilateral decrease on the occluded side). Comparison of the stump pressure changes based on CBF categories showed that group I and group II patients displayed an average increase of 9 mmHg (14%) and 10 mmHg (16%) respectively, while group III patients demonstrated no upward trend (Fig. 3).

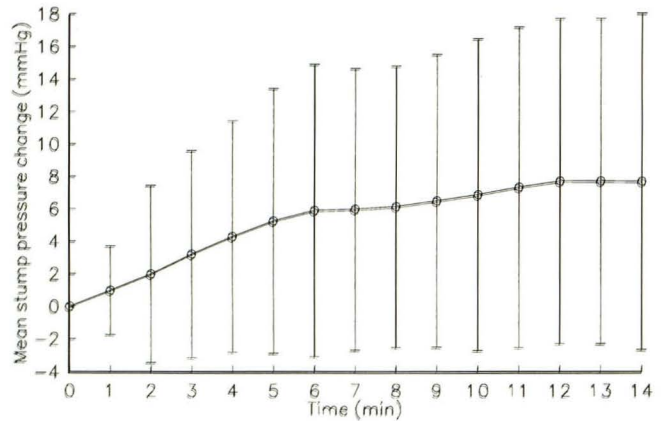


Fig. 2. Change in stump pressure after ICA occlusion. Average plot of all 70 patients. Change in stump pressure is significant at the end of 14 minutes ($P < .001$). Error bars indicate 1 standard deviation.

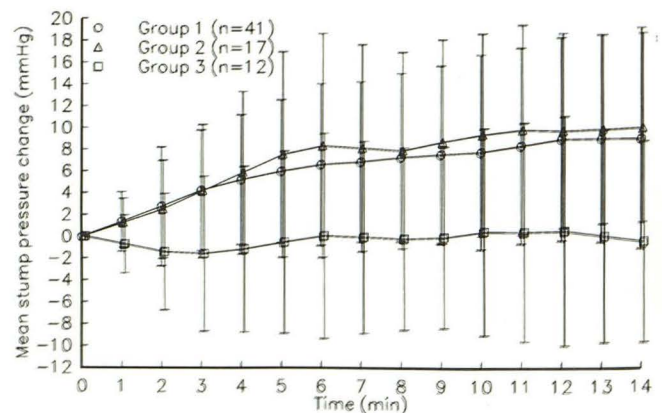


Fig. 3. Change in stump pressure after ICA occlusion. Patients categorized according to xenon CBF measurements. Group III patients are significantly different from group I and group II patients combined ($P = .013$). Error bars indicate 1 standard deviation.

Differences in stump pressure change between group I and group II patients combined versus group III patients were statistically significant ($P = .013$, two-tailed Student t test).

Discussion

Stump pressure measurements have been used as an assessment of cerebral cross-filling during ICA occlusion (6–8). Measurements have been taken immediately following occlusion, but not usually observed over time. One exception was Beebe et al (9), who reported changes in stump pressure during carotid endarterectomy. Because stump pressure measurements have proven to be poor predictors of stroke risk (10), we have employed a 15-minute clinical test occlusion and a xenon CT CBF study as a more reliable examination.

As a consequence of our routine, we have had the opportunity to monitor stump pressure throughout the 15-minute occlusion period. We have observed that many patients upon occlusion, after an initial drop in stump pressure from systemic levels, exhibit a gradual increase during the occlusive period to a relatively stable value, still below systemic pressure. Most of this increase occurs during the first 6 minutes of occlusion. Importantly, changes in systemic blood pressure do not correlate with changes in stump pressure.

Furthermore, upon retrospective analysis, we noted that group III patients (asymmetric CBF with occlusion) do not display this same trend and are significantly different ($P = .013$) from group I and group II patients. Although the differences are statistically significant, large overlaps among the groups preclude the use of stump-pressure change as a predictor of stroke in the individual patient.

What these findings do suggest is the presence of a compensatory mechanism in the cerebral circulation in addition to "traditional" autoregulation. Autoregulation, the ability to maintain constant blood flow despite changes in pressure, is generally thought to occur in a matter of seconds and is thought to be controlled via arterioles. In contrast, the response we are observing occurs over a period of minutes and likely involves collateral vessels, primarily those of the circle of Willis. Myogenic response times of this magnitude have been observed in isolated cerebral arteries of rats (11).

Group III patients, on average, do not demonstrate a rise in stump pressure. There are at least three explanations for this. The first is that some patients simply have an incomplete circle of Willis and lack other significant collaterals. A second explanation is that, although present, the collaterals are unable to dilate because of such causes as vasospasm, vasculitis, chronic hypertension, tumor encasement, or atherosclerosis. A third explanation is that, because of chronic demand for cross-flow, the collateral vessels are already maximally dilated.

One clinical consequence of our observation regards the use of SPECT (single photon emission CT) imaging during ICA test occlusion. If a stable state of cerebral perfusion during occlusion requires several minutes to develop, then the timing for the radiotracer injection becomes an important issue and perhaps should not take place immediately following occlusion. The stable xenon CT CBF method we employ has an inherent delay between balloon inflation and data acquisition of approximately 5 minutes and is therefore less sensitive to the early flow changes.

Potential pitfalls in our data may be from several sources. For example, PCO_2 , a strong determinant of CBF, was not monitored during the clinical portion of the occlusion test and conceivably could have varied causing alterations in CBF. Also, pressure measurements can be factitious if a catheter is partially occluded by the vessel wall or by the balloon itself. Kinking of a catheter can also occur. To control for these latter possibilities, a pressure tracing was observed during the measurements and should have remained pulsatile with a characteristic waveform. If it did not, then the catheter tip was repositioned slightly or the catheter lumen purged until satisfactory tracings returned. Inaccuracies can also occur from motion artifact during the xenon CT exam. This was not a significant problem. Finally, there is a period of time (approximately 30 minutes) between the acquisition of the pressure measurements and the acquisition of the blood flow data.

In summary, stump-pressure measurements during ICA occlusion indicate that stump pressure varies over time in some patients, increasing in that group of patients who display a normal CBF during occlusion. The stump-pressure increase was absent in the group with abnormal CBF (asymmetric low flow on the occluded side). The use of this information in an individual case is not helpful because of the large overlap among groups. However, trends in the data suggest a

compensatory mechanism in the cerebral circulation that evolves over a period of several minutes and represents a second level of cerebral autoregulation.

References

1. Erba SM, Horton JA, Latchaw RE, et al. Balloon test occlusion of the internal carotid artery with stable xenon/CT cerebral blood flow imaging. *AJNR: Am J Neuroradiol* 1988;9:533-538
2. Steed DL, Webster MW, DeVries EJ, et al. Clinical observations on the effect of carotid artery occlusion on cerebral blood flow mapped by xenon computed tomography and its correlation with carotid artery back pressure. *J Vasc Surg* 1990;11:38-43
3. Yonas H, Good WF, Gur D, et al. Mapping cerebral blood flow by xenon enhanced computed tomography: clinical experience. *Radiology* 1984;152:425-442
4. Gur D, Wolfson SK, Yonas H, et al. Progress in cerebral vascular disease: LCBF by xenon-enhanced CT. *Stroke* 1982;13:750-758
5. Gur D, Good WF, Wolfson SK Jr, Yonas H. In vivo mapping of local cerebral blood flow by xenon enhanced computed tomography. *Science* 1982;5:1267-1268
6. Matas R. Summary of meeting of the American Surgical Association. *Ann Surg* 1910;52:126-130
7. Hays RJ, Levinson SA, Wylie EJ. Intraoperative measurement of carotid back pressure as a guide to operative management for carotid endarterectomy. *Surgery* 1972;72:953-960
8. Hunter GC, Seiffert G, Malone JM, Moore WS. The accuracy of carotid back pressure as an index for shunt requirements: a reappraisal. *Stroke* 1982;13:319-326.
9. Beebe HG, Starr C, Slack D. Carotid artery stump pressure: its variability when measured serially. *J Cardiovasc Surg (Torino)* 1989;30:419-423
10. Kelly JJ, Callow AD, O'Donnell TF, et al. Failure of carotid stump pressures. *Arch Surg* 1979;114:1361-1366
11. Halpern W, Osol G. Influence of transmural pressure on myogenic responses of isolated cerebral arteries of the rat. *Ann Biomed Eng* 1985;13:287-294