

Are your **MRI contrast agents** cost-effective?

Learn more about generic **Gadolinium-Based Contrast Agents**.



FRESENIUS  
KABI

caring for life

**AJNR**

**Infected epidermoid cyst of the sphenoid bone.**

P A Bejarano, D F Broderick and M H Gado

*AJNR Am J Neuroradiol* 1993, 14 (3) 771-773

<http://www.ajnr.org/content/14/3/771>

This information is current as  
of April 19, 2024.

# Infected Epidermoid Cyst of the Sphenoid Bone

Pablo A. Bejarano,<sup>1</sup> Daniel F. Broderick,<sup>2</sup> and Mokhtar H. Gado<sup>2,3</sup>

**Summary:** An infected epidermoid cyst presented on CT as a primarily dense, sclerotic expansile lesion in the greater wing of the sphenoid bone. Presumably, infection was responsible for the atypical appearance.

**Index terms:** Epidermoid cyst; Sphenoid bone; Skull, computed tomography

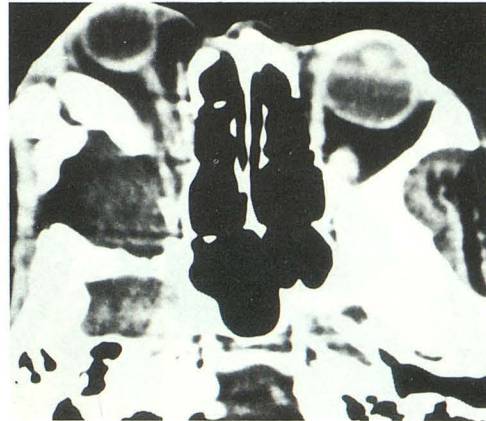Primary intradiploic cysts of the skull are rare, and are usually found in the frontal, parietal, and occipital bones (1). Two cases of epidermoid cyst located in the sphenoid bone have been reported in the literature: one located in the lesser wing (2) and the second in the greater wing of the sphenoid (3). The purpose of this report is to describe a third case of an epidermoid cyst in this unusual primary location and to describe its appearance, which has created diagnostic difficulties for several years.

## Case Report

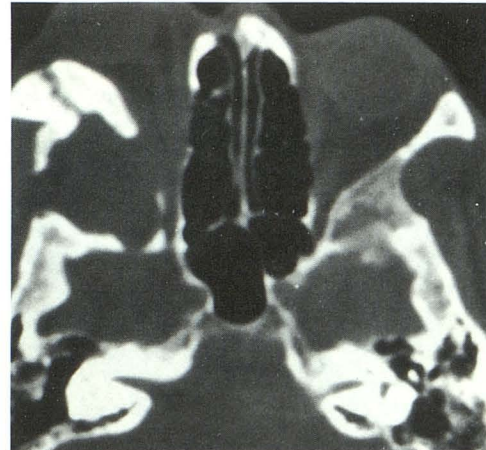The patient, a 71-year-old black woman, presented with a history of more than 30 years of painless, slowly progressing right eye proptosis and chronic sinusitis for which she had undergone frontal and sphenoid sinus surgery on four previous occasions. She recently complained of clear yellow pus draining from the external portion of the right eyelid. There was no loss of vision and no history of trauma.

Computed tomography (CT) scans showed a lesion centered on the greater wing of the right sphenoid bone with thickening, expansion, and dense sclerosis of the greater wing and a 4 × 2.5 × 3.6-cm central soft-tissue component. Multiple bone defects were shown (Fig. 1) and the bone changes extended into the zygoma and the roof of the orbit. The findings were interpreted as chronic osteomyelitis with abscess. Differential diagnoses of fibrous dysplasia and ossifying and nonossifying fibroma were considered. The appearances were similar to scans done 2 years earlier.

The patient was lost to follow-up for 2 years more and returned with clinical evidence of flare-up of infection (fever and periorbital pain) as well as rapid decrease in visual



A



B

Fig. 1. A, CT scan shows expansion and thickening of the greater sphenoid wing with central soft-tissue component.

B, Bone window display of same section as A. Note cortical disruption laterally and anterolaterally extending to the lateral orbital margin.

acuity and development of diplopia, trismus, tenderness, and fluctuance in the right frontal periorbital region. Draining at the lateral canthus of the right eye persisted. A repeat CT scan showed increase in proptosis and a new right lateral extraconal soft-tissue density with probable involve-

Received February 20, 1992; revision requested May 2; revision received June 20 and accepted July 23.

Departments of <sup>1</sup>Pathology and <sup>2</sup>Radiology, Barnes Hospital at Washington, University Medical Center, One Barnes Hospital Plaza, St. Louis, MO 63110.

<sup>3</sup> Address reprint requests to M. H. Gao, Mallinckrodt Institute of Radiology, Box 8131, St. Louis, MO 63110.

AJNR 14:771-773, May/June 1993 0195-6108/93/1403-0771 © American Society of Neuroradiology

ment of the lateral and superior rectus muscles (Fig. 2). She was diagnosed as having intraorbital extension of chronic osteomyelitis. At operation, the draining sinus and the cavity in the lateral orbital wall contained creamy yellow material. The affected bones were debrided. A culture from contents of the cavity grew *Peptostreptococcus* species.

Pathologic examination showed numerous strips of squamous epithelium featuring a granular layer and deposits of laminated keratin (Fig. 2B) resting on a loose vascular

fibroconnective tissue. Focal acute and chronic inflammation with multinucleated giant cells was considered a reaction to the debris of keratin. With the exception of small fragments of calcification and bone, attributable to pressure and erosion by the cyst, the findings were identical to those seen in the more frequently encountered epidermoid cyst of the skin. There were no pilosebaceous structures or eccrine sweat glands nor evidence of fibrous dysplasia or ossifying fibroma or malignancy.

Postoperatively, the fistulous tract, diplopia ectropion, and keratopathy resolved in 2 months.

## Discussion

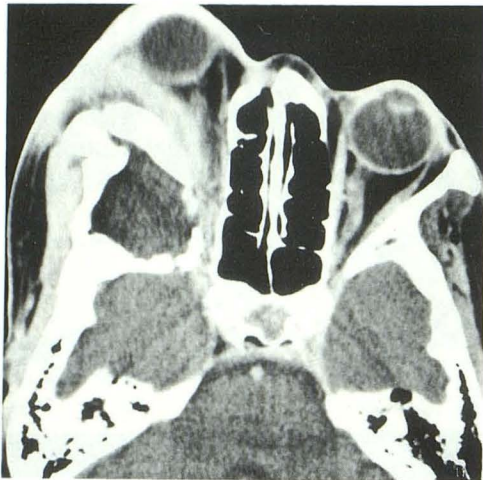
Epidermoid cysts are cavities lined by squamous epithelium. They differ from dermoid cysts in having a distinct granular layer and containing laminated keratin. Dermoid cysts lack a granular layer and contain cutaneous adnexa. Epidermoid cysts of the skull are very uncommon. Recently, world literature including non-English literature was reported to contain a total of 223 cases (1). They are slow-growing lesions with a variable clinical presentation depending on their location and size. The lesion may be seen as an incidental finding on radiographic examination of the skull (2).

Neither of the two previously reported epidermoid cysts of the skull involving the sphenoid bone was associated with proptosis. In one report of a 3½-year-old boy, a 1.5-cm. lesion in the lesser wing was an incidental finding with the typical features on a skull radiograph (2). In the second report, a 5 × 3 × 4-cm lesion in the greater wing showed typical features on CT in a 43-year-old woman with a grand mal seizure (3).

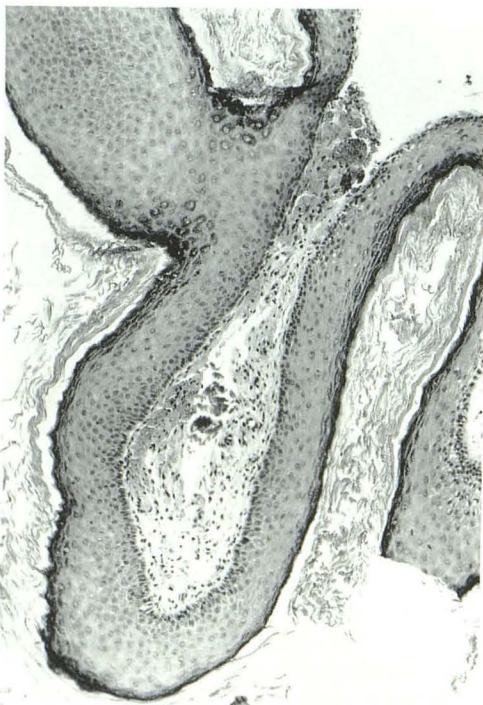On the other hand, there are two previously reported cases of intraorbital epidermoid cyst associated with proptosis (4, 5). Although not clearly stated, it is probable that the sphenoid wing was involved in both cases.

There are three theories on the pathogenesis of the epidermoid cyst of the skull: congenital origin, metaplasia, and trauma. A congenital origin is a possible explanation in our case. Entrapment of epithelial rests of ectodermal origin within the fusion plates between the different chondrification centers of the alisphenoid and presphenoid bones in the embryo could result in the formation of an intradiploic cyst of the sphenoid bone (6).

Alterations in the pneumatization process or retention of displaced epithelial nests within the frontal or sphenoid sinus, which are in themselves intradiploic, may explain the development of intrasinus epidermoids. The normally present cili-



A



B

Fig. 2. A, CT scan 2 years after Figure 1 shows proptosis and an extraconal soft-tissue mass with probable involvement of the lateral rectus muscle. Involvement of the superior rectus muscle (data not shown) was suspected.

B, Histology of epidermoid cyst. The cyst wall is lined by stratified squamous epithelium with a well-formed granular layer (hematoxylineosin, ×100).

ated respiratory epithelium of the paranasal sinuses may undergo metaplastic changes towards squamous epithelium as a result of infection or chronic inflammation and so set the grounds for the formation of an epidermoid cyst. However, this process would not explain the origin of intracranial cysts unrelated to the paranasal sinuses (3). Implantation of squamous epithelium within the bone after trauma was proposed by Toglia (7), but a history of trauma is not always obtained. Because our patient did not have history of trauma, a congenital origin seems more likely.

The typical radiologic features of diploic epidermoid cysts (2, 8, 9) are a round or oval radiolucency and a sharply defined sclerotic rim that may be scalloped or lobulated. The sclerotic rim may be blurred by inflammation or reabsorbed by the rapid growth of the cyst and, therefore, may not be evident. When completely intradiploic, the lesion may cause expansion and erosion of the outer and occasionally the inner tables of the skull.

In our case, the CT findings of an epidermoid cyst were masked by bone thickening and dense sclerosis extending beyond the cystic component. Infection of the epidermoid cyst was responsible for this atypical appearance which, together with the unusual location, leads to the diagnosis of osteomyelitis and no consideration of an underlying infected epidermoid cyst. Fibrous dysplasia of the skull can also give a sclerotic, pagetoid, or cystic appearance with

widened diploic spaces, osseous expansion, and poorly defined sclerosis, whereas cystic changes are less common (10).

We recommend that the possibility of an infected epidermoid cyst be considered in the differential diagnosis of a sclerotic expansile lesion of the greater wing of the sphenoid with central lucency.

## References

1. Ciappetta P, Artico M, Salvati M, Raco A, Gagliardi FM. Intradiploic epidermoid cysts of the skull: report of 10 cases and review of the literature. *Acta Neurochir (Wien)* 1990;102:33-37
2. Skandalakis JE, Godwin JT, Mabon RF. Epidermoid cyst of the skull. *Surgery* 1958;43:990-1001
3. White AK, Jenkins HA, Coker NJ. Intradiploic epidermoid cyst of the sphenoid wing. *Arch Otolaryngol Head Neck Surg* 1987;113:995-999
4. MacCarty CS, Leavens ME, Love JG, Kernohan JW. Dermoid and epidermoid tumors in the central nervous system of adults. *Surg Gynecol Obstet* 1959;108:191-198
5. Rubin G, Scienza R, Pasqualin A, Rosta L, Da Pian R. Craniocerebral epidermoids and dermoids. *Acta Neurochir (Wien)* 1989;97:1-16
6. Sperber GH. The cranial base. In: Derrick DD, ed. *Craniofacial embryology*. London: Wright, 1989:101-118
7. Toglia JU, Netsky MG, Alexander E Jr. Epithelial (epidermoid) tumors of the cranium. *J Neurosurg* 1965;23:384-393
8. Holthusen W, Lassrich MA, Steiner C. Epidermoids and dermoids of the calvarian bones in early childhood: their behaviour in the growing skull. *Pediatr Radiol* 1983;13:189-194
9. Garcia J, Lagier R, Hoessly M. Computed tomography-pathology correlation in skull epidermoid cyst. *J Comput Assist Tomogr* 1982;6:818-820
10. Fries JW. The roentgen feature of fibrous dysplasia of the skull and facial bones. *AJR: Am J Roentgenol* 1957;77:71-88