Are your MRI contrast agents cost-effective?
Learn more about generic Gadolinium-Based Contrast Agents.
FRESENIUS KABI
caring for life

AJNR

Menkes kinky hair disease: characteristic MR angiographic findings.

D S Jacobs, A S Smith, D A Finelli, C F Lanzieri and M Wiznitzer

AJNR Am J Neuroradiol 1993, 14 (5) 1160-1163
http://www.ajnr.org/content/14/5/1160

This information is current as of April 17, 2024.

Menkes Kinky Hair Disease: Characteristic MR Angiographic Findings

David S. Jacobs,[1] Alison S. Smith,[1] Daniel A. Finelli,[1] Charles F. Lanzieri,[1] and Max Wiznitzer[2]

Summary: We report two cases of Menkes kinky hair disease in which MR and MR angiography were performed. The clinical and imaging features are reviewed. MR demonstrated characteristic cerebrovascular tortuousity and thus may be a valuable aid in diagnosis and follow-up.

Index terms: Menkes syndrome; Magnetic resonance angiography (MRA); Pediatric neuroradiology

Menkes kinky hair disease is a rare, X-linked disorder manifested by mental retardation, arrested motor development, seizures, and hypothermia. The disorder was first described by Menkes et al in 1962 (1). These infants usually present with unexplained hypothermia, hypotonia, and seizures with progressive neurologic deterioration. Scalp hair is hypopigmented with characteristic kinking and friability. Levels of copper and ceruloplasmin (a copper transport enzyme) in serum are abnormally low (2). Abnormal copper utilization is thought to be the underlying defect. The diagnosis is sometimes delayed for weeks to months because copper/ceruloplasmin levels are normally low in the first few weeks of life. In addition, the primary fetal hair may be normal, so the hair abnormalities may not be apparent early (3, 4).

Patient 1

This male patient was the product of a full-term delivery. He was admitted to an outside hospital at 3 weeks of age with prolonged tonic-clonic seizures. Magnetic resonance (MR) showed minimal signal abnormality in the left sylvian region. An electroencephalogram was abnormal, but basic blood chemistries were unremarkable. At 5 months of age, he was admitted to our hospital with a 3-day history of excessive somnolence and poor eating. He was found to be hypothermic and lethargic and had unusually coarse hair. His complete blood count, blood chemistries, and cerebrospinal fluid were all normal. He was treated for presumed dehydration, hypothermia, and sepsis with minimal improvement. A neurologic consultation led to the suspicion of Menkes kinky hair disease. Copper and ceruloplasmin levels in serum were 11 μg/dL (normal, 70 to 125 μg/dL) and <1 mg/dL (normal, 18 to 45 mg/dL), respectively, confirming the diagnosis. Copper histidine therapy was started but was given sporadically because of poor parental compliance. At 18 months of age, he presented with increasing seizure activity. MR was performed and showed severe cerebral and cerebellar atrophy, diffusely deficient myelinization, and bilateral subdural fluid collections (Fig. 1A–1C). MR angiography (MRA) was done. It demonstrated bizarre, tortuous intracranial arteries (Fig. 1D and 1E).

Patient 2

This male child was the product of a normal delivery and had an unremarkable neonatal course. At 2 months of age, he was admitted to an outside hospital because of somnolence, weight loss, and dehydration. He was hypothermic and hypotonic, with unusually coarse hair. An extensive evaluation revealed abnormally low copper and ceruloplasmin levels, resulting in a diagnosis of Menkes kinky hair disease. He was placed on copper histidine therapy. His course was complicated by subsequent generalized seizures. He later required numerous hospital admissions for dehydration and sepsis. At 10.5 months of age, he was admitted to the hospital with severe diarrhea, poor skin turgor, and fever and was treated for dehydration and sepsis. Because of his increasing lethargy and seizures, MR was performed; it showed moderate cerebral and cerebellar atrophy and deficient myelinization, particularly in the centrum semiovale, the anterior and posterior periventricular white matter, and the internal capsules. MRA was also done for evaluation of the arteriopathy and showed marked tortuosity of the major intracranial arteries (Fig. 2). The patient did well after hydration and antibiotic therapy and was released. At 4 years of age, he functions at the level of a 3 month old.

Received June 30, 1992; revision requested August 20; revision received November 16 and accepted November 23.

Presented at the 30th Annual Meeting of the ASNR, St. Louis, MO, May 1992.

Departments of [1]Radiology and [2]Pediatric Neurology, University Hospitals of Cleveland, 2074 Abington Road, Cleveland, OH 44106. Address requests for reprints to David S. Jacobs, MD.

AJNR 14:1160–1163, Sep/Oct 1993 0195-6108/93/1405-1160 © American Society of Neuroradiology

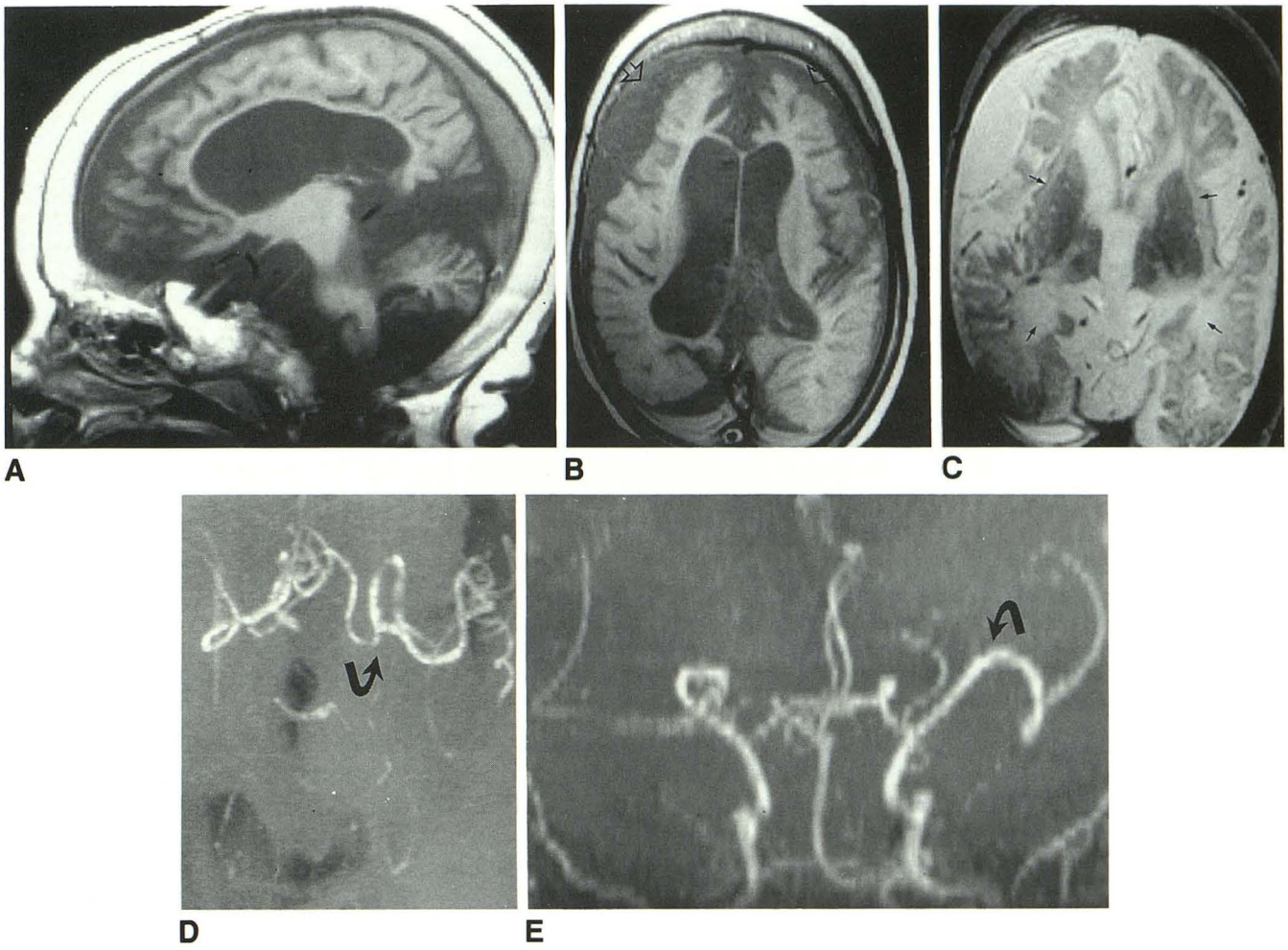

Fig. 1. Eighteen-month-old boy with Menkes disease.

A and *B*, Sagittal and axial T1-weighted images show diffuse cerebral and cerebellar atrophy. Bilateral subdural collections (*arrows*) are present.

C, Axial T2-weighted image shows deficient myelinization in the small amount of white matter that is present (*arrows*).

D and *E*, Axial and coronal MRA (three-dimensional fast imaging with steady precession time of flight 13/35/8 [TR/TE/excitations]) show markedly tortuous intracranial arteries (*arrows*).

Discussion

Children with Menkes disease cannot absorb orally administered copper properly. The copper that is present in the body is maldistributed, abnormally low in some tissues and elevated in others. On the basis of these findings, an abnormality of copper transport through cellular compartments is postulated, although the exact defect has not been elucidated. The copper transport and storage abnormality results in several important cerebrovascular findings. Extensive gray and associated white matter loss occurs; the cerebellar Purkinje fibers are especially affected (5, 6). Diffuse myelin deficiency is an associated finding. Subdural hematomas and hygromas occur frequently, presumably as the result of shearing of the bridging cortical veins as atrophy progresses.

One striking finding in children with Menkes disease is bizarre elongation and tortuosity of the intracranial vasculature. Microscopically, distortion of arteries and variation in wall thickness are found. Systemic arteries show extensive fragmentation, beading, and splitting. Intimal hyperplasia occurs, and abnormal elastic fibers form within the intima (2). These changes in elasticity are presumably the cause of vascular stretching and dilation—findings that have been described on angiography (7, 8) and on spin-echo MR (9–12) but not, to our knowledge, on MRA.

Cerebral atrophy and extracerebral collections are fairly nonspecific findings that can be seen in

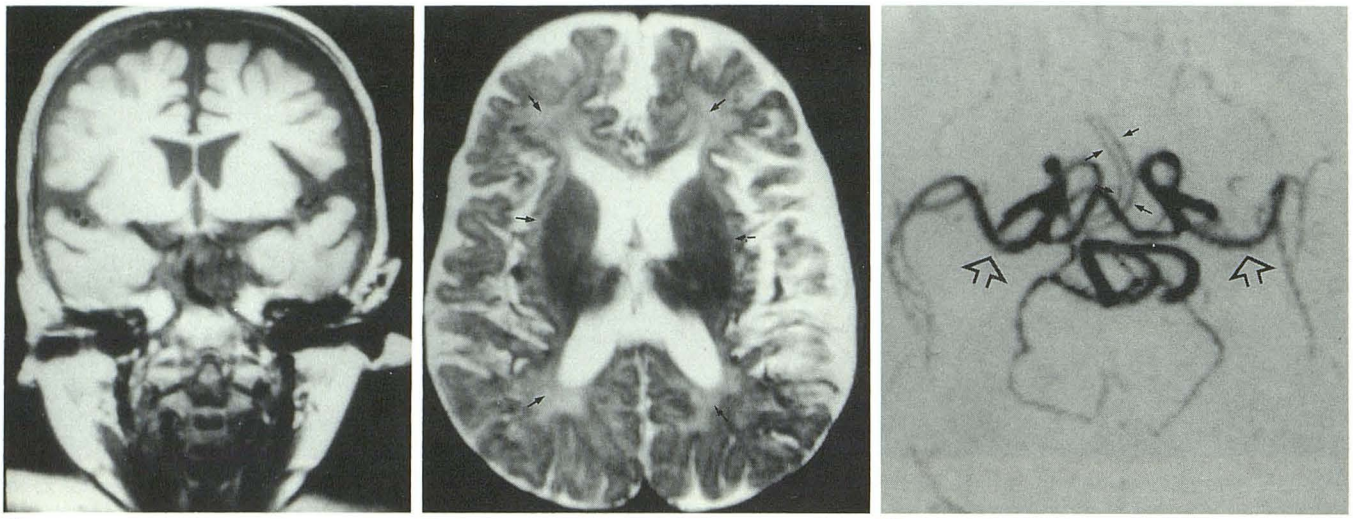

Fig. 2. Ten-and-a-half month old with Menkes disease.
A, coronal T1-weighted MR shows moderate global atrophy.
B, axial T2-weighted MR demonstrates deficient myelinization in the white matter (*arrows*).
C, axial MRA (three-dimensional fast imaging with steady precession time-of-flight 15/40) shows tortuous anterior (*closed arrows*) and middle (*open arrows*) cerebral arteries.

numerous conditions, including inherited metabolic disorders (13), postmeningitis/encephalitis, and child abuse. Extensive arterial tortuosity, in combination with the above findings, however, is characteristic for Menkes disease. These vascular irregularities are more clearly demonstrated on MRA than on spin-echo imaging. MRA thus becomes a valuable aid in the diagnosis of this disorder. This becomes particularly important because the characteristic clinical and laboratory features may not be present in the neonatal period, and diagnosis may be delayed for weeks to months.

Early work on the angiography of childhood atrophy does not describe arterial tortuosity as a feature (14). However, recent anedoctal (unpublished) reports have indicated that arterial tortuosity may, in fact, be a feature of a severe atrophy. This could theoretically occur as vessels are pulled and stretched as the brain shrinks. If true, the specificity of this finding for Menkes disease would be diminished. Clearly, MRA studies on other atrophy-producing pediatric entities, such as the leukodystrophies, mucupolysaccharidoses, severe anoxic events, and Sturge-Weber disease, would therefore be of interest.

MRA may also become important as a noninvasive mode of following the progressive neurovascular changes in this disease, particularly because serial standard angiography is not well accepted by parents of young children. It has been postulated that the cerebral atrophy and myelin deficiency may be the result of the arteriopathy (13). The correlation of serial MRA with progressive MR changes of atrophy and myelin disease would therefore be of interest. As MRA techniques improve, not only will the gross morphology of the arteries be apparent, but more subtle intimal changes will be detected.

In conclusion, MRA may be a useful adjunctive diagnostic procedure in infants with unexplained hyporthermia and progressive neurologic deterioration. We believe that MRA may also be substituted for conventional angiography in demonstrating the characteristic findings of Menkes disease.

References

1. Menkes JH, Alter M, Steigleder GK, Weakley DR, Sung JH. A sex-linked recessive disorder with growth retardation, peculiar hair, and focal cerebral and cerebellar degeneration. *Pediatrics* 1962;29:764–779
2. Danks DM, Campbell PE, Stevens BJ, Mayne V, Cartwright E. Menkes kinky hair syndrome. An inherited defect in copper absorption with widespread effects. *Pediatrics* 1972;50:188–201
3. Menkes JH. Kinky hair disease: twenty five years later. *Brain Dev* 1988;10:77–79
4. Gunn TR, Macfarlane S, Phillips LI. Difficulties in the neo-natal diagnosis of Menkes kinky hair syndrome—trichopoliodystrophy. *Clin Pediatr* 1984;23:514–516
5. Hirano A, Llena JF, French JH, Ghatak NR. Fine structure of the cerebellar cortex in Menkes kinky hair disease. *Arch Neurol* 1977;34:52–56
6. Okeda R, Gei S, Chen I, Okaniwa M, Shinomiya M, Matsubara O. Menkes' kinky hair disease: morphological and immunohistochemical

comparison of two autopsied patients. *Acta Neuropathol* 1991;81:450–457
7. Wesenberg RL, Gwinn JL, Barnes GR. Radiologic findings in the kinky hair syndrome. *Radiology* 1969;92:500–506
8. Ahlgren P, Vestermark S. Menkes kinky hair disease. *Neuroradiology* 1977;13:159–163
9. Faerber EN, Grover WD, Defiupp GJ, Capitanio MA, Liv TH, Swartz JD. Cerebral MR of Menkes kinky hair disease. *AJNR: Am J Neuroradiol* 1989;10:190–192
10. Ichihashi K, Yano S, Kobayashi S, Miyao M, Yanagisawa M. Serial imaging of Menkes disease. *Neuroradiology* 1990;32:56–59
11. Blaser SI, Berns DH, Ross JS, Lanska MJ, Weissman BM. Serial MR studies in Menkes disease. *J Comput Assist Tomogr* 1989;13:113–115
12. Johnsen DE, Coleman L, Poe L. MR of progressive neurodegenerative change in treated Menkes' kinky hair disease. *Neuroradiology* 1991;33:181–182
13. Kendall BE. Disorders of lysosomes, peroxisomes, and mitochondria. *AJNR: Am J Neuroradiol* 1992;13:621–653
14. Taveras JM, Poser CM. Roentgenologic aspects of cerebral angiography in children. *Am J Roentgenol Radium Ther Nucl Med* 1959;82:371–391