Are your MRI contrast agents cost-effective?
Learn more about generic Gadolinium-Based Contrast Agents.
FRESENIUS KABI
caring for life

AJNR

MR of acute subarachnoid hemorrhage: a preliminary report of fluid-attenuated inversion-recovery pulse sequences.

K Noguchi, T Ogawa, A Inugami, H Toyoshima, T Okudera and K Uemura

AJNR Am J Neuroradiol 1994, 15 (10) 1940-1943
http://www.ajnr.org/content/15/10/1940

This information is current as of April 19, 2024.

MR of Acute Subarachnoid Hemorrhage: A Preliminary Report of Fluid-Attenuated Inversion-Recovery Pulse Sequences

Kyo Noguchi, Toshihide Ogawa, Atsushi Inugami, Hideto Toyoshima, Toshio Okudera, and Kazuo Uemura

Summary: We report preliminary results applying fluid-attenuated inversion-recovery (FLAIR) sequences to three patients with acute subarachnoid hemorrhage. Acute subarachnoid hemorrhage could be clearly demonstrated as areas of high signal intensity on FLAIR sequences in all patients. These preliminary results suggest that with FLAIR sequences one could reliably diagnose acute subarachnoid hemorrhage.

Index terms: Subarachnoid space, hemorrhage; Magnetic resonance, technique

A fluid-attenuated inversion-recovery (FLAIR) sequence nulls the signal from cerebrospinal fluid (CSF) and produces very heavy T2 weighting as a consequence of its very long echo time. It has been reported that FLAIR sequences provide high sensitivity to a wide range of central nervous system disease, such as multiple sclerosis, small cortical infarctions and metastatic tumors (1–3). We report the preliminary results of FLAIR sequences applied to three patients with acute subarachnoid hemorrhage.

Case Reports

We performed magnetic resonance (MR) imaging with a FLAIR sequence (5000/120/1 [repetition time/echo time/excitation], inversion time 2000) for three patients with subarachnoid hemorrhage within 5 hours after onset. We used a 0.5-T superconducting MR unit (SMT-50X, Shimadzu, Kyoto, Japan). FLAIR imaging was performed as a research study to evaluate the usefulness of the FLAIR sequence for the diagnosis of acute subarachnoid hemorrhage. Therefore, informed consent was obtained from the patients or their relatives. Because acute subarachnoid hemorrhage is difficult to detect with standard T1- and T2-weighted images (4–7), we obtained FLAIR images only after diagnosing subarachnoid hemorrhage by computed tomography (CT) scan.

Case 1

A 68-year-old woman with sudden onset of severe headache was transferred to our hospital by ambulance. A CT scan obtained 4 hours after the ictus clearly showed subarachnoid hemorrhage in the right sylvian fissure and suprasellar cistern (Figs 1A and B). MR imaging with a FLAIR sequence obtained 5 hours after the ictus also showed subarachnoid hemorrhage as areas of high signal intensity relative to CSF and surrounding brain parenchyma (Figs 1C and D). Four-vessel angiography revealed a saccular aneurysm of the right middle cerebral artery. Surgery confirmed subarachnoid hemorrhage in the right sylvian fissure and the ruptured right middle cerebral artery aneurysm.

Case 2

A 30-year-old woman with severe headache and vomiting was transferred to our hospital by ambulance. CT scan obtained 3.5 hours after the ictus showed subarachnoid hemorrhage mainly involving the left sylvian fissure (Fig 2A). MR imaging with a FLAIR sequence obtained 4 hours after the ictus also showed subarachnoid hemorrhage as areas of high signal intensity (Fig 2B). Four-vessel angiography revealed a saccular aneurysm of the left middle cerebral artery. Subarachnoid hemorrhage caused by the ruptured left middle cerebral artery aneurysm was confirmed at surgery.

Case 3

A 68-year-old man was admitted to our hospital with sudden severe headache and vomiting. CT scan obtained 1 hour after the ictus showed subarachnoid hemorrhage in the anterior interhemispheric fissure and left sylvian fissure. MR imaging with a FLAIR sequence obtained 2 hours after the ictus revealed high signal intensity in the bilateral sylvian fissures and quadrigeminal cistern. Four-vessel angiography showed a saccular aneurysm of the anterior communicating artery. Subarachnoid hemorrhage caused

Received March 8, 1994; accepted after revision June 20.

From the Department of Radiology and Nuclear Medicine, Research Institute of Brain and Blood Vessels, Akita, Japan.

Address reprint requests to Kyo Noguchi, Department of Radiology and Nuclear Medicine, Research Institute of Brain and Blood Vessels-Akita, 6-10, Senshu-kubota-machi, Akita City, 010, Akita, Japan.

AJNR 15:1940–1943, Nov 1994 0195-6108/94/1510–1940

© American Society of Neuroradiology

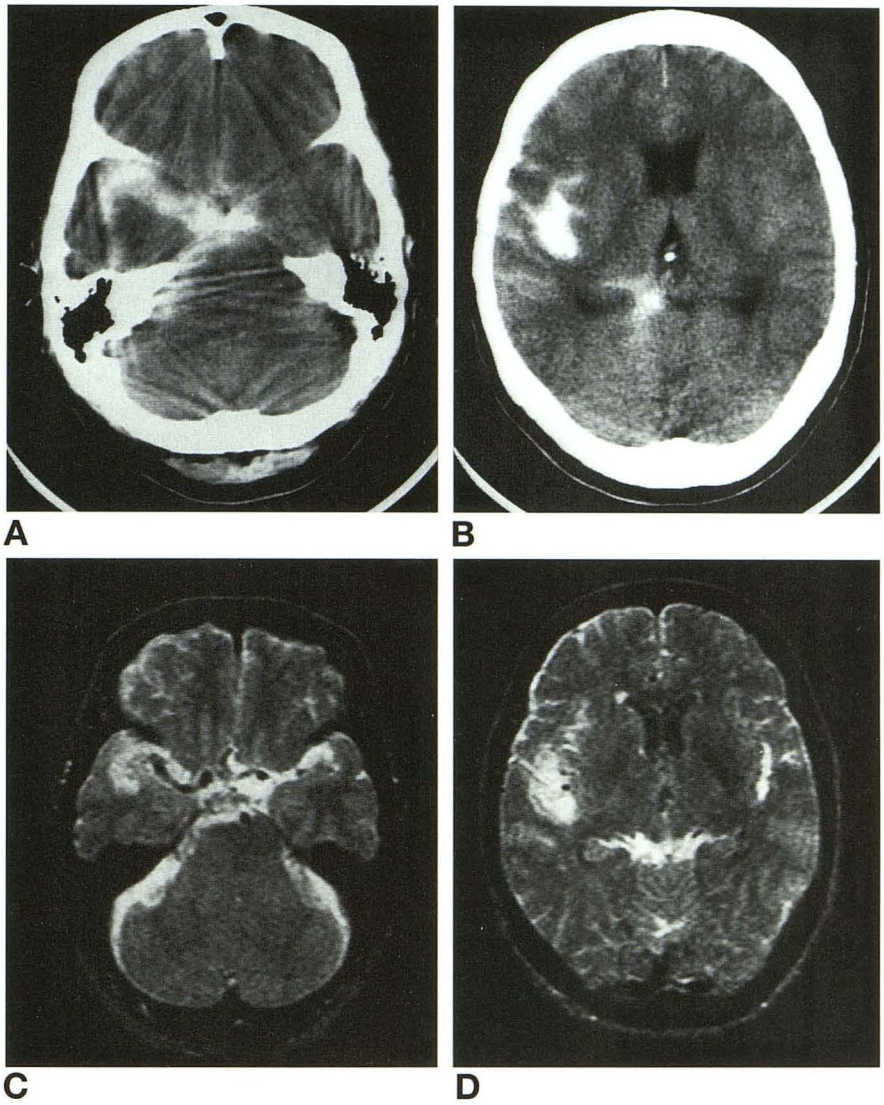

Fig 1. Case 1.

A and *B*, CT scans clearly show subarachnoid hemorrhage as high-attenuated areas in the suprasellar cistern, right sylvian vallecula, right sylvian fissure, right cerebellopontine angle cistern, and right retropulvinar cistern.

C and *D*, MR images with a FLAIR sequence show subarachnoid hemorrhage as areas of high signal intensity relative to CSF and brain parenchyma. Especially, subarachnoid hemorrhage in the left sylvian fissure and left cerebellopontine angle cistern is more clearly seen than on CT scans.

by the ruptured anterior communicating artery aneurysm was confirmed at surgery.

Discussion

It is generally accepted that acute subarachnoid hemorrhage is difficult to detect with MR imaging because fresh blood causes little change in the signal characteristics of CSF (4–7). However, some reports have shown that acute subarachnoid hemorrhage can be reliably demonstrated with MR imaging if the appropriate parameters are applied (8–11). Ogawa et al reported that the T1 relaxation time of acute subarachnoid hemorrhage was markedly shorter than that of normal CSF and longer than that of gray matter, and the T2 relaxation time of acute subarachnoid hemorrhage was moderately shorter than that of normal CSF and moderately longer than that of gray matter. In their reports of using a 0.5-T MR unit, proton density–weighted images and moderately T2-weighted images were suited for the demonstration of acute subarachnoid hemorrhage (11).

The FLAIR sequence is an inversion-recovery pulse sequence designed to null or greatly reduce the signal from CSF; it enables very heavy T2 weighting without very high signal and potential artifacts from CSF. However, although signal from normal CSF is reduced on this FLAIR sequence, there is still increased signal from bloody CSF because of shortening of the T1 relaxation time. Thus acute subarachnoid hemorrhage is seen as hyperintense relative to normal CSF. On the other hand, the T2 relaxation time of acute subarachnoid hemorrhage is longer than that of gray matter,

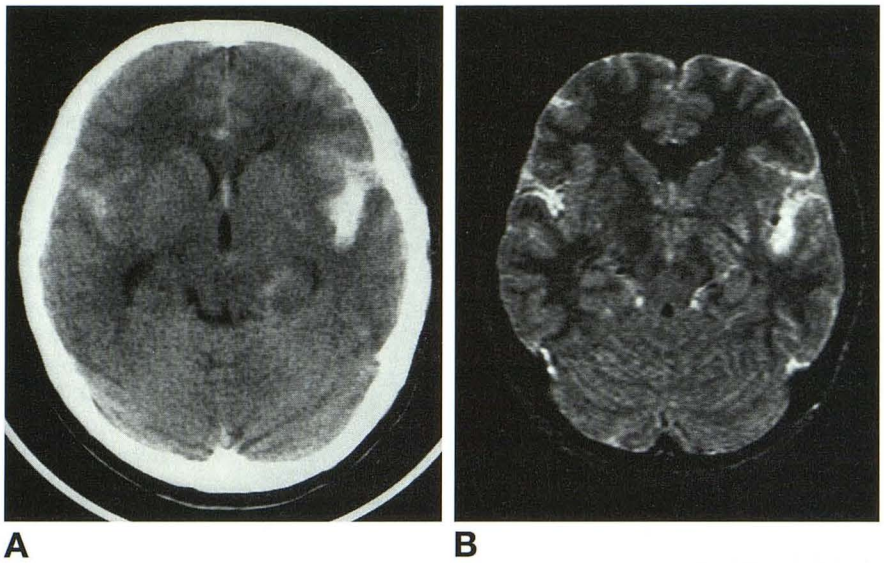

Fig 2. Case 2.

A, CT scan shows subarachnoid hemorrhage in the bilateral sylvian fissures, left ambient cistern, and anterior interhemispheric fissure.

B, MR image with a FLAIR sequence shows subarachnoid hemorrhage as areas of high signal intensity relative to CSF and brain parenchyma. Subarachnoid hemorrhage in the right ambient cistern and bilateral frontal cortical sulci are more clearly demonstrated than on CT scan.

and acute subarachnoid hemorrhage can be seen as hyperintense relative to gray matter if a long echo time is selected on the FLAIR sequence.

Whether acute subarachnoid hemorrhage can be seen on a CT scan depends only on attenuation values of bloody CSF. Conversely, on MR imaging, it depends mainly on the differences of the relaxation times among acute subarachnoid hemorrhage, CSF, and surrounding brain parenchyma. Chakeres and Bryan have reported that identification of acute subarachnoid hemorrhage will be theoretically much easier with MR than with CT because of the marked relaxation time differences of normal and bloody CSF (12). Our cases support this and show that acute subarachnoid hemorrhage can be reliably demonstrated as hyperintense relative to CSF and surrounding gray matter using a FLAIR sequence. This sequence was especially suited for the visualization of acute subarachnoid hemorrhage in the posterior fossa, which was difficult to demonstrate on CT because of beam-hardening artifact.

MR findings of intracranial hemorrhage are complex and controversial. The sequential degradation of hemoglobin was initially emphasized as a major factor determining MR appearance of evolving intracerebral hemorrhage (13). Because we examined within 2 to 5 hours of the onset of subarachnoid hemorrhage in this study, the blood is presumably in oxyhemoglobin form. With longer delays between time of ictus and MR imaging, the blood would evolve in the form of deoxyhemoglobin or intracellular methemoglobin. We can suspect that these forms of subarachnoid blood might result in markedly diminished signal on heavily T2-weighted imaging and could thus potentially be obscured on a CSF-suppression sequence. However, subarachnoid hemorrhage differs from intraparenchymal hemorrhage in that it is mixed with CSF. Subarachnoid hemorrhage has high ambient oxygen levels, and thus "age" advances more slowly than that of intraparenchymal hemorrhage (14). Moreover, protein concentration effect is also recognized as an additional important factor that may influence the MR signal intensity of intracerebral hemorrhage (15). Therefore, it remains to be elucidated whether late acute subarachnoid hemorrhage can be demonstrated as areas of high signal intensity on the FLAIR sequences.

In conclusion, although CT is still a modality of choice for diagnosing acute subarachnoid hemorrhage at present, it is also true that acute subarachnoid hemorrhage can be reliably detected with MR by selecting appropriate parameters. The usefulness of the FLAIR sequence for the diagnosis of acute subarachnoid hemorrhage remains to be shown in more cases.

References

1. Coene BD, Hajnal JV, Gatehouse P, et al. MR of the brain using fluid-attenuated inversion recovery (FLAIR) pulse sequences. *AJNR Am J Neuroradiol* 1992;13:1555–1564
2. Coene BD, Hajnal JV, Pennock JM, Bydder GM. MRI of the brain stem using fluid attenuated inversion recovery pulse sequences. *Neuroradiology* 1993;35:327–331

3. Tomas DJ, Pennock JM, Hajnal JV, Young IR, Bydder GM, Steiner RE. Magnetic resonance imaging of spinal cord in multiple sclerosis by fluid-attenuated inversion recovery. *Lancet* 1993;341: 593–594
4. Bradley WG, Schmit PG. Effect of methemoglobin formation on the MR appearance of subarachnoid hemorrhage. *Radiology* 1985;156:99–103
5. Zimmerman RD, Heier LA, Snow RB, Liu DPC, Kelly AB, Deck MDF. Acute intracranial hemorrhage: intensity changes on sequential MR scans at 0.5 T. *AJNR Am J Neuroradiol* 1988;9: 47–57
6. Davis JM, Hesselink JR. Vascular lesions: intracerebral hemorrhage. In: Taveras JM, Ferrucci JT, eds. *Radiology: Diagnosis-Imaging-Intervention.* Philadelphia: JB Lippincott, 1988:1–15
7. Grossman RI. Magnetic resonance imaging of hemorrhage. In: Taveras JM, Ferrucci JT, eds. *Radiology: Diagnosis-Imaging-Intervention.* Philadelphia: JB Lippincott, 1990:1–13
8. Matsumura K, Matsuda M, Handa J, Todo G. Magnetic resonance imaging with aneurysmal subarachnoid hemorrhage: comparison with computed tomography scan. *Surg Neurol* 1990;34:71–78
9. Sato S, Kadoya S. Magnetic resonance imaging of subarachnoid hemorrhage. *Neuroradiology* 1988;30:361–366
10. Jenkins A, Hadley DM, Teasdale GM, et al. Magnetic resonance imaging of acute subarachnoid hemorrhage. *J Neurosurg* 1988; 68:731–736
11. Ogawa T, Inugami A, Shimosegawa E, et al. Subarachnoid hemorrhage: evaluation with MR imaging. *Radiology* 1993;186:345–351
12. Chakeres DW, Bryan RN. Acute subarachnoid hemorrhage: in vitro comparison of magnetic resonance and computed tomography. *AJNR Am J Neuroradiol* 1986;7:223–228
13. Gomori JM, Grossman RI, Goldberg HI, Zimerman RA, Bilaniuk LT. Intracranial hematomas: imaging by high-field MR. *Radiology* 1985;157:87–93
14. Bradley WG. MR appearance of hemorrhage in the brain. *Radiology* 1993;189:15–26
15. Hayman LA, Tuber KH, Ford JJ, Bryan RN. Mechanisms of MR signal alteration by acute intracerebral blood: old concepts and new theories. *AJNR Am J Neuroradiol* 1991;12:899–907