

Are your **MRI contrast agents** cost-effective?

Learn more about generic **Gadolinium-Based Contrast Agents**.



FRESENIUS
KABI

caring for life

AJNR

Giant cell tumor of the thoracic spine: MR appearance.

S P Meyers, K Yaw and K Devaney

AJNR Am J Neuroradiol 1994, 15 (5) 962-964

<http://www.ajnr.org/content/15/5/962>

This information is current as
of April 17, 2024.

Giant Cell Tumor of the Thoracic Spine: MR Appearance

Steven P. Meyers, Kenneth Yaw, and Kenneth Devaney

Summary: The MR features of a giant cell tumor that predominantly involved the posterior elements of a thoracic vertebra are presented. This extradural neoplasm compressed and displaced the spinal cord. The tumor had low to intermediate signal on short-repetition-time images and predominantly high signal on long-repetition-time images. It showed mild heterogeneous enhancement with gadopentetate dimeglumine.

Index terms: Spine, vertebrae; Spine, neoplasms; Spine, magnetic resonance

Giant cell tumors represent approximately 5% of primary bone neoplasms (1, 2). These tumors are locally aggressive and rarely metastasize (1, 2). Giant cell tumors are typically located at the ends of long bones; only 4% involve vertebrae above the sacrum (1).

Case Report

A 15-year-old boy presented with a 6-week history of right lower extremity weakness, and a 2-month history of left-sided chest pain without radiation. There was decreased pinprick sensation at the T-5 level, decreased strength in his right leg, and bilateral hyperactive reflexes at the patella and ankle.

A frontal roentgenogram of the thoracic spine showed absence of the left pedicle of the T-5 vertebra (not shown). Magnetic resonance (MR) imaging of the thoracic spine was performed (Fig 1). The preoperative diagnostic considerations included giant cell tumor, osteoblastoma, and aneurysmal bone cyst.

The patient underwent a T-4–T-5 laminectomy and gross total excision of the tumor. The tumor was found to be entirely extradural and did not invade the dura. Resected specimens appeared as hemorrhagic and brown-yellow soft tissue partially replacing bone. The histologic features were consistent with giant cell tumor of bone (Fig 2). Follow-up imaging at 12 months showed no evidence of tumor recurrence.

Discussion

In a large series of 429 giant cell tumors, only 16 (4%) were located in vertebrae above the sacrum (1). The age distribution of patients with giant cell tumors of vertebrae was lower than that for appendicular lesions (1, 2). Dahlin (2) reported that 29% of vertebral giant cell tumors occurred during the first 2 decades of life.

Histologically, giant cell tumors consist primarily of sheets of mononuclear round to spindle-shaped cells and numerous multinucleated giant cells within a moderately vascularized stroma as shown in Figure 2 (1–3). In our case, the vascular stroma contained numerous scattered collections of erythrocytes. Other features of this lesion included occasional erythrocyte lakes (secondary “aneurysmal bone cystlike” change) and xanthomatous change within focal collections of histiocytes. Aneurysmal bone cyst formation may be encountered as a secondary feature in a variety of osseous lesions including giant cell tumor (4).

The MR signal characteristics of the vertebral lesion, low to medium signal intensity on short-repetition-time images and predominately high signal intensity on long-repetition-time images, are similar to those located within the appendicular skeleton (5–7). A marginal zone of low signal also has been reported previously and has been suggested to represent hemosiderin deposition or reactive bone formation (5, 6). Direct histopathologic imaging correlation to confirm either of these possibilities, however, was not performed because en bloc tumor resection was carried out neither previously (6) nor in our case. Short-repetition-time images after administration of gadopentetate dimeglumine showed slightly better differentiation between enhancing tumor and uninvolved marrow than similar images without

Received September 18, 1992; accepted pending revision November 18; revision received January 25, 1993.

From the Department of Radiology, Strong Memorial Hospital, University of Rochester School of Medicine and Dentistry, Rochester, NY (S.P.M.); the Department of Orthopedics, University of Pittsburgh School of Medicine (K.Y.); and the Department of Pathology, University of Missouri-Kansas City, Truman Medical Center, Kansas City, Kan (K.D.).

Address reprint requests to Steven Meyers, MD, PhD, Department of Radiology, University of Rochester, 601 Elmwood Ave, Rochester, NY 14642.

AJNR 15:962–964, May 1994 0195-6108/94/1505-0962 © American Society of Neuroradiology

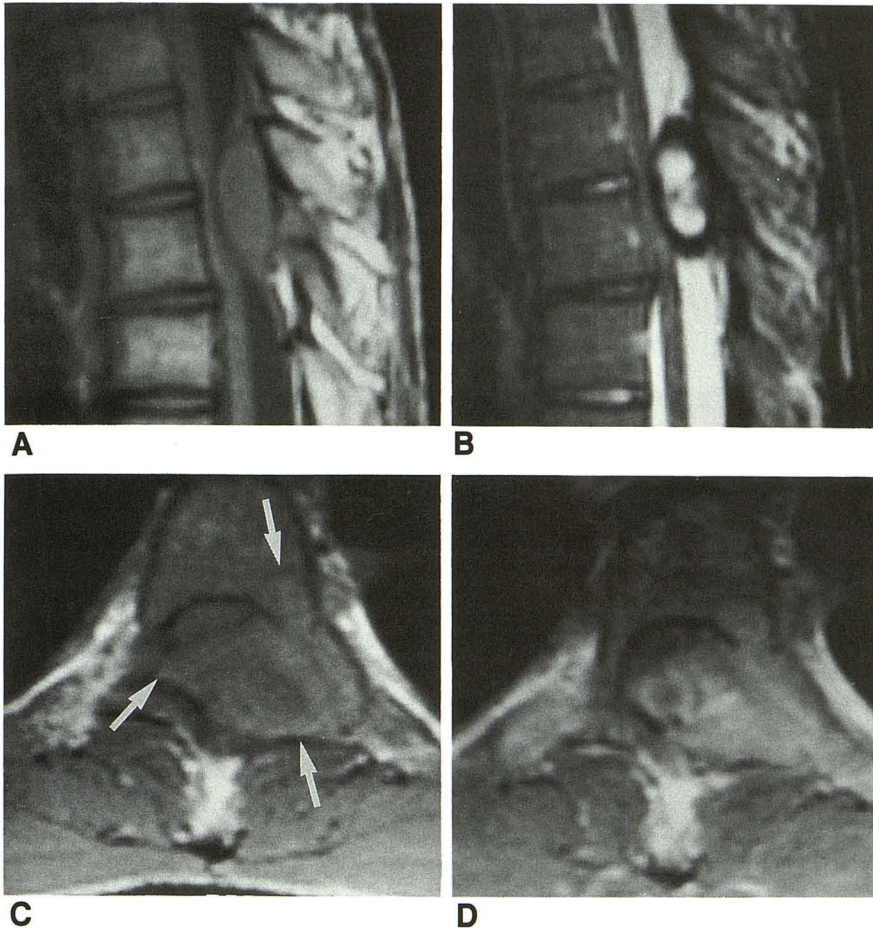


Fig. 1. A, Short repetition time/echo time 550/19 sagittal MR image (1.5 T) shows an extradural tumor with low to medium signal intensity. The tumor extended into the spinal canal, compressing the posterior margin of the spinal cord.

B, Long repetition time/long pseudo-echo time 4000/144 sagittal fast spin-echo image (8 echo train) shows the tumor to have predominantly high signal centrally with a surrounding margin of very low signal.

C, Short repetition time/echo time 600/11 axial image shows tumor involving the posterior portion of the vertebral body, left pedicle, lamina, and transverse and spinous processes (arrows).

D, Postcontrast short repetition time/echo time 600/11 axial image shows a mild degree of heterogeneous enhancement within the tumor.

contrast (Fig 1). Few data exist on the MR enhancement characteristics of giant cell tumor with gadolinium. It has been reported that nonnecrotic portions of giant cell tumor show varying degrees of gadolinium enhancement (6).

The location of giant cell tumor within vertebrae can vary (2). In a series of vertebral giant cell tumors, conventional roentgenographic findings of rarefaction were present in 27 cases (2). Thirteen had roentgenologic involvement of the vertebral body, 9 involved the vertebral arch and body, and 5 involved only a portion of the arch (2). In our case, MR showed the giant cell tumor to involve the vertebral body, pedicle, lamina, transverse and spinous processes.

The differential diagnosis of the more common lesions that involve the posterior vertebral elements in children include giant cell tumor, osteoblastoma, aneurysmal bone cyst, and metastases. These lesions can have overlapping MR signal features (4, 8-10). Definitive diagnosis based solely on MR characteristics, therefore, may not be possible. The important clinical role

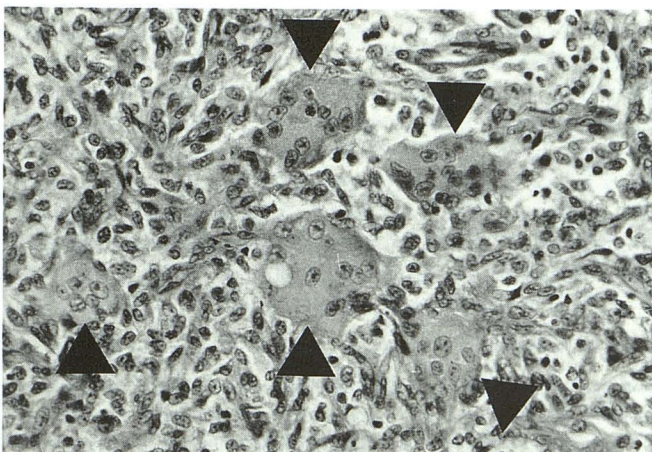


Fig. 2. High-power (400X, hematoxylin-eosin stain) photomicrograph of the tumor shows numerous round to spindle-shaped cells and interspersed multinucleated giant cells (arrowheads).

of MR is to define tumor size and location for surgical planning.

Giant cell tumors are locally invasive lesions and rarely metastasize (1-3). The traditional treatment of giant cell tumor has been curettage and autograft reconstruction (11). A limitation of this technique is that local recurrence of giant cell tumor can be up to 60% (11). This has led others to recommend excision of tumor-containing bone with a wide local margin (11). The location of giant cell tumor within the spine makes gross total tumor resection difficult (2).

References

1. Dahlin DC, Unni KK. Giant cell tumor (osteoclastoma). In: *Bone tumors*. 4th ed. Springfield, IL: Charles C Thomas, 1986:119-140
2. Dahlin DC. Giant cell tumor of vertebrae above the sacrum: a review of 31 cases. *Cancer* 1977;39:1350-1356
3. Moser RP, Kransdorf MJ, Gilkey FW, Manaster BJ. Giant cell tumor of the upper extremity. *Radiographics* 1990;10:83-102
4. Caro PA, Mandell GA, Stanton RP. Aneurysmal bone cyst of the spine in children. MR imaging at 0.5 tesla. *Pediatr Radiol* 1991;21:114-116
5. Tehranzadeh J, Murphy BJ, Mnaymneh W. Giant cell tumor of the proximal tibia: MR and CT appearance. *J Comput Assist Tomogr* 1989;13:282-286
6. Yao L, Mirra JM, Seeger LL, Eckardt JJ. Case report 715. *Skeletal Radiol* 1992;21:124-127
7. Herman SD, Mesgarzadeh M, Bonakdarpour A, Dalinka MK. The role of magnetic resonance imaging in giant cell tumor of bone. *Skeletal Radiol* 1987;16:635-643
8. Kroon HM, Schurmans J. Osteoblastoma: clinical and radiologic findings in 98 new cases. *Radiology* 1990;175:783-790
9. Pettersson H, Gillespy T, Hamlin DJ, et al. Primary musculoskeletal tumors: examination with MR imaging compared with conventional modalities. *Radiology* 1987;164:237-241
10. Tsai JC, Dalinka MK, Fallon MD, Zlatkin MB, Kressel HY. Fluid-fluid level: a nonspecific finding in tumors of bone and soft tissue. *Radiology* 1990;175:779-782
11. Carrasco CH, Murray JA. Giant cell tumors. *Orthop Clin North Am* 1989;20:395-405