

Are your **MRI contrast agents** cost-effective?

Learn more about generic **Gadolinium-Based Contrast Agents**.



FRESENIUS
KABI

caring for life

AJNR

The combined role of embolization and tissue expanders in the management of arteriovenous malformations of the scalp.

T R Marotta, A Berenstein and B Zide

AJNR Am J Neuroradiol 1994, 15 (7) 1240-1246

<http://www.ajnr.org/content/15/7/1240>

This information is current as of April 17, 2024.

The Combined Role of Embolization and Tissue Expanders in the Management of Arteriovenous Malformations of the Scalp

T. R. Marotta, A. Berenstein, and B. Zide

Summary: Successful results of a multidisciplinary (interventional neuroradiology and plastic surgery) approach of aggressive preoperative embolization followed by complete en bloc excision of scalp arteriovenous malformations are presented in five cases. To cover the defect, we used adjacent tissue-expanded scalp.

Index terms: Arteriovenous malformations, embolization; Scalp; Skull, surgery; Interventional neuroradiology, experimental; Surgery, reconstructive

Vascular malformations involving the scalp present with an "expanding" pulsatile mass, associated with headaches, and local ischemic ulcerations that can result in various degrees of bleeding. On occasion, scalp arteriovenous malformations (AVMs) can have significant transbony dural supply and sometimes associated dural fistulas with intracranial venous drainage that may produce neurologic manifestations. If untreated, scalp AVMs usually increase in size, with more flow producing venous distention, which in turn further reduces tissue perfusion (1). Cosmetically, these lesions can be unsightly because of prominent tortuous vessels. Bleeding can be profuse and may become life threatening. Treatment is difficult in view of the rich vascularity of the scalp and the potential for transbony supply to an extracranial lesion from meningeal arteries (1). Therefore, if only partially treated by whatever methods (surgery, embolization, etc), a high probability of recurrence will continue to cause problems for the patient. Curative treatment occurs only by "encompassing the entire system in a surgical resection" (2). In both large and small lesions in which the shunt is occluded with a permanent tissue adhesive (1), we have been able to accomplish complete excision using a combined

approach of aggressive preoperative embolization (both transarterial and direct percutaneous) followed by complete excision (including periosteum and skin) and coverage of the defect by tissue-expanded adjacent scalp.

Methods and Materials

Using this combined approach of scalp tissue expansion, preoperative embolization, complete excision, and defect repair using the expanded tissue, we have treated five patients with scalp AVMs. Three patients were treated in this way only after numerous attempts at embolization and partial excisions failed to control the lesions (group A). Two patients were treated by this combined approach from the outset (group B). One patient from each of these groups is presented in detail.

Group A Patient

This patient presented more than 10 years ago when she was 21 years old and in the third trimester of her first pregnancy. She noticed pulsations posterior to her left ear. On examination there was a soft, pulsatile, compressible mass in the tissues over the left mastoid region (Fig 1A). A loud bruit was easily heard. There was some reddish discoloration of the skin and hyperemia of the left pinna. Because she was pregnant, a limited left common carotid angiogram was performed with appropriate shielding to rule out an intracranial component. This showed a left scalp AVM with transbony supply from the left middle meningeal artery and high flow from the posterior auricular and occipital arteries; drainage was into the transverse and sigmoid sinus through the bone and into superficial scalp veins. She was advised to have a cesarean-section delivery at term to avoid undue stress on the vascular malformation. A healthy baby was born without difficulty. The AVM did not change after the delivery. Repeat angiography with selective injections showed the bulk of supply to the malformation from the occipital artery. Additional supply from the posterior auricular, middle meningeal (trans-

Received June 2, 1993; accepted pending revision August 30; revision received October 1.

From the Department of Interventional Neuroradiology (A.B.) and the Department of Plastic Surgery (B.Z.), New York (NY) University Medical Center; and the Department of Neuroradiology (T.R.M.), Vancouver General Hospital, Vancouver, British Columbia, Canada.

Address reprint requests to T. R. Marotta, MD, Department of Neuroradiology, Vancouver General Hospital, 855 W 12th Ave, Vancouver, BC, Canada V5Z 1M9.

AJNR 15:1240-1246, Aug 1994 0195-6108/94/1507-1240 © American Society of Neuroradiology

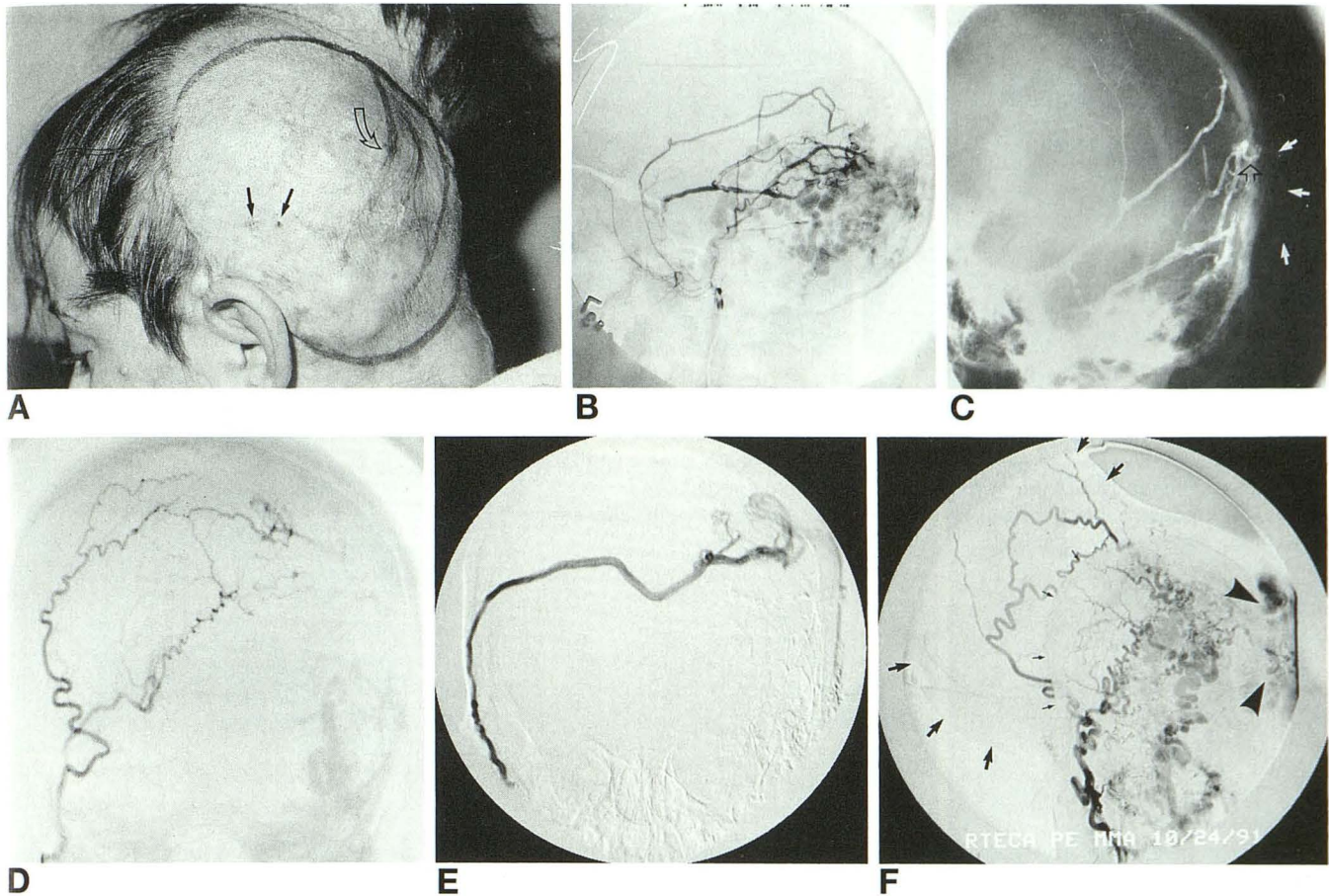


Fig 1. A, Presurgical photograph after embolization shows serpiginous mass behind the left ear. Note marks in skin indicating the site of entrance for the percutaneous portion of embolization (*arrows*). Note also area of small ulceration, which had been bleeding (*curved arrow*).

B, Angiogram. Selective middle meningeal artery injection to show transbony supply to scalp AVM.

C, Plain film. Cast of glue after embolization of the middle meningeal artery. Oblique projection shows the glue passing through the bone toward the scalp (*arrowhead*). Note evidence of glue penetrating the area of the nidus (*white arrows*).

D and E, Angiograms show recruitment of supply from right middle meningeal artery (D) and right occipital artery (E).

F, Angiogram. Frontal view of right external carotid injection shows the left scalp AVM (*arrowheads*) and the tissue-expanded right scalp (*large arrows*; *small arrows* outline outer bony skull).

bony to scalp) (Figs 1B and C), ascending pharyngeal, and dorsal cervical arteries was demonstrated. Aggressive embolization using particles of polyvinyl alcohol foam and isobutyl cyanoacrylate was performed and accomplished approximately 90% to 95% angiographic closure of the lesion. The patient did well for 6 years but returned with renewed pulsations, headaches, and "spreading" of the lesion. Subsequent angiography showed recurrence with recruitment of supply from the left vertebral C-1 and C-2 branches, left superficial temporal, and opposite (right) occipital and middle meningeal arteries (Figs 1D and E). She was now noticing pulsation in the right occipital region, where a thrill and bruit were noted; these findings were cyclical, being worse about 1 week before menstruation. In addition, hair loss and small ulcerations with bleeding were occurring over the left scalp (Fig 1A). Several additional embolizations with both acrylic and polyvi-

nyl alcohol foam were carried out during 4 years without complete control of the malformation.

In an attempt to completely eradicate the AVM, a large tissue expander was then placed in the less-affected right temporal parietal scalp at least 3 cm from the edge of the AVM; after sufficient time for expansion (2.5 months) and before excision, aggressive preoperative embolization of the malformation with liquid acrylic from both the transarterial and percutaneous routes was performed (Fig 1F-H). One week after embolization complete excision of the malformation was then accomplished. The expanded scalp was transposed for coverage of the entire defect. Excision included periosteum, which was lifted off the bone, revealing large transosseous vessels, a few occluded by acrylic but most requiring closure with bone wax. Despite embolization, there was marked bleeding requiring transfusion of 6 U of blood during the 3.5-hour procedure. She now

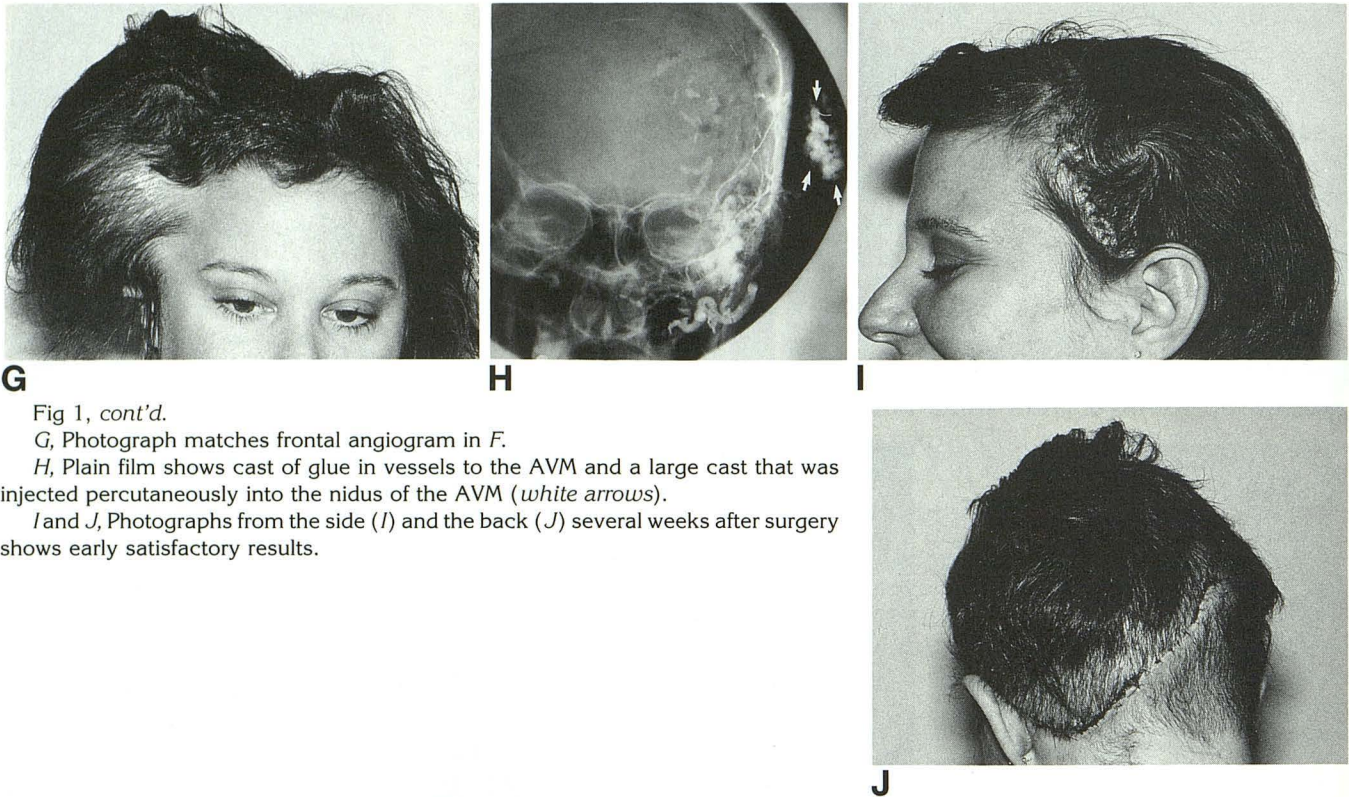


Fig 1, cont'd.

G, Photograph matches frontal angiogram in F.

H, Plain film shows cast of glue in vessels to the AVM and a large cast that was injected percutaneously into the nidus of the AVM (white arrows).

I and J, Photographs from the side (I) and the back (J) several weeks after surgery shows early satisfactory results.

has been followed for 2 years with no recurrence of the vascular malformation. She looks completely normal and has normal hair growth (Figs 1I and J).

Group B Patient

This 19-year-old man had been struck in the head by a surfboard just more than 1 year before treatment. At the time of the incident he sustained a small linear skull fracture in the parietal region; there was associated scalp fullness, which was felt to represent a hematoma. He remained neurologically intact throughout. There was persistence of parietal scalp fullness for months with the development of pulsation in the temporal region and a bruit. Computed tomographic and magnetic resonance examination showed prominence of the right parietal soft tissues with areas of flow void consistent with a diagnosis of high-flow arteriovenous fistula or scalp AVM. Angiographic examination confirmed the presence of a vascular malformation with high flow to the lesion through the right superficial temporal artery and bilateral occipital arteries. Direct fistulous components were present, draining into superficial veins (Fig 2A). The findings were interpreted as an AVM probably triggered by the trauma. However, traumatic arteriovenous fistulization with associated angiogenesis could not be ruled out. Treatment consisted of direct percutaneous puncture of the lesion and embolization with *N*-butyl cyanoacrylate; a significant component of the lesion was closed, leaving a lump of glue in the scalp but eliminating the pulsations and bruit. The patient decided

not to have surgery for removal of the lump at that time. Within 6 months there was recurrence of pulsation and bruit. The patient then underwent tissue expansion of the left parietooccipital scalp over 3 months. Repeat direct percutaneous embolization with *N*-butyl cyanoacrylate was carried out just before en bloc surgical excision of the vascular malformation, during which there was minimal blood loss (Fig 2B-F). Excellent coverage of the defect was obtained with the scalp flap, and the patient has done well (Fig 2G).

Principles and Method of Embolization

The principles and method of transfemoral approach and embolization are thoroughly covered in Volumes 2 and 4 of *Surgical Neuroangiography* (1, 3). For percutaneous access to scalp AVMs the procedure is performed under general anesthesia. The hair overlying the scalp AVM is shaved, and this area is prepared and draped as part of the usual preparation for femoral puncture. Superselective angiographic mapping of the lesion is performed via the transfemoral approach. An appropriate area of the malformation is then chosen (feeding pedicle, nidus, or venous outflow) and punctured directly using an 18- to 20-gauge angiocatheter. A syringe and connecting tubing filled with contrast material are attached to the catheter and secured in position. Backflow of blood and small injections of contrast material are used to confirm the position of the catheter. An angiogram during hand injection is then performed to document the component of the AVM accessed,

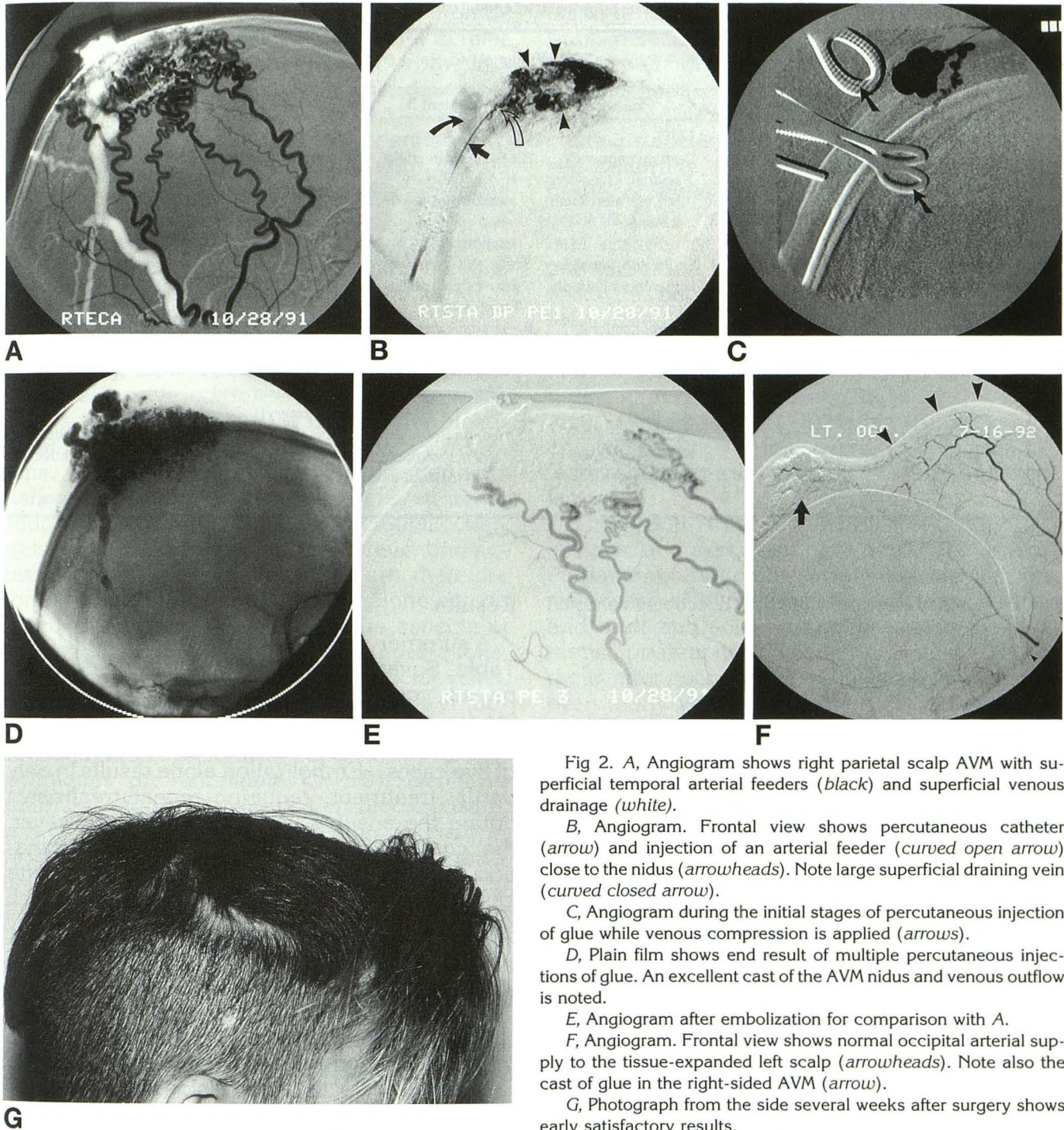


Fig 2. A, Angiogram shows right parietal scalp AVM with superficial temporal arterial feeders (black) and superficial venous drainage (white).

B, Angiogram. Frontal view shows percutaneous catheter (arrow) and injection of an arterial feeder (curved open arrow) close to the nidus (arrowheads). Note large superficial draining vein (curved closed arrow).

C, Angiogram during the initial stages of percutaneous injection of glue while venous compression is applied (arrows).

D, Plain film shows end result of multiple percutaneous injections of glue. An excellent cast of the AVM nidus and venous outflow is noted.

E, Angiogram after embolization for comparison with A.

F, Angiogram. Frontal view shows normal occipital arterial supply to the tissue-expanded left scalp (arrowheads). Note also the cast of glue in the right-sided AVM (arrow).

G, Photograph from the side several weeks after surgery shows early satisfactory results.

to rule out supply to normal scalp, to rule out dangerous anastomoses, and to define venous outflow. Venous outflow then can be blocked using manual compression, allowing for better penetration of the nidus, better filling of fistulous components, and less risk of escape of embolic material to the venous circulation. Embolization is carried out using *N*-butyl cyanoacrylate.

The route of embolization (transarterial versus percutaneous) is chosen based on the angiographic architecture

of the malformation. In all cases a selective transarterial angiogram is performed before embolization to map the lesion. If there are arterial pedicles accessible to superselective catheterization that will allow sparing of the normal surrounding scalp supply and good penetration of the nidus, these are embolized transarterially. When transbony meningeal supply is identified, it is embolized through a transarterial approach. Arterial pedicles that are not readily accessed transarterially, the nidus, and veins are

Five patients with AVMs of the scalp treated with combined approach of embolization and tissue expanders

	Group A (Multiple Previous Embolization Attempts)			Group B (Combined Approach from the Outset)	
	Patient 1	Patient 2	Patient 3	Patient 4	Patient 5
Age at presentation/Sex	17/F	18/F	19/F	20/M	21/M
Presentation	During pregnancy noticed pulsations posterior to left ear	During pregnancy noticed discolored left ear after local trauma	Bleeding from scalp, H/A's, difficulty swallowing, ataxia, sleep apnea, exophthalmos	Persisting scalp mass and bruit after minor local trauma	Bruit and hair loss
Angiographic architecture	Scalp and transbony meningeal supply	Scalp and transbony meningeal supply	Scalp and transbony meningeal multiple dural fistulas	Scalp only	Scalp and transbony meningeal supply
Treatment before combined approach	3 embolizations in 10 years	4 embolizations, 1 skin graft in 3 years	R external carotid artery ligation (subsequent reanastomosis) 6 embolizations	1 embolization (initially refused tissue expansion and surgery)	None
Outcome and follow-up	Excellent at 2 years, no AVM recurrence	Excellent at 6.5 years, no AVM recurrence	Immediate improvement in exophthalmos and ataxia, residual dural fistulas	Excellent at 1 year, no AVM recurrence	Developed scalp abscess in late postoperative period, no AVM recurrence at 1 year

then approached and embolized by a direct percutaneous route.

Principles and Method of Scalp Tissue Expansion and Surgery of Scalp AVMs

Reconstruction after removal of a scalp AVM requires considerable planning. The usual options are limited. Local transposition of tissue rarely provides sufficient coverage. Free-flap reconstruction requires anastomoses to nearby vessels, which may be compromised or enlarged by the malformation. In addition, hairless reconstruction is esthetically inferior. Tissue expansion has become routine for nonvascular scalp lesions (ie, large nevi); the technique has required only moderate adjustment for scalp vascular lesions. Certain specific principles should be noted regarding expanders in scalp AVMs. The method of maximizing gain from rectangular expanders has been presented previously (4). Because a scalp AVM often has perforating transbony vessels, placement of the expander must avoid any of these. The edge of the expander must be at least 2 cm from the AVM. All incisions for the expander placement are perpendicular to the expansion and nowhere near the AVM. Ports are always externalized to allow bloody fluid egress after surgery. This sanguinous drainage tends to continue for a few days because even the noninvolved scalp to be expanded is thicker and hypervascular. Embolization by either transarterial or percutaneous routes must leave the main vessel to the expanded tissue alone. This is necessary for scalp flap survival.

Results

A summary of the five cases is provided in the Table. Several features of scalp AVMs are apparent: young age at presentation, inciting factor (ie, pregnancy or minor trauma), and the presence of transbony meningeal supply (four of five cases). Embolization alone results in only partial treatment, requiring repeat treatments during the ensuing years (group A). However, the combined approach has led to elimination of the AVMs in four of five cases, the fifth case having a large dural component, which remains.

Discussion

The first requirement of any treatment plan is to understand and define what is being treated. Regarding scalp vascular lesions, a classification similar to cerebral vascular lesions may be applied (1, 3). The important distinction is between a single-hole arteriovenous fistula (usually traumatic) and more complex lesions (thought to be congenital). These more complex lesions are characterized by a network of abnormal channels (nidus) between the arterial feeder(s) and the draining vein(s) (ie, an AVM). They also may have components with no intervening nidus (ie, fistulas). The lesions with which we are dealing in this report are of the

complex congenital type. A single-hole arteriovenous fistula indeed may present in a similar way, with the fistula being "hidden" in the enlarged, tortuous venous network that develops. However, treatment of these lesions is usually more straightforward, whereby identification and elimination of the hole leads to cure. On the other hand, treatment of congenital scalp AVMs is much more difficult.

Various types of treatments for congenital scalp AVMs have been used, including surgical excision, vessel ligation, embolization, radiation, electrocoagulation, sclerosis, and compression, with the goal being complete obliteration (5, 6). However, surgery is made difficult by the extensive complex vascularity of these lesions and the scalp itself (7). Excessive bleeding at the time of surgery leads to partial resections. Proximal arterial ligations are certainly ineffective, making the situation even more troublesome by encouraging intracranial collaterals and ischemic changes and preventing access for safe embolization, and are therefore contraindicated (8). Embolization alone can be effective in controlling some of the aspects of scalp AVMs such as size, bleeding, pulsations, noise, and unsightly tortuous superficial veins. However, obliteration of these lesions by embolization alone is difficult (9). Radiation, electrocoagulation, sclerosis, and compression techniques are unreliable (5, 10). Definitive treatment requires controlled en bloc excision, in which the entire malformation is encompassed by the resection (8, 9). Controlled excision implies manageable intraoperative bleeding; this can be attained by aggressive preoperative embolization. En bloc excision includes not only wide margins but also full depth to include both periosteum and skin. A large defect remains and will require coverage.

Embolization has been most effective if liquid agents can be used, because they will prevent recanalization and permit good nidus penetration. We combine transarterial embolization of meningeal transbony supply with percutaneous nidus injections. It is important to plan the location of the tissue expanders and the embolization. Occlusion of the vessels supplying the expanded scalp should be avoided, even if partially supplying the AVM, because this will be the supply to the donor scalp. The timing of embolization should be shortly before the en bloc excision and therefore after the expander has matured.

Many techniques have been used to cover scalp defects; some of these include skin and galeal-pericranial flaps, compound musculocutaneous flaps, and free-tissue transfer (11, 12). However, disadvantages of these methods include insufficient locally available tissue, donor site deformity, and unmatched coverage with tissue of different color, thickness, and hair growth (13). Free-tissue transfer requires normal vessels for anastomosis. These difficulties are addressed by the use of tissue expansion, which has become a widely used plastic surgery technique. Neuman (14) described "the expansion of an area of skin by progressive distention of a subcutaneous balloon" in 1957. Since then, tissue expansion has been used in the scalp (15), head and neck (13), face (16), abdomen, and extremity (17) for coverage of various defects related to tumors, trauma, and congenital lesions.

The group A cases illustrate the locally aggressive and persistent nature of these lesions. Partial embolization treatment provides temporary relief of symptoms related to pulsations and bruit and some improvement in the cosmetic appearance. However, symptoms usually recur after recruitment of new feeding vessels even many years later. The most critical point regarding partial embolization is the need for distal penetration of the nidus and closure of shunts and fistulas, which is best accomplished using liquid acrylics by transarterial and percutaneous injection. Proximal occlusive treatment (ie, coils) should be avoided, because it will likely be ineffective and probably deleterious. Hurwitz and Kerber (8) point out that proximal occlusion encourages collateral blood flow by further reducing the already low venous resistance of the arteriovenous shunt and also by rendering the surrounding tissues relatively ischemic. Proximal occlusion of vessels by coils or other means also will preclude repeated distal embolizations, which, as in the group A cases, can be used during the course of many years to provide palliation of these lesions.

An important concept when considering partial treatment for scalp AVM either surgically or by distal embolization is the possibility of actually stimulating further growth and aggressiveness. The inciting factors for this are unknown, but it is well recognized that mechanical trauma, endocrine stimulation, and inflammation can turn a quiescent lesion into one that is more active (1, 10). Note the five cases re-

viewed here, two presented during pregnancy and one presented after minor local trauma. J. J. Merland (18) recommends treating scalp AVMs with some caution, "such that we do not create a dramatic situation out of one that did not previously exist. If the AVM is quiescent, it must be left untouched, and it is better to teach the patients to take care of the territory of their AVM particularly to prevent aggressive situations (trauma)."

Once treatment is decided on for a symptomatic scalp AVM (pulsation, bruit, bleeding, and aesthetics), the approach should be in a multidisciplinary mode, with complete removal from the outset (ie, group B cases). Very extensive vascular malformations can be cured with an excellent cosmetic result by a combination of embolization and plastic surgery. Heilman et al (7) were able to eliminate a scalp "cirroid" aneurysm by a combination of transarterial (particles and coils) embolization, and percutaneous (coils) embolization followed by surgical removal of the occluded lesion through a small elliptical coronal incision, which was closed primarily (note that this lesion was an arteriovenous fistula, not an AVM as in our cases). Hurwitz and Kerber reported two cases of scalp AVM treated by a combination of embolization (polyvinyl alcohol foam particles) and wide excision requiring coverage by a latissimus dorsus myocutaneous free flap in one case and by a permanently pedicled flap based on the contralateral neck in the other case (8).

Conclusion

Our approach requires careful planning, which includes magnetic resonance imaging, full angiographic mapping, and placement of a tissue expander that will permit coverage of the excised tissue defect. These initial steps are followed by aggressive transarterial embolization of the transbony supply and accessible scalp arterial pedicles with acrylic material, and direct percutaneous embolization of the superficial component that best reaches the nidus, sparing the scalp blood vessels. Embolization is performed shortly before en bloc resection and coverage.

The complication of retained embolic material and scalp abscess has occurred in one case. There has been no evidence of recurrence with follow-up ranging from 1 to 6 years. The aesthetic results have been most satisfactory in each case.

References

1. Lasjaunias P, Berenstein A. *Surgical Neuroangiography*. Vol 2. New York: Springer-Verlag, 1992:1-56
2. Conley JJ. Blood vessel complications. In: Conley JJ, ed. *Complications of Head and Neck Surgery*. Philadelphia: Saunders, 1979:66-80
3. Berenstein A, Lasjaunias P. *Surgical Neuroangiography*. Vol 4. New York: Springer-Verlag, 1992:1-86,189-266
4. Zide BM, Karp NS. Maximizing gain from rectangular tissue expanders. *Plast Reconstr Surg* 1992;90:500-504
5. Ogawa Y, Inoue K. Electrothrombosis as a treatment of cirroid angioma in the face and scalp and varicosis of the leg. *Plast Reconstr Surg* 1982;70:310-318
6. Persky MS, Berenstein A, Cohen NL. Combined treatment of head and neck vascular masses with preoperative embolization. *Laryngoscope* 1984;94:20-27
7. Heilman CB, Kwan ES, Klucznik RP, Cohen AR. Elimination of a cirroid aneurysm of the scalp by direct percutaneous embolization with thrombogenic coils. *J Neurosurg* 1990;73:296-300
8. Hurwitz DJ, Kerber CW. Hemodynamic considerations in the treatment of arteriovenous malformations of the face and scalp. *Plast Reconstr Surg* 1981;67:421-432
9. Schultz RC, Hermosillo CX. Congenital arteriovenous malformation of the face and scalp. *Plast Reconstr Surg* 1980;65:496-501
10. Khodadad G. Arteriovenous malformations of the scalp. *Ann Surg* 1973;177:79-85
11. Horowitz JH, Persing JA, Nichter LS, Morgan RF, Edgerton MT. Galeal-pericranial flaps in head and neck reconstruction: anatomy and application. *Am J Surg* 1984;148:489-497
12. Fonseca JLS. Use of pericranial flap in scalp wounds with exposed bone. *Plast Reconstr Surg* 1983;72:786-790
13. Baker SR, Swanson NA. Clinical applications of tissue expansion in head and neck surgery. *Laryngoscope* 1990;100:313-319
14. Neuman CG. The expansion of an area of skin by progressive distension of a subcutaneous balloon. *Plast Reconstr Surg* 1957;19:124-130
15. Nordstrom REA, Devine JW. Scalp stretching with a tissue expander for closure of scalp defects. *Plast Reconstr Surg* 1985;75:578-581
16. Romo T, Goldberg J. Versatile use of skin expanders in facial plastic surgery. *Arch Otolaryngol Head Neck Surg* 1992;118:333-337
17. Paletta C, Campbell E, Shehadi SI. Tissue expanders in children. *J Pediatr Surg* 1991;26:22-25
18. Merland JJ. Discussion: hemodynamic considerations in the treatment of arteriovenous malformations of the face and scalp. *Plast Reconstr Surg* 1981;67:433-434