

Are your MRI contrast agents cost-effective?

Learn more about generic Gadolinium-Based Contrast Agents.



**FRESENIUS
KABI**

caring for life

AJNR

**Childhood cerebral form of
adrenoleukodystrophy: short-term effect of bone
marrow transplantation on brain MR
observations.**

D J Loes, A E Stillman, S Hite, E Shapiro, L Lockman, R E
Latchaw, H Moser and W Krivit

This information is current as
of April 10, 2024.

AJNR Am J Neuroradiol 1994, 15 (9) 1767-1771
<http://www.ajnr.org/content/15/9/1767>

Childhood Cerebral Form of Adrenoleukodystrophy: Short-term Effect of Bone Marrow Transplantation on Brain MR Observations

Daniel J. Loes, Arthur E. Stillman, Stephen Hite, Elsa Shapiro, Lawrence Lockman, Richard E. Latchaw, Hugo Moser, and William Krivit

PURPOSE: To report the serial brain MR observations in patients with childhood-onset cerebral adrenoleukodystrophy 1 to 2 years after bone marrow transplantation. **METHODS:** Eight boys with childhood-onset cerebral adrenoleukodystrophy have undergone successful transplantation at our institution. Seven patients (mean age, 8 years 10 months; range, 5 years 3 months to 11 years 9 months) had serial MR studies before and after transplantation. An MR severity score (0 to 34) based on disease location and the presence or absence of focal atrophy was calculated for each patient scan. **RESULTS:** Posttransplantation serial MR showed improvement in two patients, stabilization in three patients, and worsening of MR signal changes in two patients. The patient with the most striking progression had systemic graft-versus-host disease. Although the adrenoleukodystrophy MR severity score did not change in three patients after transplantation, two of these patients did show improved margination of disease. **CONCLUSION:** Bone marrow transplantation can affect brain MR observations in childhood-onset cerebral adrenoleukodystrophy. Although brain MR findings do not typically resolve, they do seem to stabilize, which is an improvement over the natural MR history of the disease.

Index terms: Adrenoleukodystrophy; Brain, diseases; Brain, magnetic resonance; Pediatric neuroradiology; Transplants

AJNR Am J Neuroradiol 15:1767-1771, Oct 1994

The childhood-onset cerebral form of X-linked adrenoleukodystrophy is a devastating peroxisomal disorder that primarily affects the adrenal glands and the central nervous system (1). The prognosis in these patients with clinically apparent disease has been poor, with rapid neurologic deterioration leading to a vegetative state and subsequent death, usually occurring within a few years after the onset of clinical disease (1). Dietary treatment does not seem

to alter the disease progression in symptomatic patients (2). Bone marrow transplantation is currently being evaluated as a form of therapy in symptomatic individuals (3, 4). The purpose of this study is to report the brain magnetic resonance (MR) observations in patients with childhood-onset cerebral adrenoleukodystrophy 1 to 2 years after bone marrow transplantation.

Materials and Methods

Eight young boys with childhood-onset cerebral adrenoleukodystrophy have undergone successful bone marrow transplantation at our institution. One failed to return for follow-up and subsequently died; no further clinical details are known. Diagnosis in each patient was based on positive biochemical testing, abnormal neuropsychologic testing, and positive brain MR. Seven patients had serial MR scanning before and after bone marrow transplantations. The age range of these seven patients at the time of transplantation was 5 years 3 months to 11 years 9 months, with a mean of 8 years 10 months.

The MR examinations before transplantation were performed on multiple scanners at multiple institutions. The

Received September 28, 1993; accepted after revision February 2, 1994.

Supported by grant ROI-29099-03 from the National Institute of Neurological Disorders and Stroke, grant RR00052 from the National Institutes of Health, and grant R-000685 from the Food and Drug Administration.

From the University of Minnesota Hospital and Clinic, Minneapolis (D.J.L., A.E.S., S.H., E.S., L.L., R.E.L., W.K.); and the Kennedy Krieger Institute, Baltimore, Md (H.M.).

Address reprint requests to Daniel J. Loes, MD, University of Minnesota Hospital and Clinic, Department of Radiology, Box 292, 420 Delaware St SE, Minneapolis, MN 55455.

AJNR 15:1767-1771, Oct 1994 0195-6108/94/1509-1767

© American Society of Neuroradiology

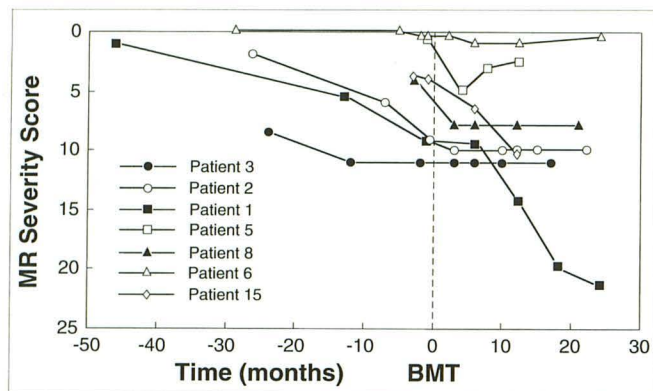


Fig 1. Childhood cerebral form of adrenoleukodystrophy: effect of bone marrow transplantation (BMT) on MR severity score. Patient identification numbers are not consecutive, because they are original study numbers of patients with adrenoleukodystrophy being evaluated for possible bone marrow transplantation at our institution.

posttransplantation MR scans were all performed with a high-field 1.5-T magnet. All studies included routine sagittal T1-weighted and axial proton density- and T2-weighted sequences. An MR severity score (0.5 to 34) based on disease location and the presence or absence of focal and/or global atrophy was calculated for each patient scan (5). This is a demerit scoring system; hence, 0 is healthy, and the larger numbers indicate more advanced disease.

Statistical analysis using a two-sample *t* test was performed to compare the rates of MR severity (score change per month) for no-transplantation and successful transplantation populations. The baseline posttransplantation MR scan was used as the index exam for the transplantation population. Data acquired in 21 nontransplanted patients with adrenoleukodystrophy younger than the age of

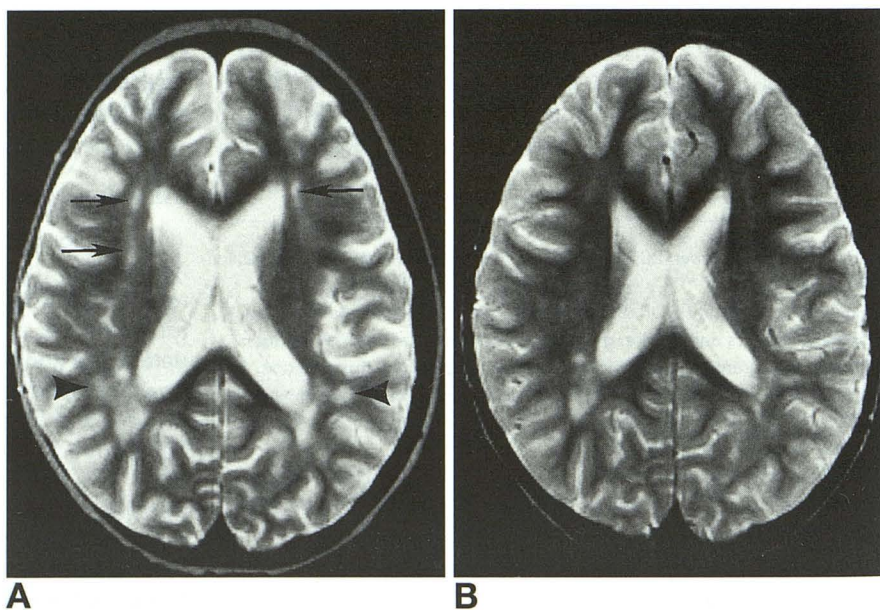
13 years with positive MR observations were combined with the pretransplantation data in this series to obtain the nontransplantation MR rate of severity (5).

Results

Seventeen pretransplantation and 22 post-transplantation brain MR exams were available for review in these seven patients. The mean time of imaging before transplantation was 17 months (range, 1 to 38 months), and the mean MR follow-up was 19 months (range, 12 to 24 months) after transplantation. The effect of bone marrow transplantation on MR severity scores in patients with childhood-onset cerebral adrenoleukodystrophy is shown in Figure 1. Of the four patients followed at least 2 years before transplantation, three patients showed progressive disease, and one patient showed stabilization. Serial posttransplantation MR showed stabilization in three patients, improvement in two patients (Fig 2), and progression in two patients (Fig 3). None of the patients' brain MR returned to normal, although one patient is close (Fig 4).

The mean rate of MR severity (score change per month) of the no-transplantation group was 0.24 with an SD of 0.27. The mean rate of MR severity of the successful transplantation group was 0.059 with an SD of 0.32. Patient 1 was excluded from the statistical analysis because of severe graft-versus-host disease. Using a one-sided *t* test, we found the rate of change for the successful transplantation population to be

Fig 2. Serial axial T2-weighted MR images (2500/90/1 [repetition time/echo time/excitations]) obtained 3 (A) and 12 (B) months after bone marrow transplantation (patient 4) shows near-complete resolution of bifrontal central signal hyperintensities (A, arrows), partial resolution of right parietal central signal hyperintensities (A, arrowheads), and the return of subarachnoid and ventricular sizes (not shown) to normal. The MR signal changes could be caused by adrenoleukodystrophy, transplantation effects or complications, or both.



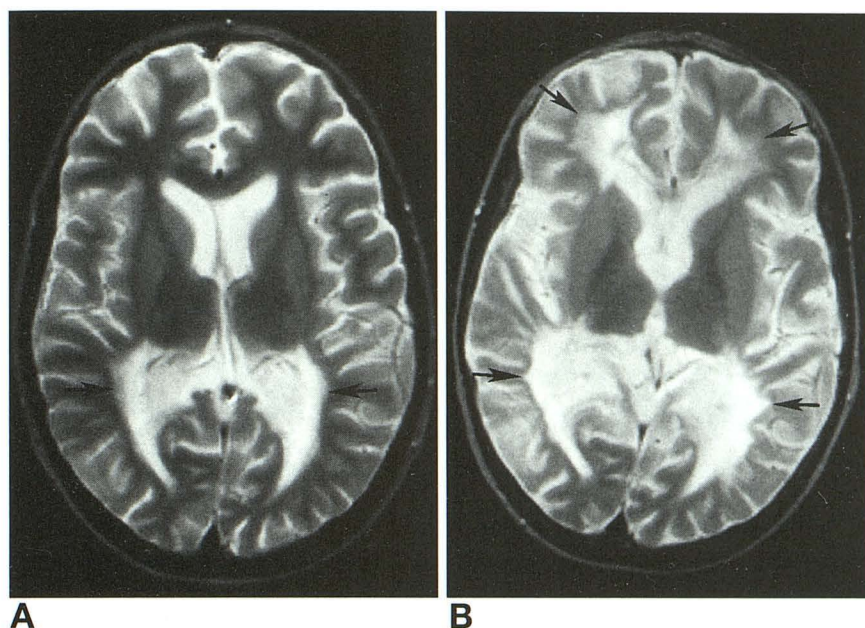


Fig 3. Serial axial T2-weighted MR images (2500/90) obtained 1 month before (A) and 18 months after (B) transplantation (patient 3) show significant central-to-peripheral and posterior-to-frontal progression (arrows).

significantly less than the control population ($P < .08$).

Discussion

The gene responsible for X-linked adrenoleukodystrophy recently has been located (6). The underlying biochemical abnormality involves accumulation of saturated very-long-chain fatty acids caused by defective function of a single peroxisomal enzyme (1). Increased very-long-chain fatty acid concentration in plasma or fibroblasts is the definitive test for this disease (1). The pathogenesis of tissue damage in adrenoleukodystrophy is related to the accumulation of saturated very-long-chain fatty acids, although the exact mechanism is unknown (7). Because not all patients with biochemical defects develop central nervous system disease, a second causal factor, in addition to the increased saturated very-long-chain fatty acids, must be required (7). It has been postulated that an immunopathogenic mechanism may be involved in the cerebral disease, because of the perivascular lymphocytic infiltration found in the central nervous system and not in adrenal cortices of affected patients (7).

Current therapy in asymptomatic children is aimed at normalizing plasma levels of very-long-chain fatty acids through dietary restriction of very-long-chain fatty acid intake and the administration of monounsaturated oils (8). Bone marrow transplantation has been shown

useful as a form of therapy in various other genetic metabolic diseases including metachromatic leukodystrophy and is currently being performed in patients with childhood-onset cerebral adrenoleukodystrophy (9). A case report by Aubourg and colleagues showed complete and permanent reversal of early neurologic and MR manifestations in a patient with the childhood form of adrenoleukodystrophy 18 months after transplantation (10). Four-year follow-up after transplantation in this patient shows the intelligence quotient to have risen 4 SD.

An ongoing study at our institution is currently being done to evaluate bone marrow transplantation as a form of therapy in patients with symptomatic cerebral adrenoleukodystrophy. All patients are closely monitored by extensive neuropsychologic testing, neurologic testing, MR, and MR spectroscopy. Our preliminary experience indicates that the neuropsychologic testing detects early onset of the cerebral form of the disease before overt neurologic findings. At present, there is agreement that an MR severity score of 1 or greater and neuropsychologic observations compatible with disease will dictate the use of bone marrow transplantation (letters from W. Krivit and H. Moser, 1993). Patient 6 had transplantation before this agreement. MR spectroscopy data are currently being evaluated.

This series shows that bone marrow transplantation does affect brain MR observations in patients with childhood-onset cerebral adreno-

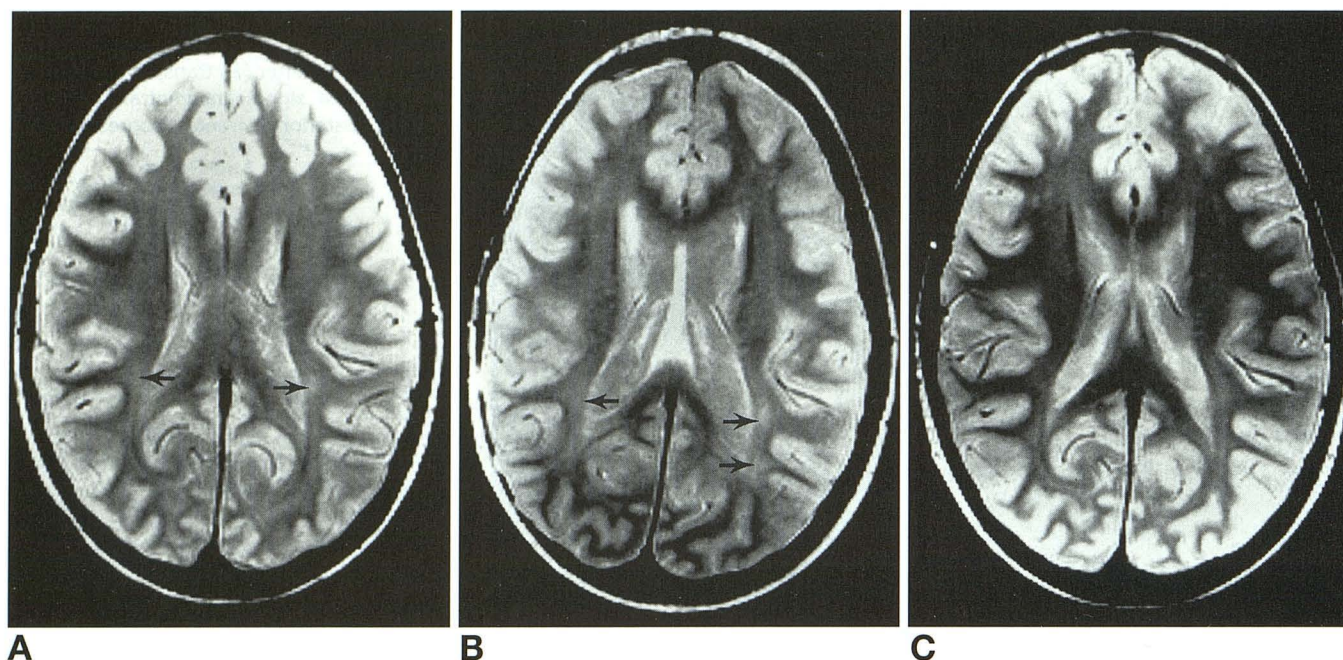
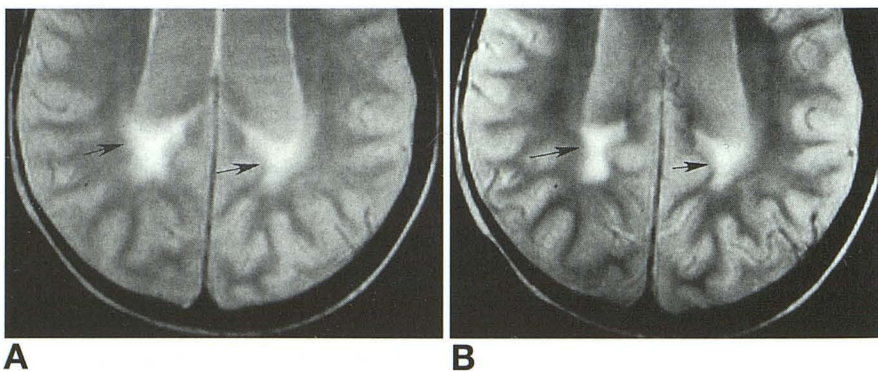


Fig 4. Serial axial proton-density MR images (2500/45) 2 months before and 6 and 24 months after transplantation (A–C) show equivocal periventricular parietooccipital white matter hyperintensities (arrows), subtle progression to definite disease on MR (arrows), and subsequent improvement to near normal (C). A few scattered punctate subcortical white matter lesions, which are probably not caused by adrenoleukodystrophy, are present in the frontal regions of the 6- and 24-month posttransplantation exams (B and C). This case illustrates the difficulty of diagnosing early adrenoleukodystrophy MR involvement. In the absence of a biochemical defect for adrenoleukodystrophy, A and C would be interpreted as normal with incomplete myelination.

leukodystrophy. The majority of patients with childhood-onset cerebral adrenoleukodystrophy did not show disease progression on MR after transplantation. This finding is contrary to the natural MR history of adrenoleukodystrophy (5). The abnormalities seen on MR may improve, although they do not typically completely resolve. The case reported by Aubourg and coworkers seems to be the exception (8). In our study one patient had early equivocal involvement on MR (severity score of 0.5) that advanced to a definitive disease, and then improved to near normal after transplantation (Fig 4). Although the MR severity score did not change in three patients, two of these patients

with stable disease did show questionable or minimal improvement, not definite enough to change the MR severity score. The MR changes were probably caused by improved margination, defined as improved sharpness of the edges of the area of high signal intensity (Fig 5). The cause of this improved margination of MR signal changes is unknown. Our hypothesis is that it is probably caused by a reduced inflammatory component, although less likely minimal focal white matter atrophy or minimal remyelination could account for these findings. Similar improved margination and/or minimal reduction in white matter MR signal changes has been reported in patients with meta-

Fig 5. Serial axial proton-density (2500/45) MR images 3 months (A) and 6 months (B) after transplantation (patient 5) show improved margination of parietal periventricular signal hyperintensities (arrows) with time, without significant changes in extent of disease and MR severity score.



chromatic leukodystrophy after bone marrow transplantation (11).

When interpreting MR studies in patients after transplantation, it is important to be cognizant of findings that may be caused by the transplantation itself or complications resulting from the transplantation. Brain MR observations, including T2 signal hyperintensity and paranchymal volume loss, in this population may be caused by drug reactions, graft-versus-host disease, autoimmune disease, infection, or a reaction to the preparative regimen or the engraftment (12). One patient (Fig 4) in our study developed a few scattered small subcortical white matter lesions; these lesions were present on 6- and 12-month posttransplantation MR studies and had partially improved by the 24-month posttransplantation exam. These findings were not scored as being caused by adrenoleukodystrophy, because they were more compatible with an arteritis or perivascular demyelination that could occur with graft-versus-host disease, drug reaction, or autoimmune disease. MR changes caused by the transplantation procedure or transplantation complications may be indistinguishable from adrenoleukodystrophy-induced MR lesions. The worsening and then improving periventricular and central white matter lesions in patient 5 (Fig 2) were compatible with and hence scored as adrenoleukodystrophy involvement, although there is a possibility that these changes could be related to the transplant procedure.

We are currently in the process of correlating clinical, neuropsychologic, and laboratory data with the adrenoleukodystrophy MR severity scoring method in patients with childhood-onset cerebral adrenoleukodystrophy. Preliminary data suggest that MR may not be the ideal tool to monitor disease course after bone marrow transplantation. All three of our patients with stable posttransplantation MR changes had some improvement based on neuropsychologic and/or clinical testing. A possible weakness of this scoring system may be in detecting improvement, because it seems that the majority of adrenoleukodystrophy-induced MR changes are irreversible. Another weakness of the scoring system already mentioned is that MR signal changes and volume loss from the transplant procedure or complications may be indistinguishable from changes resulting from adrenoleukodystrophy involvement. Although MR may

not be the best monitor of disease course in the posttransplantation population, it remains an important diagnostic tool in confirming cerebral disease in patients with childhood-onset cerebral adrenoleukodystrophy and adrenomyeloneuropathy. Further investigations with MR spectroscopy may prove it more sensitive than spin-echo MR in early detection and monitoring of disease course in adrenoleukodystrophy.

Our series shows that bone marrow transplantation can affect brain MR observations in patients with childhood-onset cerebral adrenoleukodystrophy. Although brain MR findings do not typically resolve, they may improve and tend to at least stabilize over time. This is an improvement on the natural MR history of the childhood cerebral form of adrenoleukodystrophy.

References

1. Moser HW, Naidu S, Kumar AJ, Rosenbaum AE. The adrenoleukodystrophies. *Crit Rev Neurol* 1987;3:29-88
2. Rizzo WB, Leshner RT, Odone A, et al. Dietary erucic acid therapy for X-linked adrenoleukodystrophy. *Neurology* 1989;30:1415-1422
3. Krivit W, Shapiro E, Lockman L., et al. Recommendations for bone marrow transplant in patients with childhood adrenoleukodystrophy. In: Hobbs JR, ed. *COGENT II*. London: Westminster, 1991
4. Krivit W, Shapiro E. Bone marrow transplantation for storage diseases. In: Blume K, Thomas ED, eds. *Bone Marrow Transplantation*. New York: Blackwell Scientific Press, 1994
5. Loes DJ, Hite S, Moser H, et al. Adrenoleukodystrophy: a scoring method for brain MR observations. *AJNR Am J Neuroradiol* 1994;15:1761-1766
6. Moser J, Douar AM, Sarde CO, et al. Putative X-linked adrenoleukodystrophy gene shares unexpected homology with ABC transporters. *Nature* 1993;361:726-730
7. Moser HW, Bergen A, Naidu S, et al. Adrenoleukodystrophy: new aspects of adrenocortical disease. In: Nelson DH, ed. *Endocrinology Metabolism of North America: New Aspects of Adrenocortical Disease*. Philadelphia: WB Saunders, 1991:297-318
8. Moser AB, Borel J, Odone J, et al. A new dietary therapy for adrenoleukodystrophy. *Ann Neurol* 1987;21:240-249
9. Krivit W, Shapiro E. Bone marrow transplantation for storage diseases. In: Desnick RJ, ed. *Treatment of Genetic Diseases*. New York: Churchill Livingstone, 1991:203-221
10. Aubourg P, Blanche S, Jambaque I, et al. Reversal of early neurologic and neuroradiologic manifestations of X-linked adrenoleukodystrophy by bone marrow transplantation. *N Engl J Med* 1990;322:1860-1866
11. Stillman AE, Krivit W, Shapiro E, Lockman L, Latchaw RE. Serial MR in two patients with metachromatic leukodystrophy subsequent to bone marrow transplantation. *AJNR Am J Neuroradiol* (in press)
12. Lockman L, Sung Joo Ho, Krivit W. Acute parkinsonian syndrome with demyelinating leukoencephalopathy in bone marrow transplant recipients. *Pediatr Neurol* 1991;6:457-463