

Are your **MRI contrast agents** cost-effective?

Learn more about generic **Gadolinium-Based Contrast Agents**.



FRESENIUS
KABI

caring for life

AJNR

Spinal dural arteriovenous fistulas: MR and myelographic findings.

J R Gilbertson, G M Miller, M S Goldman and W R Marsh

AJNR Am J Neuroradiol 1995, 16 (10) 2049-2057

<http://www.ajnr.org/content/16/10/2049>

This information is current as
of April 18, 2024.

Spinal Dural Arteriovenous Fistulas: MR and Myelographic Findings

Julie R. Gilbertson, Gary M. Miller, Marc S. Goldman, and W. Richard Marsh

PURPOSE: To examine the clinical and radiographic findings in a large group of patients having or suspected of having a spinal dural arteriovenous fistula. **METHODS:** An analysis of 240 spinal angiograms in 132 patients revealed 97 vascular malformations that included 66 spinal dural arteriovenous fistulas. Sixteen patients had 1 or more normal spinal angiograms that were performed for suspected spinal dural arteriovenous fistulas on other imaging studies. The imaging and clinical data were reviewed in all patients who had or were suspected of having a spinal dural arteriovenous fistula and who had a spinal MR (n = 44) and a myelogram (n = 37). **RESULTS:** Spinal dural arteriovenous fistulas were more common in males (3.4:1) with an average age of 62 years (range, 37 to 81 years). The average time from onset of symptoms to diagnosis was 27 months. Clinical findings included weakness (55%), a progressive clinical course (100%), and a myelopathy on exam (84%). The nidus of the fistula was located between T-6 and T-12 in 61%, in the sacrum in 9%, and intracranially in 8%. In the spinal dural arteriovenous fistula group, vessels were seen on supine myelography in all patients. MR findings in this group included increased T2 signal in the cord (100%), gadolinium enhancement (88%), mass effect (45%), and flow voids (T1, 35%; T2, 45%). The patients in the negative spinal angiogram group were younger (average age, 51 years), had symptoms longer (average time from symptom onset to spinal angiogram, 59 months), and presented with numbness or pain (76%). When compared with the patients with spinal dural arteriovenous fistula, acute or stable deficits were more common (31%), and myelopathy on exam was less common (56%). Although the angiogram-negative patients commonly had vessels on the myelogram (92%), abnormal T2 signal in the cord was unusual (17%). **CONCLUSIONS:** In the appropriate clinical setting, high T2 signal of the spinal cord is the most sensitive imaging finding in spinal dural arteriovenous fistula. The presence of mass effect and enhancement should not discourage this diagnosis. The likelihood of finding a spinal dural arteriovenous fistula in a patient without T2 signal on MR is low.

Index terms: Fistula, arteriovenous; Fistula, spinal dural; Spinal cord, magnetic resonance

AJNR Am J Neuroradiol 16:2049–2057, November 1995

Spinal dural arteriovenous fistulas (AVFs) represent a rare but important treatable cause of myelopathy. They are cryptic acquired lesions that typically occur in older men who present with a chronic progressive myelopathy. The fistula is usually located within the dural sleeve of an exiting thoracic or lumbar nerve

root that drains retrograde into the spinal coronal venous plexus. Symptoms are attributed to chronic venous ischemia from venous hypertension. The cause is unknown, but may be from occlusion of a normal radicular vein that alters the venous drainage of the spinal cord. Prone-supine myelography has historically been the standard screening exam before spinal angiography. Serpentine-filling defects (representing the dilated coronal venous plexus) have been described on the supine myelogram (1, 2). Several authors have described magnetic resonance (MR) findings in patients with spinal dural AVFs (3–12). The purpose of this study is to examine the clinical and MR findings in a large series of patients with angiographically and surgically proved dural fistulas, compare them with

Received February 16, 1995; accepted after revision June 28.

Presented at the 32nd Annual Meeting of the American Society of Neuroradiology, Nashville, Tenn, May 1–7, 1994.

From the Departments of Diagnostic Radiology (J.R.G., G.M.M.) and Neurosurgery (M.S.G., W.R.M.), Mayo Clinic and Mayo Foundation, Rochester, Minn.

Address reprint requests to Gary M. Miller, MD, Mayo Clinic, 200 First St SW, Rochester, MN 55905.

AJNR 16:2049–2057, Nov 1995 0195-6108/95/1610–2049

© American Society of Neuroradiology

prone-supine myelography, and assess the ability of MR to screen patients adequately before spinal angiography.

Materials and Methods

We reviewed 240 spinal angiograms performed between January 1, 1985 and December 31, 1993 in 132 patients. This review revealed 97 vascular malformations, including 66 dural AVFs and 31 other spinal vascular malformations. Sixteen patients with suspected spinal dural AVFs on a myelogram or an MR study had spinal angiograms that were interpreted as normal. Nineteen spinal angiograms were performed for other diagnoses. The spinal angiograms in the 66 patients having a dural fistula proved at surgery and the 16 patients with normal angiogram were reviewed and analyzed. Thirty-one of the 66 patients with a spinal dural AVF and 13 of the 16 patients with a normal spinal angiogram had spine MR studies available for review. These two groups of patients form the basis for our study. Their imaging and clinical findings were reviewed and compared.

Prone-supine myelography using 20 mL of water-soluble contrast was performed and reviewed in 25 patients in the positive group and in 12 patients in the negative group. Seven patients in each group underwent plain-film tomography during their myelographic evaluation. Parameters used in the evaluation of the myelogram included the presence of dilated vessels, the number of vertebral body levels over which they extended, plain-film tomography sensitivity for vessel detection, and beading of the cauda equina. Beading was noted when the dilated vessels extended along the nerve roots of the cauda equina.

All spine MR examinations were performed on a General Electric Signa 1.5-T unit (Milwaukee, Wis). The exams included sagittal T1-weighted (400–500/16–20/2 [repetition time/echo time/excitations]) and T2-weighted sequences consisting of spin-echo (1500/40–80/1), gradient-echo (400/20/4, 12° flip angle), and/or fast spin-echo (3000–3700/90–105/2) protocols. Gadolinium-enhanced sagittal T1-weighted sequences were performed in 25 of the 31 patients in the positive group and in 10 of the 13 patients in the negative group. The MR was evaluated for the presence of increased T2 signal in the cord, the extension of the signal abnormality as measured by the number of vertebral body levels, signal extension to the conus, flow voids or scalloping of the posterior aspect of the cord on T1- and T2-weighted sequences, mass effect, and coronal venous plexus or parenchymal enhancement.

Cut-film small focal spot spinal angiography was performed in all patients. Our current technique includes a bilateral iliac retrograde aortogram using 75 mL of iopamidol (Isovue 300, Bracco Diagnostics, Princeton, NJ), injected at a rate of 40 mL/s, using a Y connector with a 14-film series over the lower spine and pelvis. Selective hand injections of 3 to 5 mL of iopamidol into the spinal intercostal arteries from the supreme intercostal artery to L-3 bilaterally are performed with a 3- to 5-film series. A

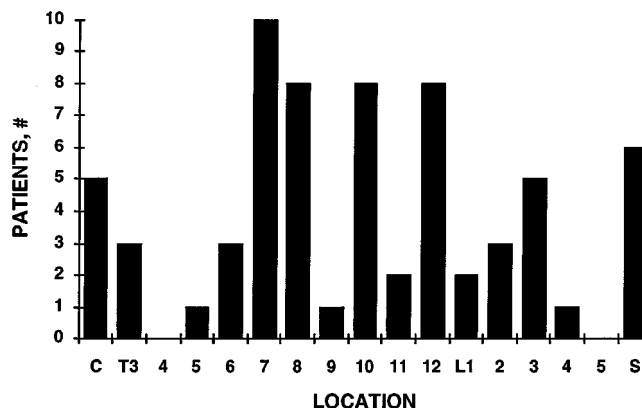


Fig 1. Location of the fistula in 66 patients. C indicates cranial; S, sacral.

repeat hand injection of 5 to 7 mL of contrast with a longer film series (typically 10 to 15 films) is made at intercostal levels that supply the fistula and the spinal arteries (anterior and posterior). If the site of the fistula is not identified, additional injections are made into the carotid, vertebral, and subclavian arteries bilaterally using appropriate contrast dose and rate with filming over the upper spine. A complete spinal angiogram typically extends over 2 days because of contrast dosage limitations.

The clinical parameters investigated in all 44 patients include age and sex, initial presenting symptom, clinical course, exam at presentation, and overall disability, using a scale of 0 to 5 for motor or sensory deficits and 0 to 6 for sphincter disturbance, with 0 being no disability and 5 or 6 representing total loss of function.

Results

Spinal Dural AVF Group

Spinal dural AVFs occurred in patients ranging from 37 to 81 years of age, with an average age of 62 years. The average length of time between onset of symptoms and diagnosis was 27 months (range, 3 months to 9 years). Fifteen patients (48%) had symptoms for 1 year or less and 21 patients (68%) had symptoms less than 2 years. Male subjects outnumbered female by 3.4:1. On spinal angiography, the nidus of the fistula was located most commonly between T-6 and L-3 (Fig 1).

The most common initial symptom was weakness, found in 55% (17 of 31). Numbness and pain were less frequent, seen in 29% and 13%, respectively. Most patients, 68% (21 of 31), experienced a chronic progressive clinical course, with the remainder experiencing a step-wise fluctuating clinical course. No patients presented with an acute or stable deficit. On initial examination, 45% (14 of 31) had myelopathy,

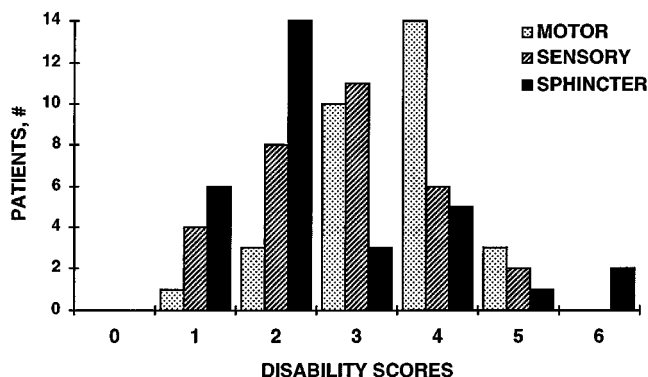


Fig 2. Disability scores in 31 patients with angiographically and surgically proved spinal dural AVF.

39% demonstrated both myelopathy and lower motor neuron signs, and 16% had lower motor neuron signs only. Most patients developed some degree of sphincter dysfunction by the time of the diagnosis. The disability scores are included in Figure 2.

Myelographic findings included the presence of prominent vessels in all patients (25 of 25), with vessels extending over an average of eight levels (range, 3 to 20 levels) (Fig 3). In the seven patients with plain-film tomography, the vessels were better seen on the tomogram in three, less well seen in three, and equally well identified in one. Beading of the cauda equina was present in 61% (14 of 23) (Fig 4).

On MR, increased T2 signal in the spinal cord was present in all patients in whom we could make this determination (30 of 30). The examination was indeterminate for T2-signal abnormality in one patient. The T2 signal was homogenous in appearance and central in location, sparing a thin rim of the cord peripherally. The abnormal signal extended over an average of seven levels (range, 1 to 11 levels) and involved the tip of conus 87% (26 of 30) of the time. Flow voids were less common, identified in 35% (11 of 31) of the exams on T1-weighted images and in 45% (14 of 31) on T2-weighted images. Mass effect was present in slightly less than one half of the cases (45%, 14 of 31). Abnormal enhancement was present in 88% (22 of 25) of the patients who received contrast. The enhancement was located within the dilated coronal venous plexus in 13, within the cord parenchyma in 5, and both within the venous plexus and parenchyma in 4 (Fig 5).

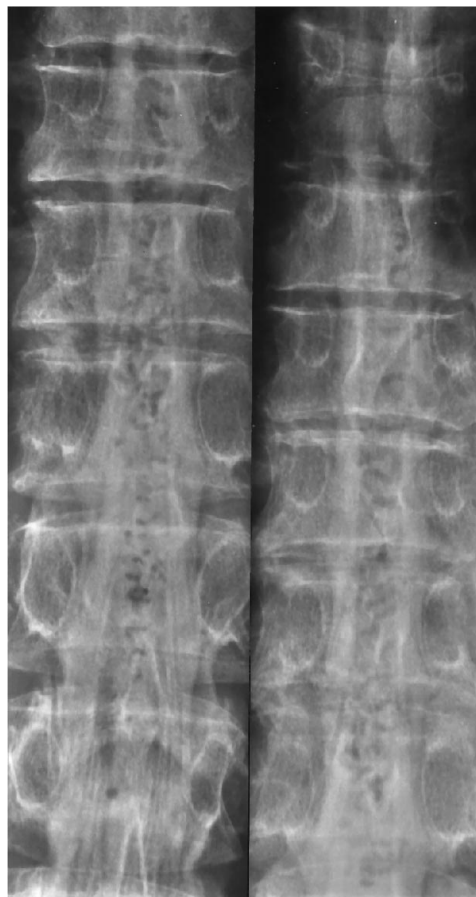


Fig 3. Supine myelogram images from a patient with a spinal dural AVF at S-1 demonstrate a dilated coronal venous plexus.

Negative Spinal Angiogram Group

The age range in the 16 patients with normal spinal angiograms was 32 to 74 years of age, with an average age of 51 years and a male-to-female ratio of 4.3:1. The average length of time from the onset of symptom to the spinal angiogram was 59 months (range, 4 days to 24 years). Seven patients (44%) had symptoms for 1 year or less, and nine patients (56%) had symptoms for less than 2 years.

The initial symptoms were numbness in 38% (6 of 16), pain in 38% (6 of 16), or weakness in 19% (4 of 16). Slightly over half (56%, 9 of 16) of the patients presented with a chronic progressive clinical course. Acute or stable deficits were present in 31% and a fluctuating clinical course in 13%. The most frequent neurologic examination findings at presentation were myelopathy in 56% (9 of 16) and lower motor neuron signs only in 44% (7 of 16). No patients in this group presented with a combination of my-

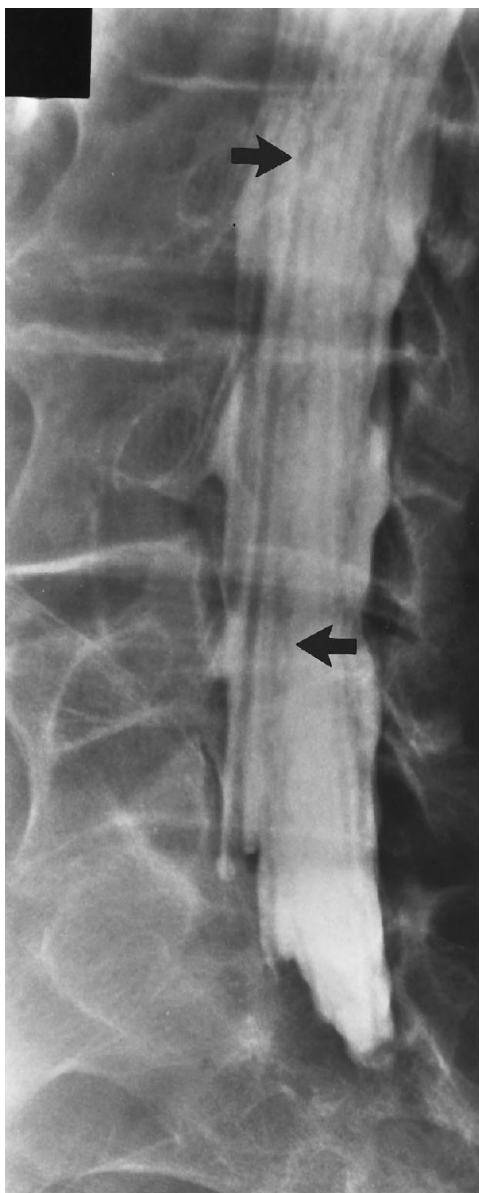

Fig 4. Dilated vessels extend along the nerve roots of the cauda equina in this patient with an L-1 spinal dural AVF, giving the roots a beaded appearance (arrows).

elopathy and lower motor neuron findings. The disability scores are included in Figure 6.

Vessels were identified on the myelogram in 92% (11 of 12), with the vessels extending over an average of six levels. The vessels were better seen on plain-film tomography in three patients and equally well identified in four patients. Beading of the cauda equina was present in two patients (17%).

Abnormal T2 signal was identified in the spinal cord in two patients (17%). One exam was indeterminate for T2-signal abnormality. Flow

voids were present in two patients (15%) on T2-weighted sequences only, and mass effect was present in one patient (8%). Abnormal contrast enhancement was observed in 6 of the 10 patients who received contrast. The enhancement was within the coronal venous plexus in five and both within the venous plexus and parenchyma in one. No patient had only parenchymal cord enhancement.

Discussion

Spinal dural AVFs are cryptic diagnoses that often are not considered by the referring clinician, and the MR findings are not recognized by the radiologist. This entity was described in 1977 by Kendall and Logue (11). The typical duration of symptoms before diagnosis is 2 to 6 years. In our series, almost half of the patients were diagnosed within 1 year, and in two thirds of the cases, the diagnosis was made by 2 years. This is an important diagnosis to make, because this condition is potentially treatable through surgical or embolization therapy (12). The diagnosis should be considered by the referring clinician but may first be suggested by the radiologist, which prompted our investigation of both the clinical presentation and imaging findings.

Spinal dural AVF was the most common spinal vascular malformation encountered in our review, representing 68% of all types. The fistula most often occurs in the thoracic region, although the nidus may be located anywhere along the spinal axis from the skull base (10, 12–15) (Gilbertson JR et al, "Posterior Fossa Dural Arteriovenous Fistula with Spinal Perimedullary Venous Drainage as a Cause of Myelopathy," abstract presented at the annual meeting of the American Society of Neuroradiology, May 1993) to the sacrum (10). Upper limb and cranial nerve symptoms have been described in patients with a cervical or intracranial nidus (13, 16, 17). In our series, the symptom complex observed was that of a progressive lower thoracic myelopathy, regardless of the location of the nidus.

The typical signs and symptoms of patients with spinal dural AVFs have been described by many authors (16, 18–20). Analysis of the clinical findings of these two study groups demonstrates that there is nothing specific about the presentation of patients with spinal dural AVFs. There is, however, a distinctive clinical pattern.

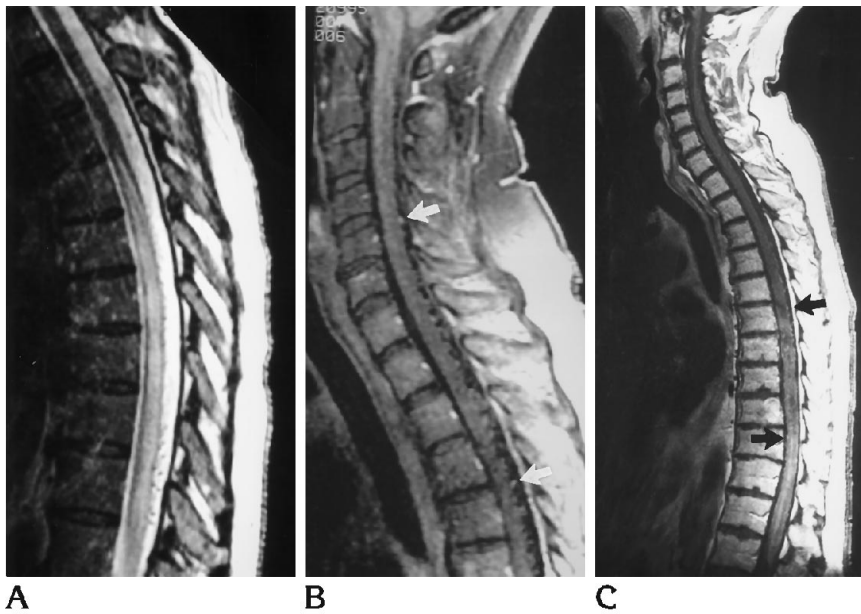


Fig 5. A, Abnormal T2 signal extends over six levels in this patient with a spinal dural AVF at L-3. Note the mild mass effect and flow voids dorsally (300/102/2).

B, Gadolinium-enhanced T1-weighted image in another patient with a spinal dural AVF at S-1 demonstrates flow voids and subtle coronal venous plexus enhancement (arrows) (450/23/2).

C, Mass effect, patchy parenchymal enhancement, and coronal venous plexus enhancement (arrows) are present in a patient with a T-7 spinal dural AVF. This patient had symptoms for 18 months before angiography (500/19/2).

The classic patient is an older man who presents with weakness and sensory loss, and myelopathy or mixed myelopathy/lower motor neuron pattern on exam, and has been gradually deteriorating over a number of years. Young people (less than 40 years of age) and patients presenting with an acute or stable deficit or pain as their only symptom are distinctly unusual.

The patients in the spinal dural AVF group clearly had greater disability, with nearly all developing some degree of sphincter dysfunction. It is uncertain how the disability scores relate to symptom duration, although many patients in the angiogram-negative group have had symptoms for a number of years and several patients with spinal dural AVFs had symptoms for only a short period of time.

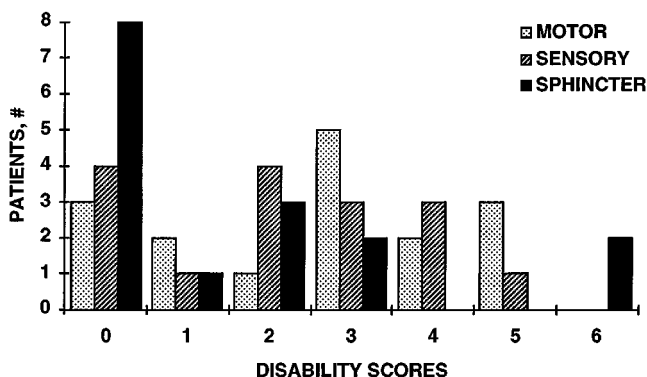


Fig 6. Disability scores in 16 patients with normal spinal angiograms.

Prone-supine myelography has long been the standard screening exam for spinal dural AVFs. Enlarged tortuous vessels on the supine film and beading of the cauda equina have been described in patients with spinal dural AVFs (1, 2). In our series, vessels were identified on the supine myelogram in all patients with spinal dural AVFs and in the patients with a negative angiogram. The appearance of the vessels in the negative angiogram group differed from the spinal dural AVF group in that they were generally not as dilated or tortuous, and this finding was much more subtle (Fig 7). However, there was overlap between the two groups of patients, and no definitive judgment could be made based on the appearance of the vessels on the myelogram, as has been noted by previous authors (1, 2). In fact, vessels on the supine myelogram were the reason for the referral to spinal angiography in 12 of the 13 patients with negative spinal angiograms. Beading of the cauda equina, a subtle and frequently overlooked finding, was present in 61% of our patients with spinal dural AVFs, compared with a previously reported sensitivity of 88% (2). This finding also was seen in two patients in the negative angiogram group.

Plain-film tomography has been a frequent addition to the prone-supine myelogram at our institution in an attempt to see the vessels better. This procedure did not increase the sensitivity of vessel detection. In all cases, vessels

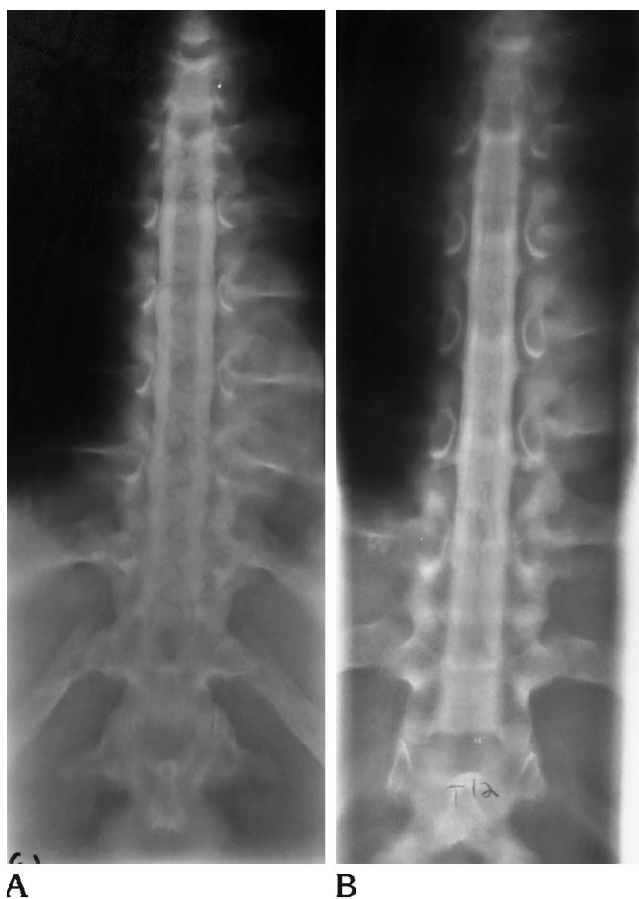

Fig 7. A, Postmyelogram supine tomograms in a patient with a spinal dural AVF at T-7. Note the dilated tortuous vessels, some of which make acute angle turns and others that extend beyond the spinal cord margin.

B, The vessels are not as dilated or tortuous in this patient with a normal spinal angiogram. These vessels corresponded to normal pial veins seen on the spinal angiogram.

that were identified on the tomogram also were seen on the supine films, although they were better seen on the tomogram in selected cases. We feel that if vessels are not identified on the supine film, plain-film tomography is probably unnecessary. There may be a few selected patients in whom tomography may help to better define vessels that are identified tentatively on the supine film or in cases in which the supine film is suboptimal because the contrast is too dilute.

Masaryk et al described the abnormal T2 signal changes in the spinal cord in patients with a dural fistula (8). Resolution or diminished T2-signal abnormality in combination with clinical improvement has been described in postoperative patients by Isu et al (6). The reversibility of the signal changes and clinical symptoms sup-

ports the accepted theory of venous hypertension and ischemia as the pathophysiology of symptoms, as proposed by Aminoff (21).

Increased T2 signal was present in all patients with spinal dural AVFs in our study, despite the variety of pulse sequences used (spin echo, gradient echo, or fast spin echo). We found this to be the most sensitive MR finding. Conversely, the absence of T2 change was associated with a high probability of a normal spinal angiogram. The presence of T2 signal on MR was a better predictor of a positive spinal angiogram than the identification of vessels on the myelogram, because nearly all of the patients with a negative spinal angiogram had vessels on the myelogram.

There were two patients in the negative group who demonstrated increased T2 signal in the cord and who deserve special discussion. Both patients had the typical imaging and clinical findings of patients with spinal dural AVFs. A presumptive diagnosis of neoplasm was made in one patient because of the presence of mass effect and parenchymal enhancement in addition to T2 signal changes, flow voids, and coronal venous plexus enhancement. An incomplete spinal angiogram was performed because of the presumptive diagnosis of neoplasm. A spinal dural AVF was discovered at surgery. The other patient had three negative spinal angiograms, including assessment of the intracranial vasculature. It was felt that this patient had a dural fistula that was either missed or spontaneously thrombosed.

Gadolinium is an important addition to the spine MR examination in all patients presenting with myelopathy. The sensitivity and specificity of the MR exam were increased in our series with gadolinium administration, because enhancement was present in most patients (88%) with spinal dural AVFs. Although enhancement of the coronal venous plexus also was noted in patients in the negative angiogram group (60%), the pattern of enhancement was different. The patients with dural fistulas have more dilated and tortuous vessels that extend in and out of the imaged volume on sagittal MR images, giving the appearance of discrete circular foci of enhancement on the dorsal surface of the cord (Fig 8). The enhancing vessels in the negative group were more subtle, vertically oriented, and less tortuous (Fig 9). With the exception of the two notable patients in the negative group, this pattern was very consis-

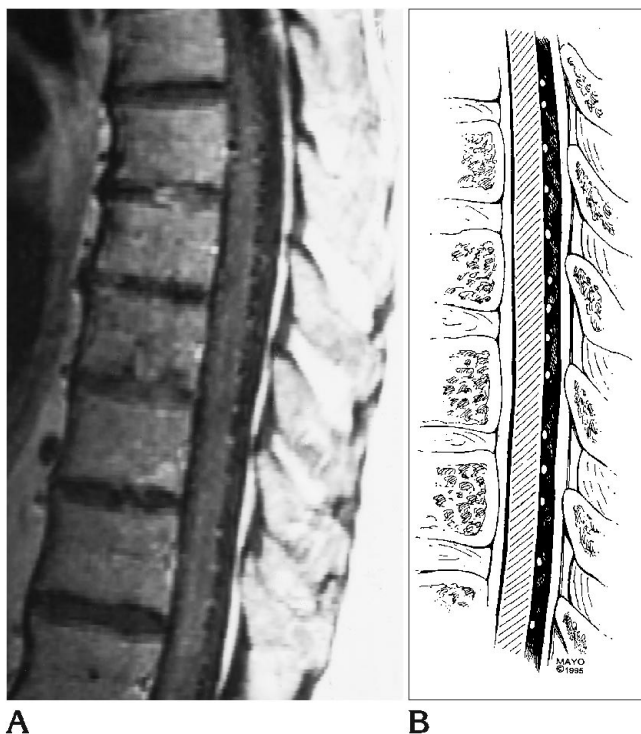

Fig 8. A, Circular dots of coronal venous plexus enhancement can be identified in this patient with a spinal dural AVF at L-1, as the dilated veins course in and out of the plane of section (pial veins in cross section) (500/19/2).

B, Drawing depicts the same finding.

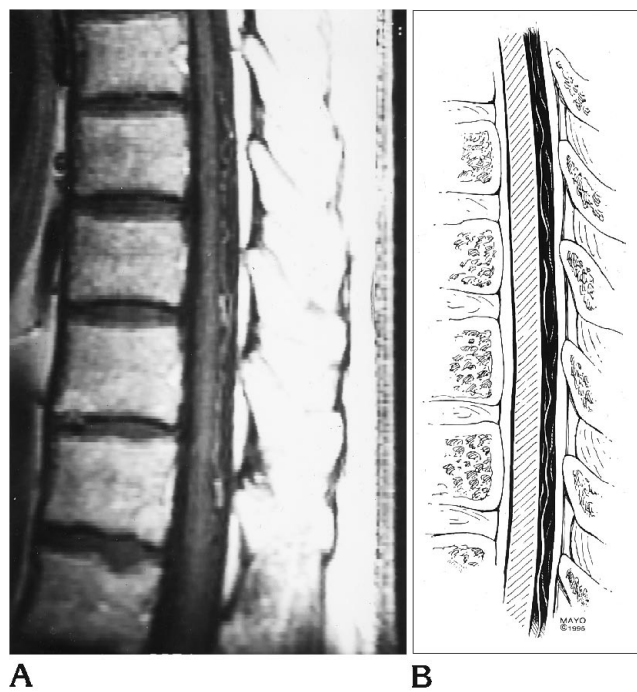


Fig 9. A, The venous plexus enhances in a more vertical fashion in this patient with a normal spinal angiogram and no abnormal T2 signal in the spinal cord (pial veins in profile). This is the same patient illustrated in Figure 7B (500/19/2).

B, Drawing depicts the same finding.

tent, seen in all positive and negative patients who received gadolinium. We believe that the vessels seen on myelography and the enhancement of the coronal venous plexus on MR in this group of patients with negative spinal angiograms most likely represent an unusually prominent but normal coronal venous plexus. Although it is not possible to exclude the possibility of a dural fistula in this group, we feel that this diagnosis is not likely based on the consistent imaging and clinical findings. In one patient, exact correlation was made with the subtle vessels noted on the myelogram and the normal coronal venous plexus seen on the venous phase of the spinal angiogram.

Some of the earliest investigators of MR findings in spinal dural AVFs described prominent flow voids along the dorsal surface of the cord on T2-weighted sequences or subtle flow voids, giving the cord a shaggy or scalloped appearance on T1-weighted images (4, 5, 8, 9). Flow voids were surprisingly uncommon in our study, seen in only 35% on T1- and 45% on T2-weighted sequences. Flow voids may be a help-

ful finding, but our experience is that they are not reliable and often are difficult to assess because of frequent problems distinguishing them from cerebrospinal fluid pulsation artifacts.

The association of mass effect in patients with spinal dural AVFs should be emphasized. The mass effect may extend over a long segment of the cord and was a relatively common finding, seen in 45% of patients with spinal dural AVFs. Like the enhancement and T2-signal changes, this finding corroborates the venous hypertension theory with resultant edema of the cord (19). The mass effect often was quite striking and should not discourage the diagnosis of spinal dural AVF in favor of another entity, such as neoplasm.

Enhancement of the coronal venous plexus increased T2 signal, and flow voids were seen in 48% of patients with spinal dural AVFs, and the combination of the former two findings was seen in 68%. No patient with a dural fistula had T2 signal abnormality as the only finding, which should help distinguish this condition from other causes of T2 signal, such as transverse myelitis,

neoplasm, or multiple sclerosis. All cases of spinal dural AVF were associated with additional findings, most frequently enhancement of the coronal venous plexus. With the exception of the one patient in the negative spinal angiogram group who had all three findings and a fistula discovered at surgery, no patient in this group demonstrated more than one finding. Although no one finding is specific, these combinations in the appropriate clinical setting are certainly highly suspect, and further evaluation with spinal angiography is warranted. It is also critical that the MR exam be of high quality, particularly for the T2-weighted sequences, as exemplified by the two patients (one in each study group) who had indeterminate T2 series caused by suboptimal exams.

MR angiography has been used to image directly the dilated coronal venous plexus in patients with spinal vascular malformations, including spinal dural AVFs (22, 23). Phase-contrast MR angiography (rather than time-of-flight) is preferred because of a higher sensitivity to slow flow and an ability to determine the velocity of flow. Gelbert et al (22) identified the dilated coronal venous plexus in two patients with spinal dural AVFs, using a two-dimensional pulse sequence in the sagittal plane. Provenzale et al (23) found three-dimensional MR angiography in the coronal plane to be the most useful technique to visualize the vessels. Both authors found that MR angiography was unable to determine the site of the fistula and did not obviate the need for spinal angiography. We did not specifically perform MR angiography examinations on our patients. However, from these preliminary reports, it would appear that phase-contrast MR angiography may further increase the sensitivity of conventional MR in the diagnosis of spinal dural AVFs.

Our data support the conclusion that MR is the initial screening procedure of choice. A combination of high T2 signal (physiologic evidence of a spinal dural AVF and either flow voids or enhancement of an enlarged coronal venous plexus (anatomic evidence of a spinal dural AVF) indicates a high probability of an existing vascular malformation, and spinal angiography is indicated. If T2 signal is the only finding and there is a high index of clinical suspicion, a supine myelogram should be obtained before spinal angiography. The likelihood of finding a spinal dural AVF in a patient with a

normal MR is low. However, these patients probably deserve a supine myelogram if there is a high index of suspicion clinically, because spinal dural AVF is a potentially treatable cause of myelopathy. Once a decision is made to pursue a spinal angiogram, a complete study should be done, including intracranial assessment. The importance of completing a spinal angiogram is exemplified by the patient who had a fistula discovered at surgery after an incomplete spinal angiogram. Our data indicate that as many as 17% of spinal dural AVFs will be located outside the typical thoracolumbar region.

References

1. Meder JF, Chiras J, Barth MO, N'Diaye M, Bories J. Myelographic features of the normal external spinal veins. *J Neuroradiol* 1984; 11:315-325
2. N'Diaye M, Chiras J, Meder JF, Barth MO, Koussa A, Bories J. Water-soluble myelography for the study of dural arteriovenous fistulae of the spine draining in the spinal venous system. *J Neuroradiol* 1984;11:327-339
3. DiChiro G, Doppman JL, Dwyer AJ, et al. Tumors and arteriovenous malformations of the spinal cord: assessment using MR. *Radiology* 1985;156:689-697
4. Doppman JL, DiChiro G, Dwyer AJ, Frank JL, Oldfield EH. Magnetic resonance imaging of spinal arteriovenous malformations. *J Neurosurg* 1987;66:830-834
5. Dormont D, Gelbert F, Assouline E, et al. MR imaging of spinal cord arteriovenous malformations at 0.5 T: study of 34 cases. *AJNR Am J Neuroradiol* 1988;9:833-838
6. Isu T, Iwasaki Y, Akino M, Koyanagi I, Abe H. Magnetic resonance imaging in cases of spinal dural arteriovenous malformation. *Neurosurgery* 1989;6:919-923
7. Larsson E-M, Desai P, Hardin CW, Story J, Jinkins JR. Venous infarction of the spinal cord resulting from dural arteriovenous fistula: MR imaging findings. *AJNR Am J Neuroradiol* 1991;12: 739-743
8. Masaryk TH, Ross JS, Modic MT, Ruff RL, Selman WR, Ratcheson RA. Radiculomeningeal vascular malformations of the spine: MR imaging. *Radiology* 1987;164:845-849
9. Minami S, Sagoh T, Nishimura K, et al. Spinal arteriovenous malformations: MR imaging. *Radiology* 1988;169:109-115
10. Partington MD, Rufenacht DA, Marsh WR, Piepgras DG. Cranial and sacral dural arteriovenous fistulas as a cause of myelopathy. *J Neurosurg* 1992;76:615-622
11. Kendall BE, Logue V. Spinal epidural angiomatous malformations draining into intrathecal veins. *Neuroradiology* 1977;13:181-189
12. Nichols DA, Rufenacht DA, Jack CR, Forbes GS. Embolization of spinal dural arteriovenous fistula with polyvinyl alcohol particles: experience in 14 patients. *AJNR Am J Neuroradiol* 1992;13:933-940
13. Gaensler EH, Jackson DE, Halbach VV. Arteriovenous fistulas of the cervicomedullary junction as a cause of myelopathy: radiographic findings in two cases. *AJNR Am J Neuroradiol* 1990;11: 518-521

14. Versari PP, D'Aliberti G, Talamonti G, Branca V, Boccardi E, Collice M. Progressive myelopathy caused by intracranial dural arteriovenous fistula: report of two cases and review of the literature. *Neurosurgery* 1993;33:914-919
15. Wrobel CJ, Oldfield EH, DiChiro G, Tarlov EC, Baker RA, Doppman JL. Myelopathy due to intracranial dural arteriovenous fistulas draining intrathecally into spinal medullary veins: report of three cases. *J Neurosurg* 1988;69:934-939
16. Symon L, Kuyama H, Kendall B. Dural arteriovenous malformations of the spine: clinical features and surgical results in 55 cases. *J Neurosurg* 1984;60:238-247
17. Gobin YP, Rogopoulos A, Aymard A, et al. Endovascular treatment of intracranial dural arteriovenous fistulas with spinal perimedullary venous drainage. *J Neurosurg* 1992;77:718-723
18. Criscuolo GR, Oldfield EH, Doppman JL. Reversible acute and subacute myelopathy in patients with dural arteriovenous fistulas: Foix-Alajouanine syndrome reconsidered. *J Neurosurg* 1989;70:354-359
19. Rosenblum B, Oldfield EH, Doppman JL, DiChiro G. Spinal arteriovenous malformations: a comparison of dural arteriovenous fistulas and intradural AVMs in 81 patients. *J Neurosurg* 1987;67:795-802
20. Tobin WD, Layton DD. The diagnosis and natural history of spinal cord arteriovenous malformations. *Mayo Clin Proc* 1976;51:637-646
21. Aminoff MJ, Barnard RO, Logue V. The pathophysiology of spinal vascular malformations. *J Neurol Sci* 1974;23:255-263
22. Gelbert F, Guichard J, Mourier KL, et al. Phase-contrast MR angiography of vascular malformations of the spinal cord at 0.5 T. *J Magn Reson Imaging* 1992;2:631-636
23. Provenzale JM, Tien RD, Felsberg GJ, Haccin-Bey L. Spinal dural arteriovenous fistula: demonstration using phase contrast MRA. *J Comput Assist Tomogr* 1994;18:811-814