

Are your **MRI contrast agents** cost-effective?

Learn more about generic **Gadolinium-Based Contrast Agents**.



FRESENIUS  
KABI

caring for life

# AJNR

## **The value of MR in differentiating subligamentous from supraligamentous lumbar disk herniations.**

C S Silverman, L Lenchik, P M Shimkin and K L Lipow

*AJNR Am J Neuroradiol* 1995, 16 (3) 571-579

<http://www.ajnr.org/content/16/3/571>

This information is current as  
of April 19, 2024.

# The Value of MR in Differentiating Subligamentous from Supraligamentous Lumbar Disk Herniations

Craig S. Silverman, Leon Lenchik, Peter M. Shimkin, and Kenneth L. Lipow

**PURPOSE:** To determine the value of MR criteria in differentiating subligamentous from supraligamentous lumbar disk herniations. **METHODS:** A retrospective review of surgical reports and MR images of 50 patients undergoing first-time lumbar surgery was performed. Three MR imaging criteria were assessed: the presence and integrity of a low-signal-intensity line posterior to the disk herniation, the size of the disk herniation in comparison with the size of the spinal canal, and the presence of disk fragments. Correlation was made with surgical findings to determine the value of these MR criteria in differentiating subligamentous from supraligamentous disk herniations. **RESULTS:** For determining subligamentous disk herniations: the presence of a continuous low-signal-intensity line posterior to the disk herniation was 29% sensitive, 65% specific, and 42% accurate; disk herniation size less than 50% of the size of the spinal canal was 64% sensitive, 47% specific, and 58% accurate; and the absence of disk fragments was 88% sensitive, 12% specific, and 62% accurate. Combinations of individual MR criteria did not improve diagnostic accuracy. **CONCLUSIONS:** For differentiating subligamentous from supraligamentous lumbar disk herniations, none of the MR imaging criteria assessed was reliable.

**Index terms:** Spine, magnetic resonance; Spine, intervertebral disks, herniation; Spine, ligaments

*AJNR Am J Neuroradiol* 16:571-579, March 1995

Percutaneous diskectomy was introduced in 1975 (1) and has since become an accepted alternative to open diskectomy for treatment of lumbar disk herniations in select cases (2-14). Reported (3-14) success rates for percutaneous diskectomy range from 60% to 87%. Many clinical and radiologic criteria have been proposed (13) for the selection of patients for percutaneous diskectomy. Containment of the disk herniation by the posterior longitudinal ligament is one of the radiologic criteria (13). Magnetic resonance (MR) imaging has been reported to be accurate in determining the integrity of the posterior longitudinal ligament (15). The purpose of this study was to assess the value of MR imaging in determining the integrity of the posterior longitudinal ligament, thus differentiating

subligamentous from supraligamentous lumbar disk herniations.

## Methods

We retrospectively reviewed the surgical reports of 78 consecutive patients who had MR imaging within 6 months before an open diskectomy. Only those patients undergoing first-time lumbar surgery for a single level lumbar disk herniation (n=50) were included in the study. The study group included 25 male and 25 female subjects 15 to 78 years old (mean, 46 years). The surgeries were performed by one of two neurosurgeons at a single tertiary care hospital between October 1992 and September 1993. All MR imaging was performed between June 1992 and September 1993. The interval between MR imaging and surgery ranged from 1 to 184 days (mean, 44 days).

The study population was subdivided further into two groups based on the interval between MR imaging and surgery to determine whether a prolonged interval between imaging and surgery affects the accuracy of imaging criteria. The interval between MR imaging and surgery was less than or equal to 1 month for the short-interval group of 29 patients and between 1 month and 6 months for the long-interval group of 21 patients.

Surgical findings included 33 (17 short interval and 19 long interval) disk herniations contained by the posterior longitudinal ligament and 17 (15 short interval and 2 long

---

Received May 26, 1994; accepted after revision September 2.

From the Departments of Radiology (C.S.S., L.L., P.M.S.) and Neurosurgery (K.L.L.), Bridgeport (Conn) Hospital.

Address reprint requests to Craig S. Silverman, MD, Bridgeport Hospital, Department of Radiology, 267 Grant St, Bridgeport, CT 06610.

*AJNR* 16:571-579, Mar 1995 0195-6108/95/1603-0571

© American Society of Neuroradiology

interval) not contained by the posterior longitudinal ligament. Disk herniations contained by the posterior longitudinal ligament were defined as subligamentous, whereas disk herniations not contained by the posterior longitudinal ligament were defined as supraligamentous. There were 4 L3-4, 24 L4-5, and 22 L5-S1 disk herniations.

MR imaging was performed with a 1.5-T unit using a quadrature receive-only thoracic/lumbar spine coil. Sagittal T1-weighted sequences (500/11/2 [repetition time/echo time/excitations], 256 × 192 image matrix, 4-mm section thickness, 1-mm gap), sagittal proton-density and T2-weighted dual-echo fast spin-echo sequences (2100/16/2, 2100/96/2, 256 × 192 image matrix, 3-mm section thickness, 1-mm gap), and axial proton-density and T2-weighted dual-echo fast spin-echo sequences (2600/18/2, 2600/108/2, 256 × 192 image matrix, 4-mm section thickness, 0.1 to 1.0 mm gap) of the lumbar spine were obtained on all patients.

One neuroradiologist, without knowledge of the clinical data or surgical findings, reviewed each MR study. All sagittal and proton-density axial sequences were used to assess for three criteria of integrity of the posterior longitudinal ligament. The first two criteria were adopted from previous literature (15, 16). The first criterion, a low-signal-intensity line posterior to the disk herniation, was interpreted as continuous, interrupted, or absent. The second criterion, the size of the disk herniation, was interpreted as less than 50% or greater than 50% of the size of the spinal canal based on the anteroposterior dimension of the disk herniation relative to the anteroposterior dimension of the spinal canal. The third criterion was the presence of herniated disk fragments.

The MR imaging findings were correlated with the surgical findings to determine the ability of the MR imaging criteria to differentiate subligamentous from supraliga-

mentous disk herniations. True-positives for integrity of the posterior longitudinal ligament were defined as cases in which MR imaging showed a continuous low-signal-intensity line posterior to the disk herniation, the size of the disk herniation to be less than 50% of the spinal canal, or absence of disk fragments. True-negatives were defined as cases in which MR imaging showed an interrupted or absent low-signal-intensity line posterior to the disk herniation, the size of the disk herniation to be greater than 50% of the spinal canal, or the presence of disk fragments.

Statistical analysis included determining the sensitivity, specificity, and accuracy of the MR imaging criteria, both individually and in combination. The predictive values of the MR imaging criteria were calculated using Bayes's theorem.

## Results

Table 1 compares the ability of each MR imaging criterion to predict the integrity of the posterior longitudinal ligament at surgery. The low-signal-intensity line posterior to the disk herniation was confidently identified as continuous (Figs 1 and 2), interrupted (Fig 3), or absent (Fig 4) in 48 of 50 cases. In 2 of the 50 cases this criterion was not confidently identified as continuous, interrupted, or absent on all sagittal sequences. In these two cases, T1-weighted and proton-density sagittal images showed an interrupted low-signal-intensity line, whereas T2-weighted sagittal images showed a continuous low-signal-intensity line. To allow more accurate comparison with prior studies,

**TABLE 1: Comparison of MR criteria in determining subligamentous lumbar disk herniations**

MR criteria	TP	FP	TN	FN	Sensitivity, %	Specificity, %	Accuracy, %	Positive PV, %	Negative PV, %
Continuous low signal line posterior to herniation (n=48)	9	6	11	22	29	65	42	60	33
Herniation size less than 50% of spinal canal (n=50)	21	9	8	12	64	47	58	70	40
Absence of disk fragment (n=50)	29	15	2	4	88	12	62	66	33

Note.—TP indicates number of true-positive cases of subligamentous disk herniations for each of MR imaging criteria; FP, false-positive; TN, true-negative; FN, false-negative; and PV, predictive value.




Fig 1. A and B. Continuous low-signal-intensity line posterior to a surgically proven subligamentous disk herniation.

A, Sagittal proton-density (2100/16) and B, axial proton-density (2600/18) fast spin-echo images show a continuous low-signal-intensity line (*short arrow*) posterior to the L5-S1 disk herniation (*long arrows*). At surgery, a subligamentous disk herniation was detected.

the two equivocal cases were excluded from the statistical analysis of this criterion.

Comparing the criteria, the 58% accuracy of disk herniation size (Figs 5 and 6) and the 62% accuracy of disk fragments (Figs 7 and 8) were slightly better than the 42% accuracy of a continuous low-signal-intensity line, at the expense of lower specificity.

The combination of a continuous low-signal-intensity line and the size of the disk herniation less than 50% of the size of the spinal canal was 27% sensitive, 71% specific, and 42% accurate in determining subligamentous disk herniations. The combination of a continuous low-signal-intensity line posterior to the disk herniation or the size of the disk herniation less than 50% of the size of the spinal canal was 64% sensitive, 41% specific, and 56% accurate in determining subligamentous disk herniations. Statistical analysis of the remaining six combinations of individual criteria did not show improved diagnostic accuracy.

Statistical analyses of the three MR imaging criteria for the short-interval and long-interval subgroups of patients are provided in Table 2. There was no improvement in diagnostic accuracy of the criteria for the short-interval subgroup. All three criteria were slightly more sensitive for the long-interval subgroup but at the expense of no specificity.

## Discussion

MR imaging of the lumbar spine often is used in the selection of patients for lumbar disk surgery. Percutaneous discectomy has become an accepted alternative to open discectomy for the treatment of disk herniation in select cases (2-14). Percutaneous discectomy operates on the principle that decreased intradiskal pressure results in a transmitted decrease in pressure on the affected nerve root (13). Some fibers of the annulus fibrosus or the posterior longitudinal





Fig 2. A and B. Continuous low-signal-intensity line posterior to a surgically proved supraligamentous disk herniation.

A, Sagittal proton-density (2100/16) fast spin-echo image shows a continuous low-signal-intensity line (*arrow*) posterior to the L5-S1 disk herniation.

B, Axial proton-density (2600/18) fast spin-echo image shows the L5-S1 disk herniation (*large arrowhead*) surrounded by a low-signal-intensity line (*small arrowheads*). At surgery, a supraligamentous disk herniation was detected. A small segment of the posterior longitudinal ligament is obscured by the thicker low signal line at the anteriormargin of the thecal sac (*open arrow*), which is artifactual. This artifact explains the false-positive MR interpretation in this patient.

Fig 3. *A* and *B*. Interrupted low-signal-intensity line posterior to the disk herniation.

*A*, Sagittal proton-density (2100/16) and *B*, axial proton-density (2600/18) fast spin-echo images show a low-signal-intensity line (*black arrow*) superior and posterior, but not inferior (*arrowhead*), to the L4-5 disk herniation (*white arrow*). At surgery, a subligamentous disk herniation was detected.



ligament must be intact for this procedure to be successful (13, 17).

Clinical and radiologic criteria have been proposed (13) for the selection of patients for percutaneous discectomy. The clinical criteria include sciatica, physical findings that correlate with the pain, and failure of conservative therapy (13). Imaging has been considered valuable in identifying disk herniations contained by the annulus fibrosus or posterior longitudinal ligament and in excluding free fragments (13). In particular, MR imaging has been reported to be accurate in determining whether a disk herniation is contained by the posterior longitudinal ligament (15). Other causes of back and leg pain, which may exclude patients from percutaneous discectomy, including spinal stenosis, facet disease, synovial cysts, calcified disks, multilevel disk herniations, and neoplasms of the spine, also are identified with MR imaging (13, 17).

Grenier et al (15), in a prospective study of 17 patients with 19 lumbar disk herniations, reported 100% sensitivity and 78% specificity of MR imaging in detecting disruption of the posterior longitudinal ligament. In their study, 8 (100%) of 8 disk herniations in which MR imaging showed disruption or absence of a low-signal-intensity line posterior to the disk herniation were found at surgery to be supraligamentous, whereas 7 (78%) of 9 disk herniations in which MR imaging showed a continuous low-signal-intensity line were found to be subligamentous. Unlike Grenier et al, we found the presence of a continuous low-signal-intensity line posterior to the disk herniation to be much less sensitive (29%) in determining subligamentous disk herniations. The discrepancy cannot be explained on the basis of patient selection alone, because both studies evaluated only surgical patients and both had a comparable number of subligamentous and supraligamentous

Fig 4. *A* and *B*. Absent low-signal-intensity line posterior to the disk herniation.

*A*, Sagittal proton-density (2100/16) and *B*, axial proton-density (2600/18) fast spin-echo images show absence of a low-signal-intensity line (*black arrow*) posterior to the L5-S1 disk herniation (*white arrow*). At surgery, a subligamentous disk herniation was detected.






Fig 5. A and B. Size of the disk herniation less than 50% of the spinal canal.

A, Sagittal proton-density (2100/16) and B, axial proton-density (2600/18) fast spin-echo images show the size of the disk herniation (*arrows*) to be less than 50% of the spinal canal in an anteroposterior dimension. The low-signal-intensity line (*arrow-head*) posterior to the disk herniation may represent the displaced posterior longitudinal ligament. At surgery, a subligamentous disk herniation was detected.

disk herniations. In our series, 33 (66%) of 50 patients had subligamentous disk herniations compared with 8 (58%) of 19 disk herniations in the series of Grenier et al. Technical differences between our series and the series of Grenier et al do not account for the discrepancy in our results. The study by Grenier et al was performed with a 0.5-T magnet, a  $256 \times 256$  image matrix, and 6-mm section thickness on all sagittal sequences. Our study was performed with a 1.5-T magnet, a  $256 \times 192$  image matrix, and 4-mm section thickness on sagittal T1-weighted sequences and 3-mm section thickness on sagittal proton-density and T2-weighted fast spin-echo sequences. The higher resolution used in our study should have improved accuracy instead of reducing it.

Fries et al (16), in a prospective study of computed tomography scans of 188 patients with 244 disk explorations, reported that the size of the herniated nucleus pulposus corre-

lated with the presence of an extruded herniated nucleus pulposus. When the size of the herniated nucleus pulposus was less than 50% of the size of the spinal canal, an extruded herniated nucleus pulposus was absent in 90% (118 of 131). When the size of the herniated nucleus pulposus was 50% or greater, an extruded herniated nucleus pulposus was present in 91% (53 of 57). In our series, only 21 (70%) of 30 patients with the disk herniation size less than 50% of the size of the spinal canal had subligamentous disk herniations, and only 8 (40%) of 20 patients with the disk herniation size greater than 50% had supraligamentous disk herniations. The difference in the two series may be attributable to the authors' definitions of a disk herniation, in particular, an "extruded herniated nucleus pulposus." Whereas we defined the types of disk herniations in reference to the posterior longitudinal ligament, Fries et al did not define an extruded herniated nucleus pulpo-





Fig 6. A and B. Size of the disk herniation greater than 50% of the spinal canal.

A, Sagittal proton-density (2100/16) and B, axial proton-density (2600/18) fast spin-echo images show the size of the disk herniation (*arrows*) to be greater than 50% of the spinal canal in an anteroposterior dimension. At surgery, a supraligamentous disk herniation was detected.

Fig 7. *A* and *B*. The presence of a herniated disk fragment with a surgically proved subligamentous disk herniation.

*A*, Sagittal proton-density (2100/16) and *B*, axial proton-density (2600/18) fast spin-echo images show a well-circumscribed disk fragment (*arrows*) that has migrated inferiorly from the L4-5 parent disk material. At surgery, a subligamentous disk herniation was detected.



sus in reference to the annulus fibrosus or the posterior longitudinal ligament.


There is some inconsistency in the literature regarding the terminology of disk herniations (13, 17, 18). For example, Onik and Helms (13) define a disk herniation that is contained by the annulus fibrosus or the posterior longitudinal ligament as a protrusion and a disk herniation that is not contained by the posterior longitudinal ligament as an extrusion. Czervionke (18), on the other hand, defines a disk herniation as a protrusion when it is intraannular and as an extrusion when the disk material has passed through the annulus fibrosus. An extruded disk may be found either anterior or posterior to the posterior longitudinal ligament, thus defining subligamentous and supraligamentous disk herniations, respectively (18). A free disk fragment is defined as disk material that is not in continuity with the parent disk material (18). The free disk fragment, also re-

ferred to as a sequestered disk, may be found either anterior or posterior to the posterior longitudinal ligament (18). Mink (17) proposes a different classification of disk herniations in which an extrusion is defined as an herniated nucleus pulposus that has passed completely through the annulus fibrosus but not through the posterior longitudinal ligament. The term *free fragment* is used when the posterior longitudinal ligament is disrupted (17). An extruded herniation and a free fragment can be either in continuity or without continuity with the disk, the latter location defining a sequestered fragment (17).

In our series, the absence of a disk fragment was 88% sensitive in predicting subligamentous disk herniations, but it lacked specificity (12%) and was not reliable in differentiating subligamentous from supraligamentous disk herniations. Four (67%) of six patients who on MR imaging showed a disk fragment were found at

Fig 8. *A* and *B*. The presence of a herniated disk fragment with a surgically proved supraligamentous disk herniation.

*A*, Sagittal proton-density (2100/16) and *B*, axial proton-density (2600/18) fast spin-echo images showing a disk fragment (*arrows*) that has migrated inferiorly from the L4-5 parent disk material. At surgery, a supraligamentous disk herniation was detected.



surgery to have subligamentous disk herniations (Fig 7), whereas two (33%) of six patients who on MR imaging showed a disk fragment were found to have supraligamentous disk herniations (Fig 8). This supports the classification of disk herniations proposed by Czervionke (18) in which a free disk fragment may be found either anterior or posterior to the posterior longitudinal ligament.

Some of our false-negative and false-positive cases may be explained by the natural history of disk herniations. Bozzao et al (19) reported a reduction in the size of lumbar disk herniations of more than 30% in 41 (63%) of 65 patients and a reduction of more than 70% in 10 (15%) of 65 patients treated without surgery. A comparable reduction in the size of disk herniations may account for some of our false-negative cases. Some of our false-positive cases may be explained by deterioration of the patients' symptoms during the interval between MR imaging and surgery. Bozzao et al reported an increase in the size of lumbar disk herniations in 5 (8%) of 65 patients, which supports this. The natural history of disk herniations is perhaps more applicable to the false-positive and false-negative cases using the criterion of the size of the disk herniation, because the criteria of a low-signal-intensity line posterior to the disk herniation and the presence of disk fragments were not evaluated by Bozzao et al. However, the interval between initial MR imaging and follow-up MR im-

aging (mean, 11 months) in the series of Bozzao et al was considerably longer than the interval between MR imaging and surgery (mean, 44 days) in our series. The method of evaluating the size of the disk herniation in comparison with the spinal canal was different in our series as well. Whereas Bozzao et al based the measurement on a volumetric evaluation of the disk herniation relative to the spinal canal at that level, we evaluated the anteroposterior dimension of the disk herniation relative to the anteroposterior dimension of the spinal canal. The natural history of disk herniations also may account for some of the discrepancy in results between our series and the series of Grenier et al (15). There was a difference in the study populations with respect to the interval between MR imaging and surgery. The interval between MR imaging and surgery was 2 to 10 days in the series of Grenier et al and 1 to 184 days in our series.

We evaluated the role of the natural history of disk herniations by subdividing our study population based on the time interval between MR imaging and surgery. We found no significant improvement in the diagnostic accuracy of the criteria for the subgroup of patients for whom the interval was less than or equal to 1 month when compared with both the corresponding subgroup of patients for whom the interval was between 1 and 6 months and the original study population. The results suggest that the differ-

TABLE 2: Comparison of MR criteria in determining subligamentous lumbar disk herniations for the subgroups with a short interval and long interval between MR imaging and surgery

MR Criteria	Short-Interval* Subgroup				Long-Interval† Subgroup			
	N	Sensitivity, %	Specificity, %	Accuracy, %	N	Sensitivity, %	Specificity, %	Accuracy, %
Continuous low signal line posterior to herniation	28	23	73	50	20	33	0	30
Herniation size less than 50% of spinal canal	29	57	53	55	21	68	0	62
Absence of disk fragment	29	79	13	45	21	95	0	86

\*Less than or equal to 1 month.

†Between 1 and 6 months.



ences between our findings and those of Bozzao et al (19) and Grenier et al (15) may not be related to the natural history of disk herniations.

The low diagnostic accuracy of the MR imaging criterion of a low-signal-intensity line posterior to the disk herniation may be explained by the limited spatial resolution of MR imaging. Volume averaging secondary to section thickness may prevent accurate differentiation between a continuous posterior longitudinal ligament and a posterior longitudinal ligament with a small defect, as well as between a very thin attenuated, but continuous, posterior longitudinal ligament and an interrupted or absent posterior longitudinal ligament. Additionally, MR imaging may not allow one to differentiate the posterior longitudinal ligament and the annulus fibrosus as two distinct structures. The posterior longitudinal ligament and the annulus fibrosus may be imaged as a complex, posterior to the disk herniation. In our series, 16 of 50 surgical reports used other descriptive terminology, which may explain our results. All 16 cases were subligamentous disk herniations. An additional description of a "large subannular extrusion contained by a very thin remaining membrane," confirmed by the neurosurgeon to be a thin annular remnant, was used in 11 of 16 of these surgical reports. The MR criterion of a low-signal-intensity line posterior to the disk herniation was interpreted as either interrupted (Fig 3) or absent (Fig 4) in 10 (91%) of 11 of these cases and continuous in 1 (9%) of 11. The remaining 5 of 16 surgical reports used an additional description of a "protrusion." The MR imaging criterion of a low-signal-intensity line posterior to the disk herniation was interpreted as continuous in 4 (80%) of 5 of these cases and interrupted in 1 (20%) of 5. The results show that there may be limitations in preoperative identification of the posterior longitudinal ligament with MR imaging. In particular, small defects in the posterior longitudinal ligament and attenuation of part or all of the posterior longitudinal ligament may not be detected. Therefore, differentiation between a normal posterior longitudinal ligament, an interrupted posterior longitudinal ligament, and an absent posterior longitudinal ligament may not be possible in many cases.

The differences in MR imaging techniques also may play a role in the evaluation of the posterior longitudinal ligament. In our study, sagittal fast spin-echo images were more useful

in the evaluation of the posterior longitudinal ligament than axial fast spin-echo images. The differences may be caused by volume averaging, because with the sagittal sequences we used 3-mm sections, whereas with the axial sequences we used 4-mm sections. Gradient-echo techniques have been shown to be useful in the evaluation of extradural disease of the cervical spine (20). Applications such as three-dimensional techniques with increased signal-to-noise ratio and more accurate thin sections may further improve the evaluation of the spine (21). The impact of these techniques on the evaluation of the posterior longitudinal ligament and on the ability of MR imaging in differentiating subligamentous from supraligamentous lumbar disk herniation requires further investigation.

The low diagnostic accuracy of MR imaging criteria in predicting subligamentous disk herniations poses a dilemma for the selection of patients for percutaneous discectomy. Diskography has been reported as useful before chemonucleolysis, a percutaneous procedure used in the treatment of lumbar disk herniations (22). In the series by Tournade et al (22), diskographic demonstration of contrast extravasation through a defect in the posterior longitudinal ligament was a contraindication for subsequent injection of the nucleolytic enzyme. Although false-negative diskography studies can occur when the nuclear cavity is not continuous with the site of the herniation (23), diskography may play a similar role in patient selection for percutaneous discectomy. A defect seen in the posterior longitudinal ligament would, by current imaging criteria, exclude a patient from percutaneous discectomy. However, the criteria for patient selection for percutaneous discectomy are not precise enough to mandate diskography before each percutaneous discectomy. The high success rates of percutaneous discectomy, despite the low diagnostic accuracy of imaging criteria in predicting subligamentous disk herniations, suggest that a disk herniation contained by the posterior longitudinal ligament may not be a necessary prerequisite for a successful percutaneous discectomy.

Although MR imaging has an essential role in the evaluation of intervertebral disk disease, in our series all three MR imaging criteria evaluated were not reliable in differentiating subligamentous from supraligamentous disk herniations. Our results suggests that less emphasis

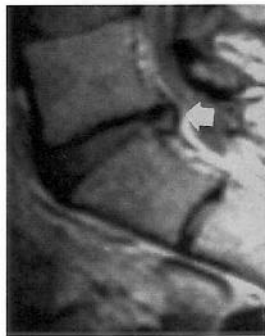
should be placed on MR criteria that predict disk herniation containment by the posterior longitudinal ligament. MR imaging should be used in the selection of patients for percutaneous discectomy only in conjunction with clinical criteria.

### Acknowledgment

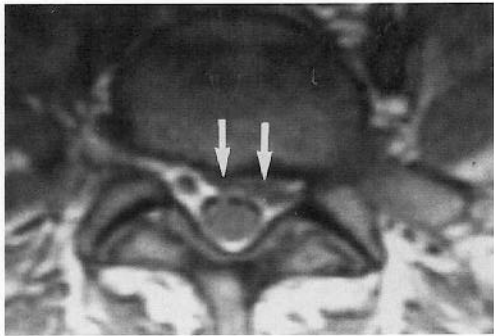
We thank Dr Ruben Kier for his editorial advice.

### References

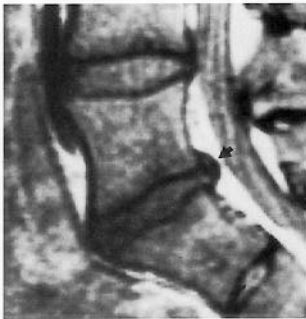- Hijkata S, Yamagishi M, Nakayama T, Oomori K. Percutaneous nucleotomy: a new treatment method for lumbar disc herniation. *J Toden Hosp* 1975;5:5-13
- Onik G, Helms CA, Ginsburg L, Hoaglund FT, Morris J. Percutaneous discectomy using a new aspiration probe. *AJNR Am J Neuroradiol* 1985;6:290-293
- Hijkata S. Percutaneous nucleotomy: a new concept technique and 12 years' experience. *Clin Orthop* 1989;238:9-23
- Kambin P, Schaffer JL. Percutaneous lumbar discectomy. *Clin Orthop* 1989;238:24-34
- Schreiber A, Suezawa Y, Leu H. Does percutaneous nucleotomy with discoscopy replace conventional discectomy? Eight years of experience and results in treatment of herniated lumbar disc. *Clin Orthop* 1989;238:35-42
- Maroon JC, Onik G, Sternau L. Percutaneous automated discectomy: a new approach to lumbar surgery. *Clin Orthop* 1989;238:64-70
- Goldstein TB, Mink JH, Dawson EG. Early experience with automated percutaneous lumbar discectomy in the treatment of lumbar disc herniation. *Clin Orthop* 1989;238:77-82
- Davis GW, Onik G. Clinical experience with automated percutaneous lumbar discectomy. *Clin Orthop* 1989;238:98-103
- Graham CE. Percutaneous posterolateral lumbar discectomy: an alternative to laminectomy in the treatment of backache and sciatica. *Clin Orthop* 1989;238:104-106
- Onik G, Mooney V, Maroon JC, et al. Automated percutaneous discectomy: a prospective multi-institutional study. *Neurosurgery* 1990;26:228-232
- Bonaldi G, Belloni G, Prosetti D, Moschini L. Percutaneous discectomy using Onik's method: 3 years' experience. *Neuroradiology* 1991;33:516-519
- Schreiber A, Leu HJ. Percutaneous nucleotome: technique with discoscopy. *Orthopedics* 1991;14:439-444
- Onik G, Helms CA. Automated percutaneous lumbar discectomy. *AJR Am J Roentgenol* 1991;156:531-538
- Koutrouvelis PG, Lang E, Heilen R, Koulizakis EN. Stereotactic percutaneous lumbar discectomy. *Neurosurgery* 1993;32:582-586
- Grenier N, Greselle J-F, Vital J-M, et al. Normal and disrupted lumbar longitudinal ligaments: correlative MR and anatomic study. *Radiology* 1989;171:197-205
- Fries JW, Abodeely DA, Vijungco JG, Yeager VL, Gaffey WR. Computed tomography of herniated and extruded nucleus pulposus. *J Comput Assist Tomogr* 1982;6:874-887
- Mink JH. Imaging evaluation of a candidate for percutaneous lumbar discectomy. *Clin Orthop* 1989;238:83-91
- Czervionke LF. Lumbar intervertebral disc disease. *Neuroimag Clin North Am* 1993;3:465-485
- Bozzao A, Gallucci M, Masciocchi C, Aprile I, Barile A, Passariello R. Lumbar disk herniation: MR imaging assessment of natural history in patients treated without surgery. *Radiology* 1992;185:135-141
- VanDyke C, Ross JS, Tkach J, Masaryk TJ, Modic MT. Gradient-echo MR imaging of the cervical spine: evaluation of extradural disease. *AJNR Am J Neuroradiol* 1989;10:627-632
- Ross JS, Tkach J, VanDyke C, Modic MT. Clinical MR imaging of degenerative spinal diseases: pulse sequences, gradient-echo techniques, and contrast agents. *J Magn Reson Imaging* 1991;1:29-37
- Tournade A, Patay Z, Tajahmady T, Braun JP, Million S, Schmutz G. Contribution of discography to the diagnosis and treatment of lumbar disc herniation. *J Neuroradiol* 1991;18:1-11
- Yasuma T, Ohno R, Yamauchi Y. False negative lumbar discograms: correlation of discographic and histological findings in postmortem and surgical specimens. *J Bone Joint Surg Am* 1988;70:1279-1290



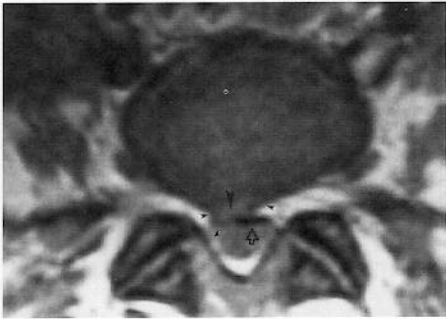**A**



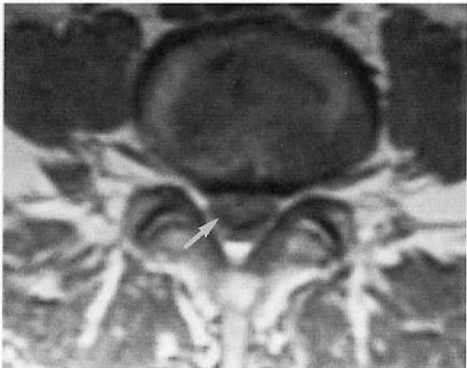
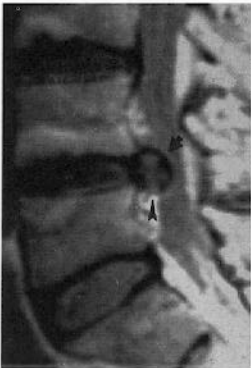**B**



**A**

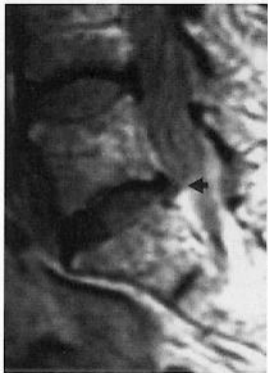


**B**

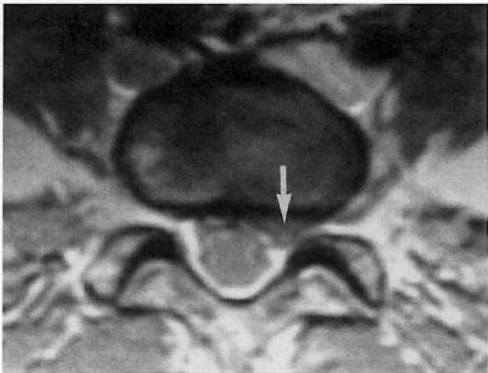


A

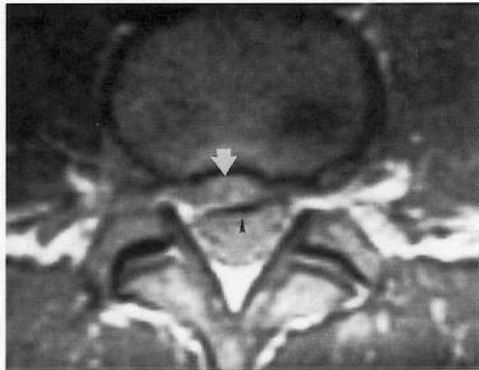
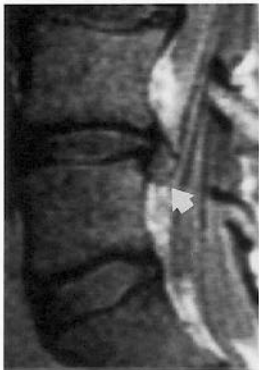B



A

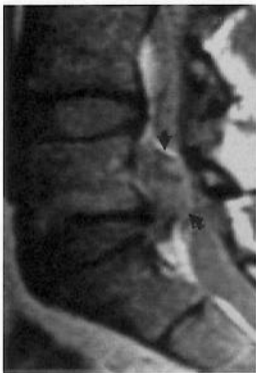

B

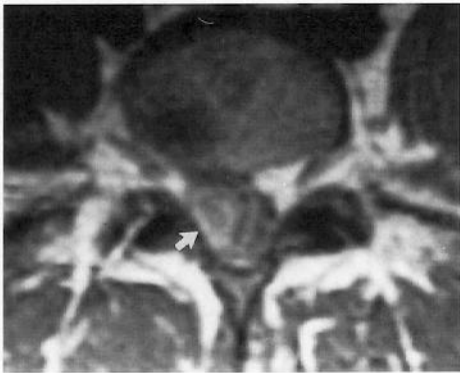


A

B



A

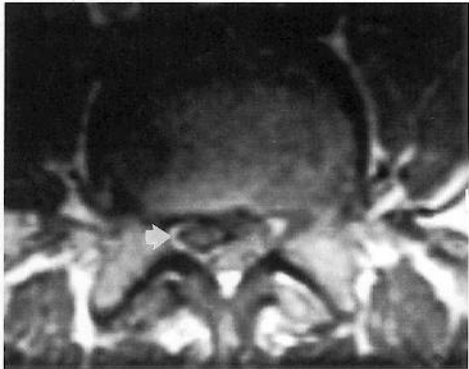


B

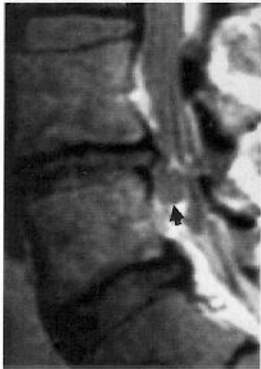




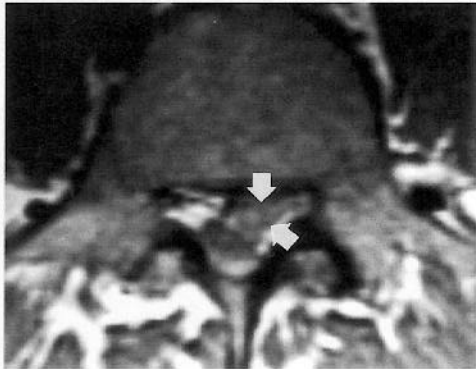
A



B



A



B