AJNR

Experimental maxillofacial arterial chemoembolization with encased-cisplatin ethylcellulose microspheres.

J Yang, X C Ma, Z J Zou and S L Wei

AJNR Am J Neuroradiol 1995, 16 (5) 1037-1041
http://www.ajnr.org/content/16/5/1037

Experimental Maxillofacial Arterial Chemoembolization with Encased-Cisplatin Ethylcellulose Microspheres

Jie Yang, Xu-chen Ma, Zhao-ju Zou, and Shu-li Wei

PURPOSE: To compare chemoembolization with conventional chemotherapy and explore the possibility of chemoembolization in the oral and maxillofacial region using encased-anticancer-drug microspheres. **METHOD:** Six mongrel dogs were divided into two equal groups, an experimental group undergoing maxillofacial arterial chemoembolization with cisplatin encased in ethylcellulose microspheres, and a control group undergoing the conventional chemotherapy with cisplatin. The peripheral venous cisplatin concentration and the cisplatin concentration at the local tissue were determined. **RESULT:** The experiment showed a significant difference in the peripheral venous cisplatin concentration between the two groups and between the time period. There was also a significant interaction between groups and time. The peak concentration in the experimental group appeared 12 to 24 hours after chemoembolization. The peak concentration in the control group appeared immediately after the anticancer drug was infused. There was a significant difference in the concentration in the local tissue between the two groups, when all time periods were aggregated. **CONCLUSION:** Compared with conventional chemotherapy, the maxillofacial arterial chemoembolization with cisplatin encased in ethylcellulose microspheres significantly decreases the cisplatin concentration in the peripheral venous circulation and increases the concentration in the local tissues, allowing for the possibility of target cancer therapy.

Index terms: Chemotherapy; Interventional materials, particles and microspheres; Animal studies

AJNR Am J Neuroradiol 16:1037–1041, May 1995

Surgery, radiation, and chemotherapy are considered to be the three major methods of treating head and neck malignant neoplasms. When the tumor reaches an advanced stage, at which it can not be excised or successfully treated with radiation, chemotherapy is the accepted method of management.

Conventional chemotherapy leads to the fast distribution of the anticancer drugs throughout the body and often results in severe side effects or complications, such as kidney and/or liver dysfunction, or bone marrow suppression (1–6). Because of the severe side effects, the dose often must be reduced or, occasionally, drug administration must be stopped.

In the early 1970s, Kato and coworkers began to experiment with chemoembolization using a combination of transcatheter arterial embolization with chemotherapy (7–10). In the 1980s, chemoembolization was commonly applied to the treatment of primary and secondary malignant tumors in the liver, kidney, lung, bone, and intrapelvic organs (11–18). However, there has been little investigation of chemoembolization in treatment of oral and maxillofacial cancer (19).

For this reason, after gaining experience with selective arterial embolization of the external carotid arterial pedicles, we investigated chemoembolization in the oral and maxillofacial region. We hypothesized that chemoembolization would allow administration of a high dose of drug in the area of the maxillary artery while sparing the rest of the body exposure to such a high dose.

Received July 6, 1994; accepted after revision November 28.

From the Department of Oral Pathology, Radiology, and Medicine, College of Dentistry, Iowa City, IA (J. Y.); and the School of Stomatology (X.-C. M., Z-j. Z.) and Pharmaceutics (S.-I. W.), Beijing Medical University, Beijing, People's Republic of China.

Address reprints to Jie Yang, DDS, MM, Department of Oral Pathology, Radiology, and Medicine, College of Dentistry, University of Iowa, Iowa City, IA 52242

AJNR 16:1037–1041, May 1995 0195-6108/95/1605–1037

Materials and Methods

Six mongrel dogs (15 to 17 kg) were randomized into two groups: (*a*) three in group A, undergoing maxillofacial arterial chemoembolization; and (*b*) three in group B, undergoing intravenous chemotherapy as the control group.

In group A, the encased-cisplatin ethylcellulose microspheres were used as emboli for chemoembolization. The microspheres were tested and produced by the School of Pharmaceutics. The yellow microspheres, with good distribution and suspended in 76% Urografin (combination of sodium diatrizoate and meglumine diatrizoate), passed easily through 4.5F, 5F, and 7F polyethylene catheters. The diameters of the microspheres were within the range of 216 μm to 441 μm. The microspheres contain 30% cisplatin and 20% barium sulfate. Anesthesia was induced using 3% sodium barbital (1 mL/kg). Using Seldinger's technique through the femoral artery and under fluoroscopic control, we guided the tips of the catheters to the orifices of the external carotid arterial pedicles. One hundred fifty milligrams of cisplatin encased in ethylcellulose microspheres containing 45 mg cisplatin was administrated via transarterial catheter to embolize the maxillary and superficial temporal arteries of each dog of the experimental group. Angiographs were made before and after chemoembolization. No hydration was undertaken before or after chemoembolization.

Two-milliliter peripheral venous blood samples were taken from the anterior leg vein at 10 minutes, 30 minutes, 1 hour, 2 hours, 4 hours, 6 hours, 8 hours, 12 hours, 24 hours, 48 hours, 72 hours, 7 days, 10 days, and 14 days after chemoembolization. Each sample was treated as follows: the sample was placed into a stationary plastic tube for 10 minutes before being centrifuged for 20 minutes (4000 rpm). The upper plasma (0.200 mL) was treated with 0.1% Triton X-100 (octoxynol). The concentration of cisplatin was determined with flameless atomic absorption spectrometry.

Under general anesthesia (see above), small biopsies (approximately 2 × 2 × 2 mm) of muscle tissue were taken through an incision made in the oral mucosa of the upper lip of the same side as the infusion side, at 0 to 2 hours, 6 to 8 hours, 2 to 3 days, and 6 to 8 days after chemoembolization. Immediately the tissues were frozen in dry ice–acetone bath for storage. The first biopsy of each dog was 5 mm away from the midline to avoid any contralateral blood supply. Following the first biopsy, a second, third, and fourth biopsy were taken on the same side at 15, 25, and 35 mm, respectively, lateral to the first biopsy. The specimens were ground in a homogenizer, the resulting homogenate was treated with 0.1% Triton X-100, and the concentration of cisplatin with flameless atomic absorption spectrometry was determined.

Animals in group B were treated identically except that 30 mg cisplatin was intravenously infused, and adequate hydration was ensured before and after the drug was infused. Two-milliliter peripheral venous blood samples from the anterior leg vein were taken at 10 minutes, 30 minutes, 1 hour, 2 hours, 4 hours, 6 hours, 8 hours, 12 hours, 24 hours, 48 hours, 72 hours, and 7 days after the drug was infused. Small biopsies of muscle tissue in upper lip were taken as for group A.

Table 1: Cisplatin concentrations (μg/mL) of peripheral venous blood after chemoembolization with cisplatin encased in ethylcellulose microspheres (group A) and intravenous chemotherapy with cisplatin (group B)

Time, h	Group A				Group B			
	Dog 1	Dog 2	Dog 3	Mean	Dog 4	Dog 5	Dog 6	Mean
0.2	0.094	0.246	0.246	0.195	2.093	3.432	2.516	2.680
0.5	0.183	0.246	0.092	0.174	1.300	2.039	1.544	1.631
1	0.231	0.085	0.185	0.167	0.777	1.500	1.046	1.108
4	0.271	0.123	0.192	0.195	0.827	0.946	0.616	0.796
6	0.364	0.150	0.158	0.224	0.800	0.981	0.639	0.806
8	0.457	0.177	0.150	0.261	0.769	1.016	0.631	0.805
12	0.481	0.169	0.165	0.272	0.623	0.439	0.500	0.687
24	0.658	0.023	0.177	0.286	0.485	†	0.492	0.488
48	0.392	0.092	0.108	0.197	0.354	†	0.454	0.404
72	0.194	0.000	0.138	0.111	0.292	†	0.308	0.300
120	···	0.000	0.160	0.080	0.273	†	0.254	0.264
168	···	0.000	0.254	0.127	0.254	†	0.196	0.225
240	0.085	0.000	0.117	0.067	···	†	0.138‡	0.138
360	0.015	0.000	0.072	0.029	···	†	···	···

Note.—A temporal ulcer occurred in dog 2 one week after chemoembolization. The ulcer healed in 4 weeks.

† The dog died 15 hours later after the 30 mg cisplatin was infused.

‡ The sample was taken in 192 hours after intravenous infusion.

Analysis of variance F tests for cisplatin concentrations in the peripheral venous blood was calculated for the two groups. At the various time periods from 10 minute to 360 hours mentioned above, as well as for the interaction between the groups and the various time periods. In addition, Student's *t* tests were performed to determine further whether there were significant differences at any of time periods. For cisplatin concentrations in the muscle tissues of the upper lips, only the Student's *t* tests were performed to determine the difference between the two groups for all time periods from 0 to 2 hours to 6 to 8 days. This was done because there were limited data points compared with the data points for the venous cisplatin concentrations.

Results

The cisplatin concentrations of the peripheral venous blood after chemoembolization and conventional chemotherapy (see Table 1) were determined. Analysis of variance F tests showed a significant difference of the peripheral venous cisplatin concentrations between the two groups ($F = 152.02$, $P = .001$) and between the different time periods from 0.2 hours to 360 hours ($F = 11.96$, $P = .001$). There also was a significant group-by-time interaction ($F = 13.44$, $P = .001$). This interaction indicated that the peripheral venous cisplatin concentrations

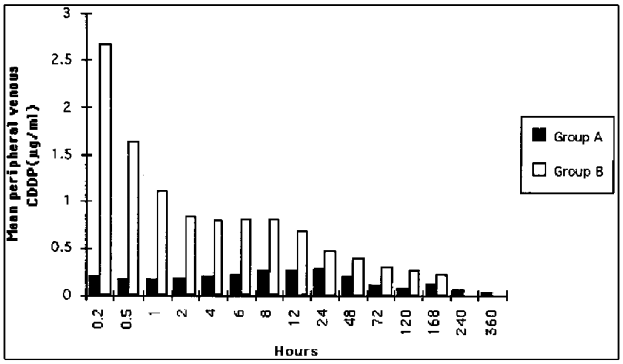

Fig 1. Variable peripheral venous cisplatin (CDDP) concentrations (mean) of the two groups in multiple biopsy time interval. Student's t test: $P < .05$ for time periods of 0.2 through 8 hours.

Table 2: Cisplatin concentrations (μg/mg) in the muscles of the upper lip of the dogs in the multiple biopsy time intervals

Group	Dog	Cisplatin concentrations in the local tissues, μg/mg			
		0–2 h	6–8 h	2–3 d	6–8 d
A	1	0.169	1.573	0.082	1.425
	2	5.309	6.178	1.824	10.457
	3	...	7.302	3.609	...
B	4	0.000	0.008	0.023	0.000
	5	0.154	0.028	†	†
	6	...	...	...	...

† The dog died later after the 30 mg cisplatin was infused.

of the two groups did not change in the same way over the different time periods. As shown in Figure 1, the peak concentration in group A appeared 12 to 24 hours after chemoembolization, but the peak concentration in group B appeared immediately after the anticancer drug was infused. Post hoc t tests indicated that differences of the peripheral venous cisplatin concentrations of the two groups were significant ($P < .05$) for time periods 0.2 hours to 8 hours, but that after 8 hours none of the group differences was significant.

The cisplatin concentrations in the upper lips of the two groups at various times are shown in Table 2. Based on Student's t tests, significant differences of the cisplatin concentrations in the muscle tissues of the upper lips exist between the two groups for all time periods combined in each group ($t = 3.46$, $P = .007$).

Discussion

Ethylcellulose microspheres are a common microsphere system for drug delivery (20). Although the microspheres are biodegradable, the microspheres can remain in the tissue at least 6 to 8 weeks (unpublished data). The anticancer drugs are released mainly through micropores in the microspheres (21). Numerous reports exist regarding sustained releasing of anticancer drugs from the ethylcellulose microspheres in vivo and in vitro (10, 11, 21, 22).

In this study, we did not compare direct transarterial infusion of cisplatin with chemoembolization using the ethylcellulose microspheres. Pharmacokinetic studies have demonstrated the advantage of an intraarterial compared with an intravenous infusion of the same anticancer drug (23, 24). However, some clinical studies have shown no significant differences of cisplatin levels in tumor, serum, and urine between an intraarterial and an intravenous infusion of cisplatin to tumor (25, 26). Chemoembolization combines transcatheter arterial embolization with chemotherapy. The potential therapeutic effect of chemoembolization comes from both the infarction and the sustained local drug action (11, 27). Head and neck tumors often are localized and obtain most of their blood supply from the external carotid artery branches (28). Occlusion of the external carotid arterial branches may inhibit the growth of the tumor, cause tumor regression, convert inoperable tumors to operable tumors, and diminish bleeding in the following surgical procedures. In addition, sustained drug release can reduce systemic toxicity of the anticancer drug.

Although the dogs in group A received 1.5 times more cisplatin than those in group B and did not undergo hydration, the cisplatin concentrations in the peripheral venous blood were much lower than in group B (Table 1). Analysis of variance demonstrates that there was a significant difference in the peripheral venous cisplatin concentration between group A and group B. The peak cisplatin concentration in the peripheral venous blood of group A was only one ninth that of group B (Fig 1). Because chemoembolization can significantly reduce the anticancer drug's concentration, especially peak concentration, in the peripheral venous blood, we hypothesize that chemoembolization could reduce the severe side effects or toxicity of the anticancer drug. In other words, chemoemboli-

zation might help us administer higher doses of anticancer drugs to treat oral and maxillofacial cancer without increasing the extent of severe side effects.

Figure 1 shows the variable peripheral venous cisplatin concentration of the two groups with time. A significant difference in the mean peripheral venous blood cisplatin concentration existed between the two groups in time periods of 0.2 through 8 hours (Student's t test; $P <$ .05). There was no significant difference between the two groups after 8 hours. In group B, the peripheral venous cisplatin concentration reached its peak immediately after the anticancer drug was intravenously infused and quickly decreased to a low level. This could be caused by fast distribution, metabolism, or clearance. In group A, unlike in group B, the peripheral venous cisplatin concentration increased gradually to a peak in 12 to 24 hours, then decreased to a low point by the end of the following week. This result suggests that cisplatin encased in ethylcellulose microspheres has sustained-release properties. The results of this experiment are similar to those obtained by Kato (7) with chemoembolization in renal arteries.

The cisplatin concentrations in the local tissues among the experimental dogs at different times (Table 2) were not as uniformly distributed as those of the peripheral venous blood. This finding might be a result of the tissue specimen variation, inasmuch as we could not take specimens at the same anatomic point as with the peripheral venous blood. Different anatomic points have different blood vessel supplies and thus a potentially different amount of cisplatin encased in ethylcellulose microspheres. In addition, local healing effects also may contribute to irregularity of the cisplatin concentrations in local tissues. However, the cisplatin concentrations in the local tissue in group A were much higher than in group B. Student's t test demonstrates a significant difference between group A and group B ($t = 3.46$, $P = .007$) when all time periods were aggregated. These results indicate that maxillofacial arterial chemoembolization significantly increased the concentration of the anticancer drug in the oral and maxillofacial region and has the potential for target cancer therapy. In this experiment, although the three dogs in group A received more anticancer drugs and underwent more trauma (caused by the emoblization procedure) than did the dogs in group B, all the dogs with chemoembolization survived the experiment. Dog 2 had a temporal ulcer 1 week after chemoembolization, but the ulcer healed in 4 weeks. The ulcer probably related to an ischemic complication attributable to distal occlusion of external carotid artery branches. In group B, on dog died 15 hours after the intravenous anticancer drugs were administered. The cause of death may have been that the single dose of chemotherapy was too high (the dose used was based on the dose for humans) and that the drug quickly entered the general circulation, resulting in a high peak cisplatin concentration in the blood and severe side effects or toxicity. If the latter were the case, the theory that conventional chemotherapy may cause severe side effects that can be avoided or reduced with chemoembolization is supported.

The microspheres used in this experiment pass more easily through the catheter than microcapsules (7, 19) because of their smooth surface and better suspension and distribution. The microspheres contain 20% barium sulfate, which contributes to the smooth surface and better suspension and distribution, and allows their distribution to be monitored with fluoroscopy.

The blood to the brain and eye is predominantly supplied by the internal carotid artery. Embolization of the external carotid artery is considered relatively safe (29), and we did not observe severe neurologic deficits or retinal edema in our three chemoembolized dogs. However, the use of small microspheres (smaller than 300 μm) still carries the risk of collateral distribution to important neural structures (29, 30). To increase the safety of chemoembolization of the external carotid arterial branches, one should use the largest microspheres that will not decrease the curative effect of chemoembolization.

Acknowledgments

We thank Axel Ruprecht, DDS, MScD, FRCD(C), and Shi-Liang Sun, MD, Professors of Radiology, University of Iowa, for reviewing the manuscript, Xian-Rong Qi, MSc, School of Pharmaceutics, Beijing Medical University, for assisting with determination of cisplatin concentration, and Jane Jakobsen, MA, for assistance with the statistical analyses.

References

1. Safirstein R, Winston, J. Goldstein M, et al. Cisplatin nephrotoxicity. *Am J Kidney Dis* 1986;8:356–367
2. Fjeldborg P, Sorensen J, Helkjaer PE. The long-term effect of cisplatin on renal function. *Cancer* 1986;58:2214–2217
3. Tanaka H, Ishidawa E, Teshima S, Shimizu E. Histopathological study of human cisplatin nephropathy. *Toxicol Pathol* 1986;14: 247–257
4. Finley RS, Fortner CL, Grove WR. Cisplatin nephrotoxicity: a summary of preventative interventions. *Drug Intell Clin Pharm* 1985;19:362–367
5. Coons HL, Leventhal H, Nerenz DR, Love RR, Larson S. Anticispatory nausea and emotional distress in patients receiving cisplatin-based chemotherapy. *Oncol Nurs Form* 1987;14:31–35
6. Rothmann SA, Paul P. Weick JK, McIntyre WR, Fantelli F. Effect of cis-diammine-dichloroplatinum on erythropoietin production and hematopoietic progenitor cells. *Int J Cell Cloning* 1985;3: 415–423
7. Kato T, Nemoto R, Kumagai I, NIshimoto T, Mori H. Studies on microencapsulated mitomycin C into arterial infusion of microencapsulated mitomycin-C into the dog kidney. *J Jap Soc Cancer Ther* 1979;14:157–163
8. Kato T, Nemoto R, Mori H, Kumagai I. Microencapsulated mitomycin-D therapy in renal cell carcinoma. *Lancet* 1979;2:479–480
9. Kato T, Nemoto R. Microencapsulation of mitomycin C for intra-arterial infusion chemotherapy. *Proc Jap Acad* 1978;54:413–417
10. Kato T, Nemoto R, NIshimoto T. Ex vivo intra-arterial infusion of microencapsulated mitomycin C into dog kidney. *Tohoku H Exp Med* 1979;127:99–100
11. Kato T, Nemoto R, Mori H, Kumagai I. Sustained-release properties of microencapsulated mitomycin C with ethylcellulose infused into the renal artery of the dog kidney. *Cancer* 1980;46:14–21
12. Fujimoto S, Miyazaki M, Endoh F, et al. Mitomycin C carrying microspheres as a novel method of drug/delivery. *Cancer Drug Del* 1985;2:173–181
13. Nemoto R, Kato T, Iwata K, Mori H, Takahashi M. Evaluation of therapeutic arterial embolization in renal cell carcinoma using microencapsulated mitomycin C. *Urology* 1981;17:315–319
14. Nemoto R, Kato R. Experimental intro-arterial infusion of microencapsulated mitomycin C into pelvic organs. *Br J Urol* 1981; 53:225–227
15. Yodono H, Saito Y, Saikawa Y, et al. Combination chemoembolization therapy for hepatocellular carcinoma: mainly, using cisplatin (CDDP). *Cancer Chemother Pharmacol* 1989;23 (Suppl)S42–44
16. Kato T, Nemoto R, Mori H, et al. Arterial chemoembolization with microencapsulated anticancer drug. *JAMA* 1981;245:1123–1127
17. Kato T, Nemoto R, Mori H, Takahashi M, Tamakawa Y. Transcatheter arterial chemoembolization of renal cell carcinoma with microencapsulated mitomycin C. *J Urol* 1981;125:19–24
18. Li J, Zhao YN, Miao ZJ, et al. Tissue tolerance to pelvic intraarterial chemoembolization with cisplatin-lipiodol suspension. *Gynecol Oncol* 1993;50:10–14
19. Okamoto Y, Konno A, Togawa K, Kato T, Amano Y. Microcapsule chemoembolization for head and neck cancer. *Arch Otorhinolaryngol* 1985;242:105–111
20. Lee PI, Good WR. *Controlled-Release Technology: Pharmaceutical Applications.* Washington, DC: American Chemical Society, 1987:201–202
21. Davis SS, Illum L, McVie JG, Tomlinson E. *Microspheres and Drug Therapy: Pharmaceutical Immunological and Medical aspects.* New York: Elsevier, 1984:229–243
22. Fujimoto S, Endoh F, Kitsukawa Y, et al. Continued in vitro and in vivo release of an antitumor drug albumin microspheres. *Experientia* 1983;39:913–916
23. Dedrick RL. Review; Arterial drug infusion: pharmacokinetic problems and pitfalls. *J Natl Cancer INst* 1988;802:84–89
24. Echman WW, Patlak CS, Fenstermacher JD. A critical evaluation of the principles governing the advantages of intra-arterial infusions. *J Pharmacokinet Biopharm* 1974;2:257–285
25. Gouyette A, Apchin A, Foka M, Richards, J. Pharmacokinetics of intra-arterial and intravenous cisplatin in head and neck cancer patients. *Eur J Cancer Clin Oncol* 1986;22:257–263
26. Bielack SS, Erttmann R, Looft G, et al. Platinum disposition after intraarterial and intravenous infusion of cisplatin for osteosarcoma. *Cancer Chemother Pharmacol* 1989;24:376–380
27. Nemoto R, Kumagai I, Mori H, Kato T, Harada M. Studies on microencapsulated anticancer drugs, IV: chemoembolization effect of intra-arterial infusion with microencapsulated mitomycin C on dog kidneys. *J Jap Soc Cancer Ther* 1979;14:1150–1157
28. Wheeler RH, Ziessman HA, Medvec BR, et al. Tumor blood flow and systemic shunting in patients receiving intraarterial chemotherapy for head and neck cancer. *Cancer Res* 1986;46: 4200–4204
29. Robert NM, Lory SM, John G. Central retinal and posterior ciliary artery occlusion after particle embolization of the external carotid artery system. *Ophthalmology* 1991;98:527–531
30. Braun IF, Levy S, Hoffman JC. The use of transarterial microembolization in the management of hemangiomas of the perioral region. *J Oral Maxillofac Surg* 1985;43:239–248