

Are your MRI contrast agents cost-effective?
Learn more about generic Gadolinium-Based Contrast Agents.



AJNR

MR of central nervous system actinomycesis.

B Funaki and J D Rosenblum

AJNR Am J Neuroradiol 1995, 16 (5) 1179-1180
<http://www.ajnr.org/content/16/5/1179.citation>

This information is current as
of April 19, 2024.

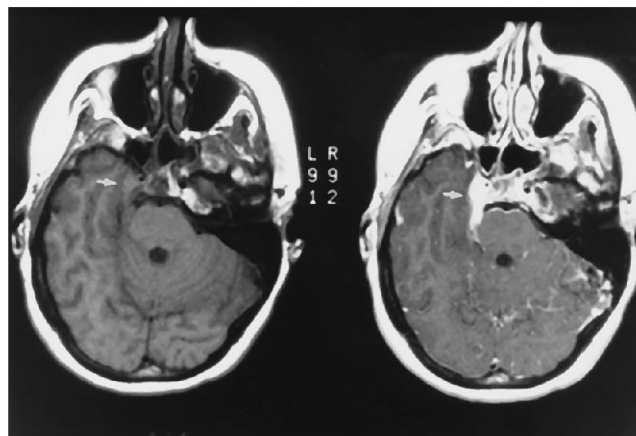
LETTER

MR of Central Nervous System Actinomycosis

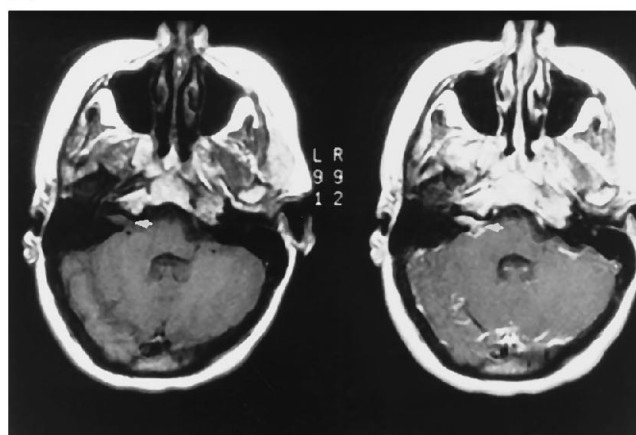
Actinomycosis is caused by a species of the genus *Actinomyces*, which can affect the head and neck, abdomen, cardiopulmonary, and central nervous systems (CNS). CNS actinomycosis is a rare disease, with only 70 reported cases since 1937 (1). We recently encountered a 40-year-old woman with a 4-month history of headaches, intermittent diplopia, vomiting, and right retroorbital pain relieved only with potent analgesics. On physical exam, she had a right cranial nerve VI paresis, right facial droop, and lethargy. T1-weighted MR images showed an area of signal abnormality isointense to brain parenchyma in the right cavernous sinus that encased and narrowed the cavernous internal carotid artery, and extended posteriorly into the ambient cistern adjacent to the pons and anteriorly into the right optic canal (Fig 1A). A second area of abnormal signal also was present in the right internal auditory canal (Fig 1B). Both lesions were isointense to brain parenchyma on proton-density images and decreased signal intensity on T2-weighted images. T1-weighted images with contrast showed homogenous enhancement. A small amount of fluid also was noted in the sphenoid sinus. Outside MR examinations from 10 days and 5 weeks earlier were subsequently obtained and demonstrated that the cavernous sinus mass had rapidly increased in size. The patient became unresponsive despite penicillin and ceftriaxone therapy and subsequently died. An autopsy revealed acute purulent meningitis. There was enlargement of the right cavernous sinus without evidence of tumor. The epithelium of the sphenoid sinus was intact; however, sulfur granules indicative of actinomycosis were found on gram stain of the sphenoid bone.

CNS manifestations of actinomycosis are brain abscess (67%), meningitis or meningoencephalitis (13%), actinomycoma (7%), subdural empyema (6%), and epidural abscess (6%) (1). Most patients afflicted with CNS actinomycosis are immunocompetent, and men are affected approximately three times as often as women. Diagnosis is difficult because of the relative nonspecificity of signs and symptoms and the bacterium's fastidious growth requirements in culture. Although somewhat controversial, the bacteria are generally considered to gain access to the CNS by direct extension from the ear or sinuses or alternatively via the blood stream from a pulmonary, genitourinary, or cervicofacial source.

The radiographic findings of CNS actinomycosis are not well documented because most case reports predate the advent of CT scanning. In the English literature, CT findings in two case reports include that of a thick-walled, multiloculated, rim-enhancing abscess (2) and of an enhancing mass simulating a meningioma with adjacent cra-



A



B

Fig 1. A, Axial T1-weighted 400/16/1.5 (repetition time/echo time/excitations) spin-echo MR images before and after injection of contrast show an enhancing mass adjacent to the right cavernous sinus (arrow) extending into the right perimesencephalic cistern.

B, More-caudal images show an enhancing mass within the right internal auditory canal (arrow).

nia thickening and surrounding edema (3). The MR findings in a single case report are of an irregularly marginated, rim-enhancing, multilobulated abscess with a cystic component on T1-weighted images, accompanied by increased surrounding signal consistent with edema on T2-weighted images (4). In the case presented here, there was no cystic component to suggest the presence of an abscess or an infectious cause, and the MR findings of enhancement within the right cavernous sinus and internal auditory canal were initially thought to represent either metastatic tumor spread or multiple primary neoplasms. In cases with radiographic findings suggestive of an abscess, meningoencephalitis, or mass lesion, but atypical

symptoms, the diagnosis of actinomycosis should be considered.

Brian Funaki
Jordan D. Rosenblum
*Department of Radiology
The University of Chicago (Ill)*

2. Sharma BS, Bannerjee AK, Sobti MK. Actinomycotic brain abscess. *Clin Neurol Neurosurg* 1990;92:373-376
3. Khosla VK, Banerjee AK, Chopra JS. Intracranial actinomycoma with osteomyelitis simulating a meningioma. *J Neurosurg* 1984;60:204-207
4. Krishna L, Slizofski WJ, Katsetos CD, et al. Abnormal intracerebral thallium localization in a bacterial brain abscess. *J Nucl Med* 1992;33:2017-2019

References

1. Smego RA. Actinomycosis of the central nervous system. *Rev Infect Dis* 1987;9:855-865