

The **next generation** GBCA  
from Guerbet is here

Explore new possibilities >

Guerbet | 

© Guerbet 2024 GUOB220151-A

# AJNR

## **Subcutaneous catheter calcification in ventriculoperitoneal shunts.**

M W Stannard and N K Rollins

*AJNR Am J Neuroradiol* 1995, 16 (6) 1276-1278

<http://www.ajnr.org/content/16/6/1276>

This information is current as  
of March 13, 2024.

---

# Subcutaneous Catheter Calcification in Ventriculoperitoneal Shunts

Michael W. Stannard and Nancy K. Rollins

**Summary:** In three male patients with long-standing Silastic ventriculoperitoneal shunts, a sleeve of dystrophic calcification surrounding the catheter at the thoracic inlet developed, visible on plain radiographs. Such calcification indicates degeneration and tethering of the shunt catheter. It was associated with shunt disconnection in two patients.

**Index terms:** Shunts, complications; Shunts, ventriculoperitoneal; Catheters and catheterization, in infants and children

Of the complications of Silastic (Dow Corning, Midland, Mass) ventriculoperitoneal shunts, radiographically visible calcification of the surrounding subcutaneous soft tissues has been one of the least reported. We have found one report of calcification about a Silastic catheter that was detectable on plain radiographs (1). We present three male patients in whom calcification about the cervicothoracic section of the shunt catheter occurred. Two were associated with disconnection of the catheter in the upper neck.

## Case Reports

### Case 1

An 11-year-old white boy presented with headache, vomiting, and left neck pain. He had received a ventriculoperitoneal shunt for hydrocephalus with one shunt revision for infection in the first year of life. A shunt series at 5 years showed an intact shunt with no calcification. At present admission, x-ray films showed a 7-cm length of calcification surrounding the shunt catheter as it crossed the left clavicle (Fig 1) and disconnection of the catheter at the level of C-4. The shunt was found to be obstructed distally. At surgery the subcutaneous shunt catheter was encrusted with calcified deposits and surrounded with dense fibrosis such that it could not be moved. It was therefore left in place, and a new piece of tubing was tunneled from the shunt valve to the abdomen along a separate path. The new shunt functioned well.

### Case 2

A 17-year-old white boy with lumbosacral spina bifida received a ventriculoperitoneal shunt at 1 month of life and had no subsequent problems with the shunt. He presented with urinary tract infections associated with his neurogenic bladder and cellulitis of a foot complicating his paraparesis. He had no symptoms of shunt dysfunction.

A chest x-ray film showed heavy calcification surrounding 12 cm of the shunt catheter in the lower right neck and upper chest (Fig 2). A shunt series showed disconnection of the shunt catheter at the level of the mastoid process. The distal tip lay in the anterior abdominal wall at the epigastrium.

### Case 3

An 8-year-old black boy presented with headache and vomiting. He had received a Hakim ventriculoperitoneal shunt at 3 months of age for communicating hydrocephalus. At age 7 he presented with shunt malfunction, and the ventricular end of the shunt was revised. The peritoneal catheter was functioning normally and was left in situ. Radiographs of the catheter showed no calcification.

At his latest admission the shunt was functioning normally, and repeat computed tomography of the head showed no ventricular dilatation. Radiographs revealed a 3-cm length of calcification about the shunt catheter as it crossed the left clavicle (Fig 3). There was no disconnection of the shunt.

## Discussion

After the introduction of Silastic ventricular shunt tubing in 1957 (2), it has proved to be a stable material producing minimal soft-tissue reaction (3). Longer-term experience has shown, however, that implanted Silastic tubing is not always totally inert. Light microscopy of excised sleeves, which had formed about the shunt tubing in two patients (4), showed a fibrous reaction made up of hyalinized connective tissue composed of flattened collagen fibers with occasional fibrocytes. In one patient with

---

Received February 9, 1994; accepted after revision April 26.

From the Department of Radiology, Children's Medical Center and the University of Texas Southwestern Medical Center at Dallas.

Address reprint requests to Michael W. Stannard, MD, Department of Radiology, Children's Medical Center, 1935 Motor St, Dallas, TX 75235.

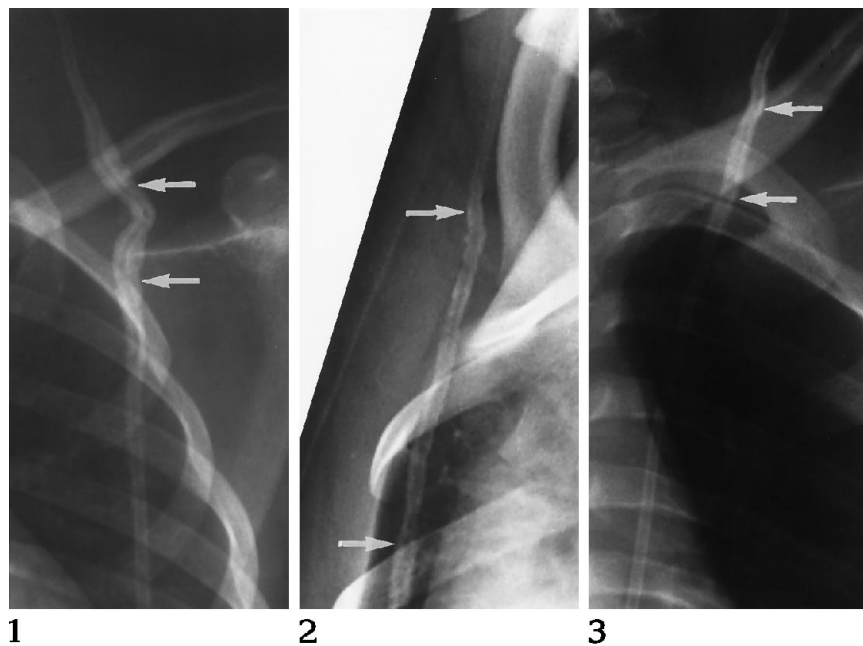


Fig 1. Case 1, 11-year-old white boy with a 7-cm calcified sleeve about the shunt catheter (arrows). There was shunt dysfunction, and the shunt was replaced.

Fig 2. Case 2, 17-year-old white boy with a 12-cm sleeve of calcification (arrows). There was no shunt dysfunction.

Fig 3. Case 3, 8-year-old black boy with a 3-cm sleeve of calcification (arrows). There was no shunt dysfunction.

shunt disconnection, this fibrous sleeve seemed to have conducted cerebrospinal fluid to the abdomen. A similar sleeve may have accounted for the absence of shunt malfunction in our case 2. Examination of removed noninfected shunt catheters with the scanning electron microscope (5, 6) showed the surface of the tube to be covered with organic material attached to the catheter by fibrinlike filaments. The tubing itself had lost its original homogenous structure, and the outer layers had become spongy and friable, associated with irregular holes and fissures at the inner surface. The three ventriculoperitoneal catheters reported by Griebel et al (6) had fractured spontaneously before removal. Some shunt catheters were surrounded by white mineral deposits visible to the naked eye, associated with deterioration of the catheter wall and tethering of the catheter by adherent surrounding soft tissues. Spectral analysis (6) and energy-dispersive analysis using x-rays (7) showed the surface deposits to be calcium phosphate. Some shunt catheters may be defective before they are implanted. Guevara et al (5) studied sections of unused shunt tubing with the scanning electron microscope and noted occasional irregular holes and defects in the outer surface, suggesting imperfect quality control during manufacture.

In the case report of calcium deposition about shunt tubing visible on plain radiographs by Shimotake et al (1), the site of calcification, at

the level of the clavicle, was similar to our three cases.

Various factors have been adduced to account for calcium deposition about shunt tubing. Variations in the quantity of silica and vulcanizing agent added to medical-grade silicone rubber may provoke a soft-tissue reaction. Static electrical charges on the tubing may hold dust and lint. Benzalkonium chloride may be absorbed into the silicone rubber and may re-enter the body after implantation. Detergents and dissolved ethylene oxide gas may excite soft-tissue fibrosis (4). In addition, polymers are known to undergo biodegradation as a result of hydration, splitting of covalent bonds, and dissolution and digestion by macrophages (8). In a review of microscopic findings in 25 removed shunts (7), the most extensive mineralization of shunt tubing occurred near the nuchal line as the shunt catheter ran from the subgaleal layer to the subcutaneous layer, a site of mild constrictive stress subject to repeated tensile strain. The same study showed a marked loss of tensile strength in implanted tubing. The most important factors in the microcalcification of the shunt catheters were the youth of the patient at original implantation and the length of time the tubing was in the patient. In none of the patients in this series was the tubing disconnected.

The three patients who form the subject of this report received their shunts in the first 2 years of life and presented not less than 7 years

later for reasons, in two, not directly related to the shunts. None had any known disorder of calcium metabolism.

The distribution of radiographically visible calcification from the midcervical region to the upper chest is strikingly similar to the patient of Shimotake et al (1), in whom the catheter had been in place for 8 years. We speculate that the tensile stresses on the tubing as it passes from the mobile neck to the relatively immobile chest wall may have been responsible for stress-related degeneration in the cervicothoracic section of the tubing. In view of the tethering of the tubing associated with calcification, it is at least plausible that the disconnection of the tubing in the upper neck about the calcified segment seen in cases 1 and 2 may have been the result of tension on the tube during movement of the head.

Although microscopic calcification of the tissues surrounding Silastic shunt tubes seems to be common, calcification heavy enough to be apparent on plain radiographs is rare. Such calcification seems to indicate degeneration and tethering of the shunt catheter and should prompt a search for disconnection.

## Acknowledgment

We acknowledge with thanks the assistance of Guido Currarino, MD, who drew our attention to cases 2 and 3.

## References

1. Shimotake K, Kondo A, Aoyama I, Nin K, Tashiro Y, Nishioka T. Calcification of a ventriculoperitoneal shunt tube: case report. *Surg Neurol* 1988;30:156-158
2. Pudenz RH, Russell FE, Hurd AH, Shelden CH. Ventriculoauriculostomy: a technique for shunting cerebrospinal fluid into the right auricle: preliminary report. *J Neurosurg* 1957;14:171-179
3. Irving IM, Castilla P, Hall EG, Rickham PP. Tissue reaction to pure and impregnated silastic. *J Pediatr Surg* 1971;6:724-729
4. Sugar O, Bailey OT. Subcutaneous reaction to silicone in ventriculoperitoneal shunts: long term results. *J Neurosurg* 1974;41:367-371
5. Guevara JA, La Torre J, Denoya C, Zuccaro G. Microscopic studies in shunts for hydrocephalus. *Childs Brain* 1981;8:284-293
6. Griebel RW, Hoffman HJ, Becker L. Calcium deposits on CSF shunts: clinical observations and ultrastructural analysis. *Childs Nerv Syst* 1987;3:180-182
7. Echizenya K, Satoh M, Mural H, Ueno H, Abe H, Komai T. Mineralization and biodegradation of CSF shunting systems. *J Neurosurg* 1987;67:584-591
8. Kronenthal RL. Biodegradable polymers in medicine and surgery. In: Kronenthal RL, Oser Z, Martin E, eds. *Polymers in Medicine and Surgery*. New York: Plenum Press, 1975:119-137