

Are your **MRI contrast agents** cost-effective?

Learn more about generic **Gadolinium-Based Contrast Agents**.



FRESENIUS  
KABI

caring for life

**AJNR**

**Postoperative imaging of the multichannel cochlear implant.**

B A Shpizner, R A Holliday, J T Roland, N L Cohen, S B Waltzman and W H Shapiro

*AJNR Am J Neuroradiol* 1995, 16 (7) 1517-1524

<http://www.ajnr.org/content/16/7/1517>

This information is current as of April 19, 2024.

# Postoperative Imaging of the Multichannel Cochlear Implant

Barry A. Shpizner, Roy A. Holliday, J. Thomas Roland, Noel L. Cohen, Susan B. Waltzman, and William H. Shapiro

**PURPOSE:** To present the postoperative radiographic appearance of the multichannel cochlear implant and to suggest criteria for the radiographic evaluation of postimplant patients. **METHODS:** One hundred forty-one patients, 73 female and 68 male, had multichannel cochlear implants inserted. One hundred thirty-five intraoperative radiographs, 31 postoperative radiographic examinations, and 10 postoperative CT examinations were retrospectively reviewed. **RESULTS:** In 135 patients, a Stenver's or anteroposterior projection confirmed the normal placement of the implant by demonstrating the electrodes to be regularly spaced and gently curved within the first turn of the cochlea. The insertion depth was determined by counting the number of electrodes that projected medial to the cochlear promontory. In 5 patients in whom intracochlear placement of the electrode array could not be confirmed on plain radiographs, CT demonstrated the location of the electrode array. In 3 patients with postoperative infections, CT either correctly identified or excluded the presence of a collection beneath the implant. **CONCLUSION:** Plain radiographs of the temporal bone are sufficient for the postoperative treatment of the majority of postimplant patients. CT should be performed when plain radiographs cannot adequately show the location of the electrode array or if postoperative infection is suspected.

**Index terms:** Ear, prostheses; Temporal bone, radiography; Computed tomography, indications

*AJNR Am J Neuroradiol* 16:1517-1524, August 1995

The multichannel cochlear implant significantly improves speech recognition in severely to profoundly deaf patients who derive little benefit from hearing aids (1). The multichannel cochlear implant prosthesis consists of both externally worn and surgically implanted components (Figs 1 and 2). The externally worn components include the headset and the speech processor. The implanted components include the receiver/stimulator and the electrode array. The receiver/stimulator is placed beneath the postauricular soft tissues within a well drilled out of the calvarium. The electrode array is inserted into the scala tympani through a cochleostomy,

which is drilled into the cochlear promontory approximately 1 mm anterior to the round window.

The preoperative radiographic assessment of patients undergoing cochlear implantation has been the focus of the majority of previous reports in the radiologic and otolaryngologic literature (2-6). The postoperative radiographic assessment of patients after multichannel cochlear implantation has been described in the otolaryngologic literature (5, 7-9). The purposes of this study are to present the postoperative radiographic appearance of the normal and abnormally functioning multichannel cochlear implant and to suggest criteria for the radiographic evaluation of patients after implant insertion.

---

Received February 24, 1994; accepted after revision February 3, 1995.  
Presented at the 31st Annual Meeting of the American Society of Head and Neck Radiology, 1993.

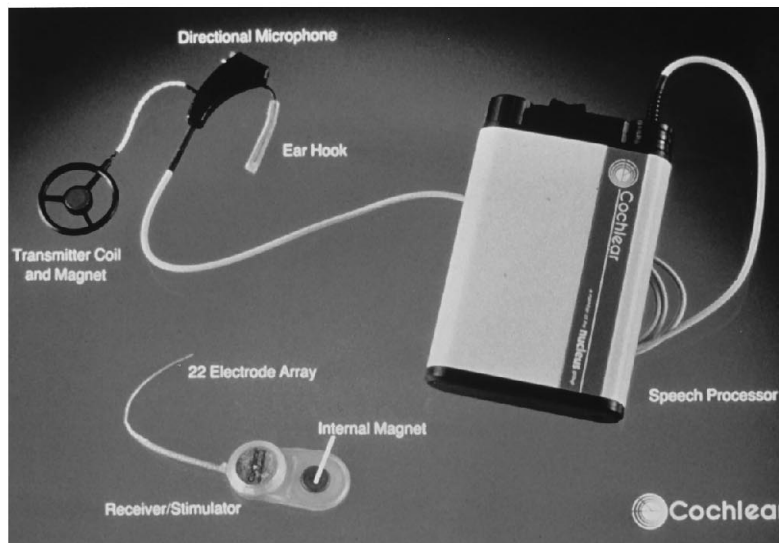
From the Departments of Radiology (B.A.S., R.A.H.) and Otolaryngology (J.T.R., N.L.C., S.B.W., W.H.S.), New York (NY) University Medical Center.

Address reprint requests to Barry A. Shpizner, MD, Department of Radiology, New York University Medical Center, 560 First Ave, New York, NY 10016.

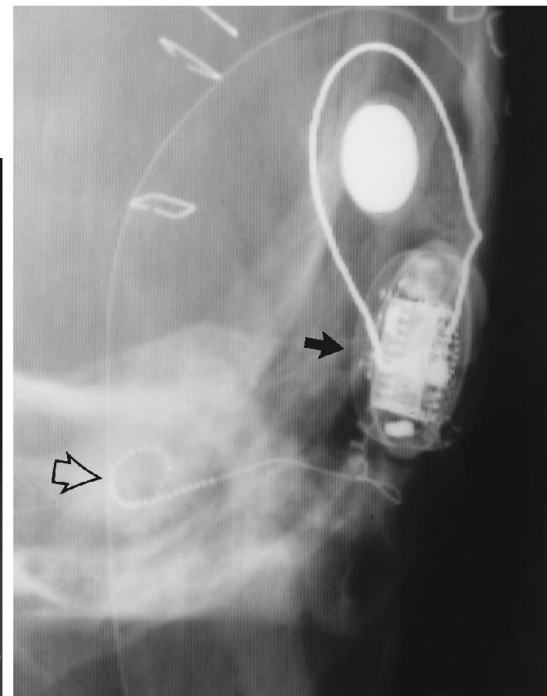
*AJNR* 16:1517-1524, Aug 1995 0195-6108/95/1607-1517  
© American Society of Neuroradiology

## Materials and Methods

The clinical histories and radiographic studies of 141 patients with Nucleus multichannel cochlear prostheses (Cochlear Corporation, Englewood, Colo) were retrospectively reviewed. Psychophysical data, which reflect the patient's perceptual response to graded electrical stimulation of specific electrodes, were also reviewed. Sixty-eight patients were male; 73 patients were female. The patients



1



2

Fig 1. Components of the multichannel cochlear implant. The externally worn components, including the headset and speech processor, are pictured above. The implanted components, including the receiver/stimulator and electrode array, are pictured below. The headset, which is worn behind the ear, contains a microphone and a transmitter coil, which is magnetically coupled to the receiver/stimulator.

Fig 2. Intraoperative transorbital anteroposterior view demonstrates all implanted components of the multichannel cochlear implant. The *closed arrow* indicates the receiver/stimulator; the *open arrow*, the electrode array.

ranged in age from 1 year to 85 years with a mean age of 25.8 years. Intraoperative Stenver's or transorbital anteroposterior views of the temporal bones were obtained in 135 patients. Postoperative Stenver's, transorbital anteroposterior, and supplemental base views were obtained in 31 patients.

The depth of insertion of the electrode array (number of electrodes and stiffening rods within the cochlea) was estimated surgically in each patient by counting the number of elements that passed through the cochleostomy. The depth of insertion was estimated radiographically by counting the number of elements relative to the cochlear promontory (Fig 3). Electrodes that projected medial to the lateral margin of the cochlear promontory were considered intracochlear. The cochlear promontory, which is identified as the air-bone interface just caudal to the vestibule (10), was confidently identified on 128 intraoperative studies and on 30 postoperative studies. Failure to identify the cochlear promontory on 7 intraoperative films was attributable to patient rotation toward either the lateral or craniad projection. The cochlear promontory could not be identified on postoperative films in one patient with vestibulocochlear dysplasia because of failure to identify otic capsule landmarks (see Fig 8A).

To demonstrate that the cochlear promontory was an accurate landmark on which to base estimates of electrode

array insertion, cochleostomy was performed on an isolated cadaveric temporal bone preparation and a cadaveric head. Stenver's views were obtained after electrode array insertion both before and after a dense barium solution was painted on the cochleostomy site. The barium projected over the air-bone interface of the cochlear promontory in both cadavers (Fig 4). The number of electrodes that projected over or medial to the cochlear promontory appeared the same as the number that entered the cochlea.

Patients were categorized according to the depth of electrode array insertion. A full insertion, defined as an insertion of all 22 electrodes and fewer than 10 stiffening rods into the cochlea, was observed in 122 patients (Fig 3). A shallow insertion, defined as an insertion of fewer than 12 electrodes, was observed in 8 patients. An ultra-deep insertion, defined as insertion of all 22 electrodes and 10 stiffening rods where the arc subtended by the array within the cochlea measured 360° or more, was observed in 6 patients (Fig 5). A partial insertion, defined as an insertion of 12 to 21 electrodes, was observed in 5 patients.

Ten postoperative computed tomographic (CT) scans of the temporal bones were obtained in nine patients (Table). All scans were performed using 1.5- to 3.0-mm contiguous axial sections with supplemental 1.5- to

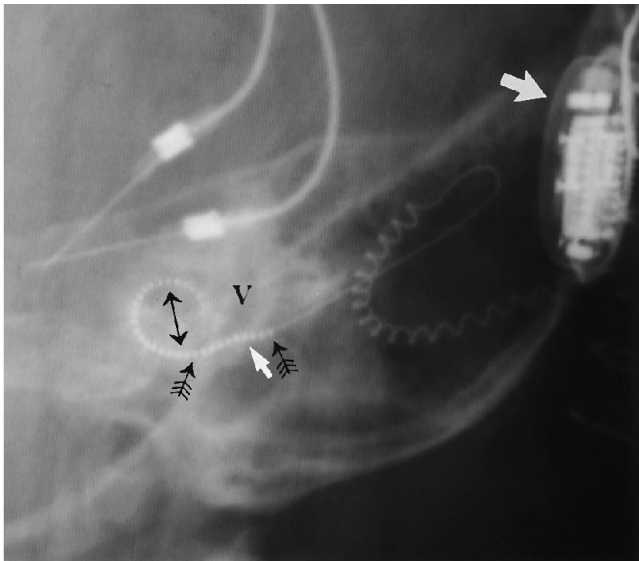


Fig 3. Intraoperative Stenver's view shows a normally inserted electrode array. Between the array of 22 active electrodes (*two-headed arrow*) and the receiver/stimulator (*large white arrow*) are 10 electrically inactive stiffening rods (*small black arrows*). The stiffening rods, which provide mechanical support during insertion, are radiographically identical in appearance to the electrodes. Note the gentle curve of the array within the first turn of the cochlea with regular spacing between the electrodes. The depth of insertion is estimated by counting the number of electrodes or stiffening rods relative to the cochlear promontory (*small white arrow*), which is the air-bone interface below the vestibule (*V*). In this example there are 3 stiffening rods lateral to the cochlear promontory, indicating an insertion of 22 electrodes and 7 stiffening rods. This is termed a *full insertion*, because all 22 active electrodes are intracochlear.

2.0-mm coronal sections obtained in eight patients. Seven CT scans were performed at our institution using a General Electric 9800 CT/T scanner (General Electric medical systems, Milwaukee, Wis). Three CT scans from other institutions using a similar scan technique were available for

review. Contrast-enhanced CT scans were performed on two patients using a standard bolus and drip technique.

## Results

Intraoperative radiographs demonstrated the implanted components of the cochlear prostheses in all patients. In 135 patients the integrity and proper positioning of the implant was confirmed radiographically. The normally inserted electrode array followed a gentle curve within the first turn of the cochlea with regular spacing between the electrodes (Fig 3).

In the 135 patients with normal-appearing electrode arrays, there was a discrepancy of two electrodes or less between the radiographic estimate and the surgical estimate of the depth of insertion. A similar correlation was found between the number of inserted electrodes estimated radiographically and the number of functioning electrodes as shown by psychophysical testing. In our experience, standardization of views did not make a significant difference regarding the radiographic estimate of electrode insertion. Correlation with surgical and psychophysiologic data demonstrated an error of plus or minus two electrodes regardless of whether anteroposterior or Stenver's views were used.

Postoperative radiographs were obtained when intraoperative radiographs failed to confirm normal placement of the electrode array, if electrode array extrusion was suspected on the basis of psychophysical testing, or if unusual nonauditory responses such as vibratory or tactile sensations were experienced by the patient. In addition, postoperative radiographs were ob-

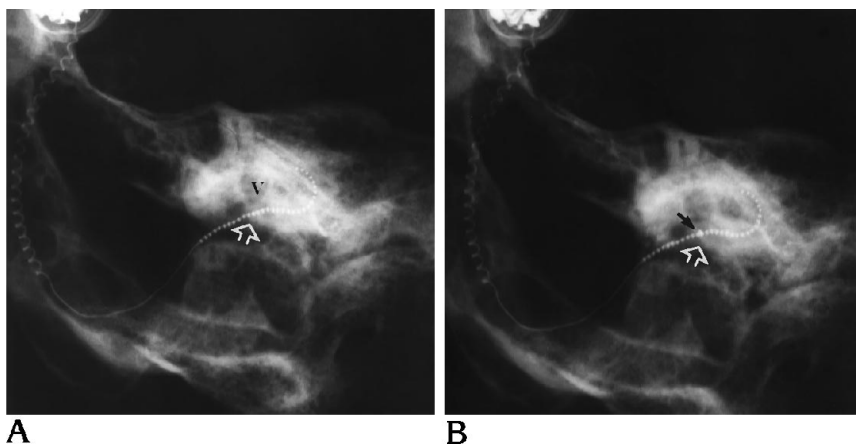


Fig 4. *A*, Stenver's view of a cadaveric temporal bone preparation after electrode array insertion. Ten stiffening rods project lateral to the cochlear promontory (*open white arrow*), and 22 electrodes project medial to it, indicating an insertion of 22 electrodes. Twenty-two electrodes were directly seen to enter the cochlea. *V* indicates vestibule.

*B*, Stenver's view of cadaveric preparation after electrode array insertion after the inner lip of the cochleostomy was painted with a dense barium solution (*black arrow*). The dense barium overlies the air-bone interface of the cochlear promontory (*open white arrow*). Twenty-one electrodes were seen to enter the cochlea, which corresponds to the number of electrodes projecting over or medial to the cochlear promontory.

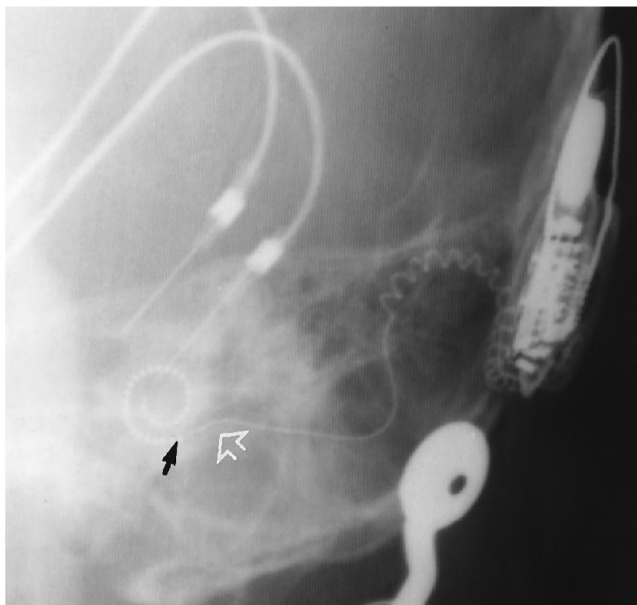


Fig 5. Intraoperative Stenver's view shows the last stiffening rod (*black arrow*) medial to the cochlear promontory (*open white arrow*), indicating that all 22 electrodes and 10 stiffening rods are inserted. The arc subtended by the array within the cochlea measures greater than 360°. This is termed an *ultradeep insertion*.

tained before CT was performed for other indications listed in the Table.

Intracochlear placement of the electrode array could not be confirmed on postoperative temporal bone radiographs alone in six pa-

tients. Five of these patients subsequently had CT scans for electrode array location. A CT scan was not obtained on the sixth patient, who was treated at another facility. In all patients the electrode array was bent or compressed or had an atypical configuration (Figs 6A and 7A). In one patient the exact location of the array could not be determined, in part, because of the absence of well-defined otic capsule structures (Fig 8A).

Temporal bone radiographs were used to confirm the diagnosis of electrode array extrusion in one patient. Ten months after implantation, the patient noticed a decrease in speech discrimination ability. Two months later, he had a sharp pain in the region of the ipsilateral eustachian tube. Psychophysical testing revealed a loss of sound perception and a reproduction of the painful response when the first four basal electrodes were stimulated. Temporal bone radiographs demonstrated 17 electrodes within the cochlea compared with an intraoperative film that showed a full insertion of 22 electrodes and three stiffening rods, confirming electrode array extrusion.

Postoperative radiographs were obtained in 12 patients who had nonauditory vibratory or tactile sensations. Eight of these patients were prelingually deaf, and 7 had symptoms refer-

#### Indications for postimplant temporal bone CT

Patient	Sex/Age, y	Indication	Result	Surgical Findings
C.S.	M/36	Radiographs do not confirm intracochlear insertion	Compressed intracochlear electrode array	...
L.E.	M/18	Radiographs do not confirm intracochlear insertion	Compressed intracochlear electrode array	...
D.S.	M/37	Radiographs do not confirm intracochlear insertion	Bent intracochlear electrode array	...
K.A.	F/5	Radiographs do not confirm intracochlear insertion	Array in hypotympanum, vestibulocochlear dysplasia	...
		After drill out: radiographs do not confirm intracochlear insertion	Tip of array in temporal bone adjacent to carotid canal	...
R.W.	F/61	Facial twitch	Intracochlear insertion, otospongiosis	...
R.C.	F/4	Severe nocturnal headache	Normal intracochlear insertion	...
C.J.	F/55	Suspected infection	Collection beneath receiver/stimulator	Sterile seroma with extrusion of receiver/stimulator
C.S.	F/34	Suspected infection	Collection beneath receiver/stimulator	Abscess beneath receiver/stimulator
T.S.	F/2	Suspected infection	No collection	Necrosis of surgical flap, no abscess

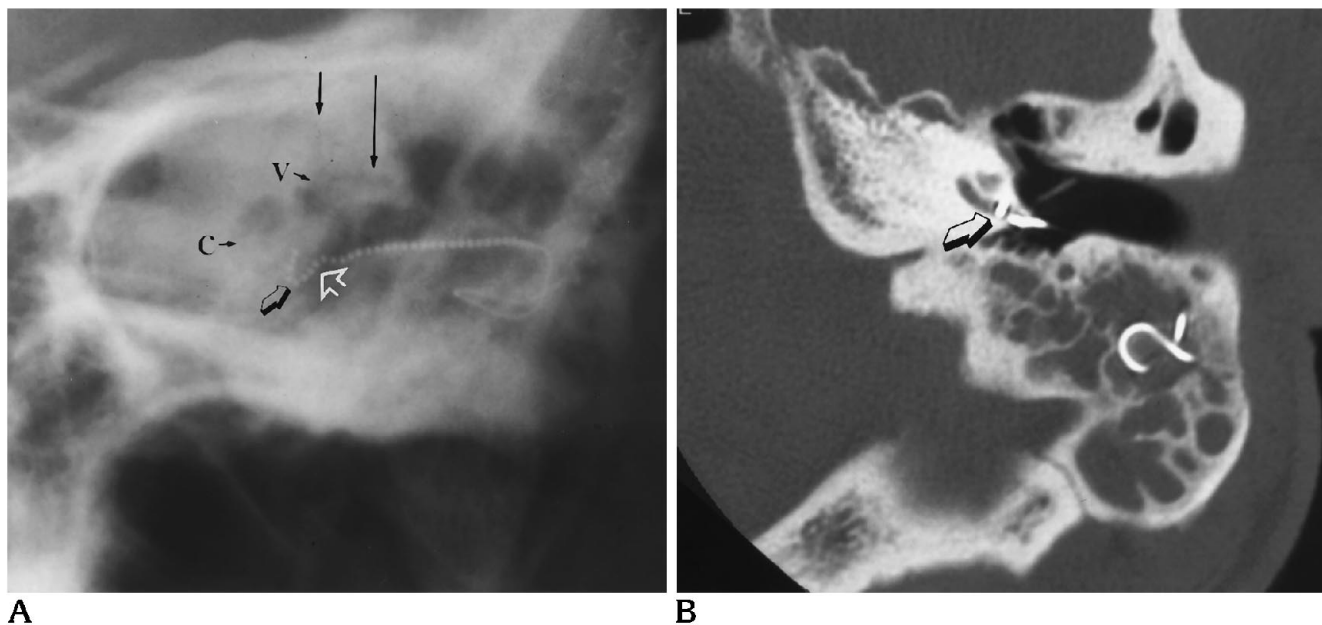


Fig 6. A, Postoperative anteroposterior view demonstrates an abnormally bent electrode array (*open black arrow*). Identification of the vestibule (V) is facilitated by its relationship with the superior semicircular canal (*short black arrow*) and the lateral semicircular canal (*long black arrow*). Eight electrodes lie medial to the cochlear promontory (*open white arrow*), yet the electrode array seems to be separate from the cochlea (C). Intracochlear insertion cannot be confirmed.

B, Axial CT scan of this patient clearly demonstrates the array entering the first turn of the cochlea. The tip of the array has reflected off the posterior wall of the cochlea, and the resultant right-angle bend of the array (*arrow*) prevented further insertion along the basilar turn.

able to the implantation site. Four patients experienced tactile sensations in distant locations such as the shoulder and abdomen; 1 patient experienced a metallic taste during stimulation. Plain radiographs confirmed normally positioned cochlear implants in all of these patients.

CT scans of the temporal bone were obtained for the indications summarized in the Table. CT scans demonstrated the location of the electrode array in relation to the otic capsule structures in all cases. The exact number of inserted electrodes could not be determined by CT be-

cause of metallic artifact from the electrodes themselves (Fig 9).

Five CT scans were performed for location of the electrode array when postoperative radiographs could not confirm an intracochlear insertion. Three CT scans confirmed an intracochlear insertion of the electrode array (Figs 6B and 7B). The degree of intracochlear insertion was determined with CT data in conjunction with plain radiographs and psychophysical data. One CT scan demonstrated the electrode array to be extracochlear in a patient with se-

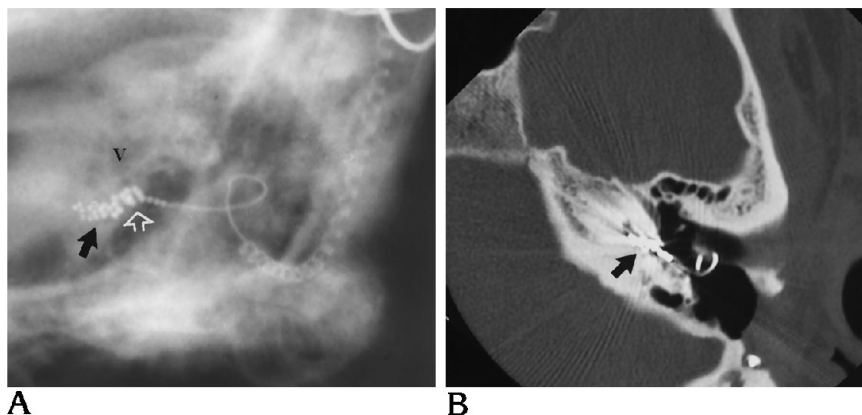
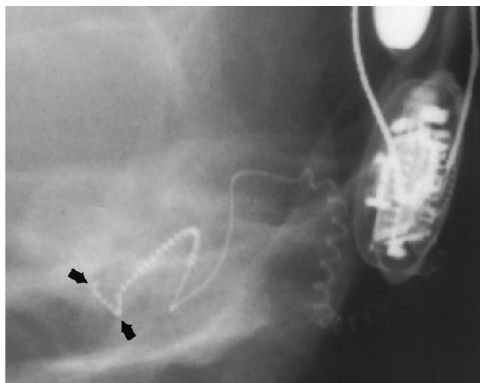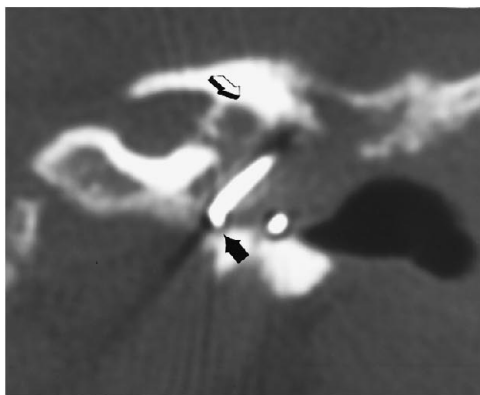


Fig 7. A, Postoperative Stenver's view demonstrates a compressed array of irregularly spaced electrodes, which are folded on themselves (*black arrow*). The abnormal-appearing array lies medial and immediately inferior to the vestibule (V). Twenty-two electrodes and seven stiffening rods lie medial to the cochlear promontory (*open white arrow*), suggesting intracochlear insertion. The cochlea cannot be identified.

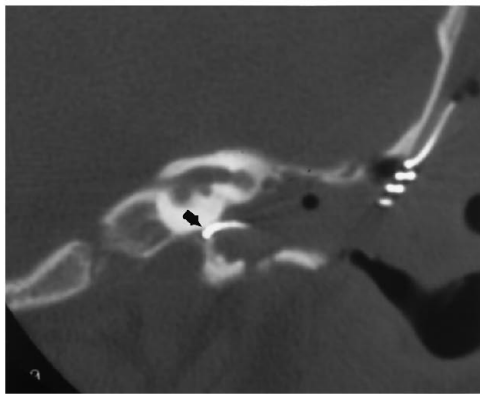
B, Axial CT scan demonstrates intracochlear placement of the electrode array (*arrow*) in this patient with labyrinthitis ossificans. Compression of the array is not demonstrated convincingly because of metallic artifact from the electrodes.



A



B



C

Fig 8. A, Postoperative anteroposterior view demonstrates an abnormal curvature to the electrode array (*arrows*). The absence of well-defined otic capsule structures precludes identification of the cochlear promontory. Extracochlear placement is suspected.

B, Coronal CT scan of this patient shows the array coiled within the hypotympanum (*solid arrow*). Note the deformity of the otic capsule structures (*open arrow*) in this patient with severe vestibulocochlear dysplasia. Abnormal soft tissue within the tympanic cavity also contributed to the decreased conspicuity of the cochlear promontory on plain radiographs.

C, After a drill out procedure, coronal CT demonstrates the tip of the electrode array embedded within the otic capsule adjacent to the carotid canal (*arrow*). Note again the deformity of the otic capsule structures.

vere vestibulocochlear dysplasia (Fig 8B). The CT was used to plan a drill out of the otic capsule into which the electrode array was inserted, resulting in a functional implant. After the drill out, plain radiographs could not locate the electrode array, but CT demonstrated a very shallow insertion into the otic capsule adjacent to the carotid canal (Fig 8C).

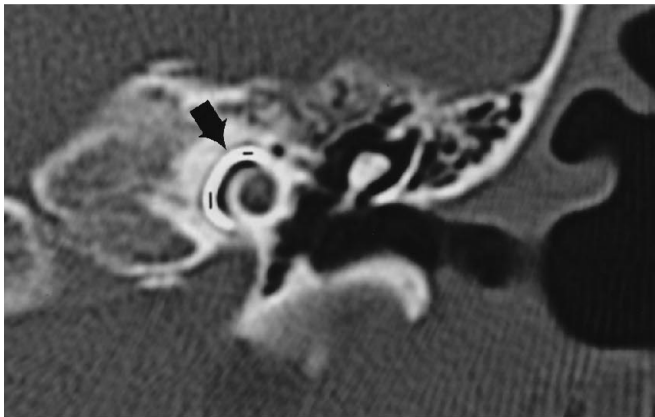
One patient experienced a facial twitch when certain apical electrodes were stimulated. A CT scan demonstrated a normal intracochlear insertion but showed severe otospongiosis (Fig 10). Absence of the normal bone insulation provided by the facial nerve canal most likely accounted for the aberrant facial nerve stimulation. The offending electrodes were programmed out, eliminating the unwanted motor response.

CT scans were performed to evaluate possible postoperative infections in three patients. Abnormal soft tissue beneath the receiver/stimulator with elevation and rotation of the implant was found in two patients (Fig 11). Radiographic characterization of the abnormal soft tissue was precluded by metallic artifact. One patient had an abscess, which was surgically drained, and the second patient had a sterile seroma, which resulted in extrusion of the receiver/stimulator through the surgical flap. The patient without demonstrable abnormal soft tissue had an area of necrosis of the overlying surgical flap from a chronic low-grade infection without a frank abscess.

## Discussion

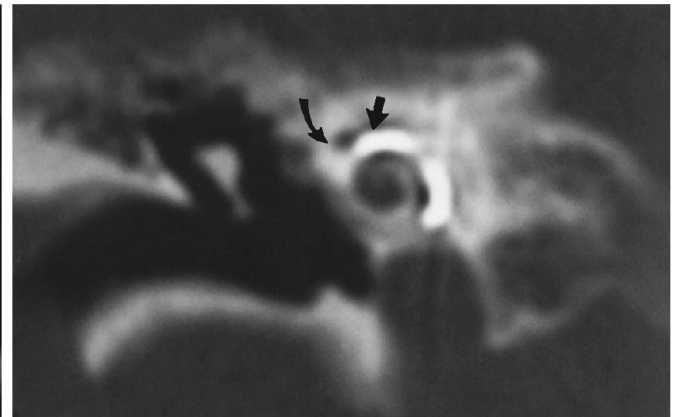
The multichannel cochlear implant provides direct electrical stimulation to the malfunctioning cochlea in an attempt to bypass the cochlear abnormality in profoundly deaf patients. The externally worn components of the multichannel cochlear implant (microphone, speech processor, and transmitter coil) transform sound into an encoded signal, which is sent across the skin to the implanted components (receiver/stimulator and electrode array), which directly stimulate the cochlea.

The ear-level microphone converts sound into an acoustic signal, which is filtered by the speech processor to extract the information necessary for speech recognition. The speech processor uses a computer to encode the signal digitally in a form suitable for the receiver/stimulator. The computer is programmed during



9

Fig 9. Coronal CT scan demonstrates the electrode array within the first turn of the cochlea (*arrow*). Note that the precise number of inserted electrodes cannot be determined.



10

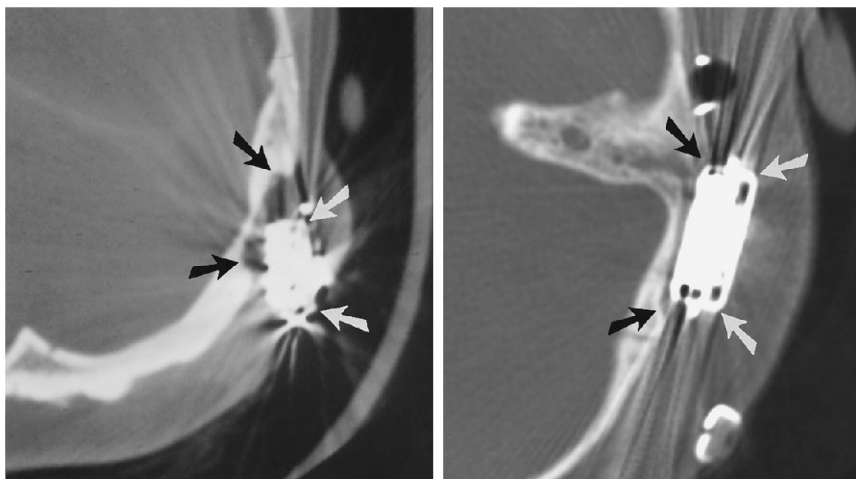
Fig 10. Coronal CT confirms a normal insertion in this patient with severe otospongiosis. Note the close proximity between the array (*straight arrow*) and the labyrinthine segment of the facial nerve (*curved arrow*).

psychophysical testing to optimize the performance of each patient. The transmitter coil is magnetically coupled to the receiver/stimulator and sends the encoded signal across the skin. The receiver/stimulator decodes the signal and activates the appropriate electrode pair implanted within the scala tympani. The close proximity of the electrode array to the basilar membrane permits direct stimulation of the residual hair cells within the organ of Corti (11). By providing selective stimulation of specific regions within the cochlea, the multichannel implant exploits the tonotopic organization of the cochlea to improve speech recognition (12).

The radiographic evaluation of patients after insertion of the multichannel cochlear implant plays an important role in postoperative treat-

ment. Intraoperative radiographs of the temporal bone demonstrate the integrity, positioning, and depth of insertion of the implant in most patients. In addition, these radiographs provide a baseline for future studies in the event that implant extrusion is suspected.

Temporal bone radiographs are superior to CT scans for estimating the number of inserted electrodes, because metallic artifact on the CT images renders individual electrodes indistinguishable. The technique described by Marsh et al (9) for estimating electrode array insertion depth on postoperative radiographs involved quantifying electrodes relative to a line drawn parallel to the overlapping limbs of the superior semicircular canal. This required the use of standardized views with strict attention to pa-



A

B

Fig 11. A, Axial CT of a patient with recurrent infections of the surgical bed with fistulization demonstrates elevation and rotation of the receiver/stimulator (*white arrows*) out of the calvarial well (*black arrows*). Note the extensive metallic artifact produced by the receiver/stimulator. An abscess beneath the receiver/stimulator was drained surgically, and the implant was removed.

B, Axial CT of a normally seated receiver/stimulator, for comparison, shows the implant (*white arrows*) flush against the calvarial well (*black arrows*).



tient positioning. At our institution, intraoperative films were obtained routinely (5). Our technique was developed to provide an accurate method of estimating insertion depth under conditions in which strict control over patient positioning was not possible. This technique was found to be reliable in a large proportion of cases (127 of 135 patients).

Estimates of the depth of electrode array insertion may have prognostic implications with regard to predicting auditory performance. There is the possibility of a direct correlation between insertion depth and auditory performance, because a wider range of frequencies can be stimulated when more electrodes are intracochlear. Preliminary results by Marsh et al (9) show a close correlation between auditory performance in postlingually deaf patients who have received implants and radiographic estimates of insertion depth.

Plain radiographs of the temporal bone are least reliable in determining the location of the electrode array when the array is compressed or bent or has an atypical curvature. A CT scan of the temporal bone definitively demonstrates the intracochlear or extracochlear location of the electrode array in these instances. Postoperative radiographs are useful in evaluating patients with nonauditory vibratory or tactile responses. Plain radiographs can confirm that the electrode array has not migrated and is in the normal position, eliminating the need for sectional imaging.

In patients with suspected postoperative infection, CT is the study of choice for detecting collections beneath the receiver/stimulator even though the images are obscured by metallic artifact. Excessive separation of the implant from the calvarial well, evident on wide window settings, is an accurate indication of the presence of underlying fluid. Although separation of the receiver/stimulator from the calvarium may be demonstrated on plain radiographs, this requires a tangential view necessitating careful patient positioning. CT consistently demonstrates the position of the receiver/stimulator relative to the calvarial well and would be more

likely to define a contiguous spread of infection beyond the well.

Plain radiographs of the temporal bone are sufficient for the postoperative treatment of the majority of patients after multichannel cochlear implant insertion. Postoperative radiographs are recommended when intraoperative radiographs cannot confirm normal electrode array placement, when electrode array extrusion is suspected, and in the evaluation of nonauditory responses. CT scans should be performed when postoperative radiographs fail to demonstrate the location of the electrode array adequately or if postoperative infection is suspected.

## References

1. Clark AO. The University of Melbourne/Cochlear Corporation (Nucleus) Program. *Otolaryngol Clin North Am* 1986;19:329-354
2. Mueller DP, Dolan KD, Gantz BJ. Temporal bone computed tomography in the preoperative evaluation for cochlear implantation. *Ann Otol Rhinol Laryngol* 1989;98:346-349
3. Harnsberger HR, Dart DJ, Parkin JL, Smoker WRK, Osborn AG. Cochlear implant candidates: assessment with CT and MR imaging. *Radiology* 1987;164:53-57
4. Jackler RK, Luxford WM, Schindler RA, McKerrow WS. Cochlear patency problems in cochlear implantation. *Laryngoscope* 1987;97:801-805
5. Rosenberg RA, Cohen N, Reede DL. Radiographic imaging for the cochlear implant. *Ann Otol Rhinol Laryngol* 1987;96:300-304
6. Balkany TJ, Dreisbach JN, Seibert CE. Radiographic imaging of the cochlear implant candidate: preliminary results. *Otolaryngol Head Neck Surg* 1986;95:592-597
7. Ball JB, Miller GW, Hepfner ST. Computed tomography of single channel cochlear implants. *AJNR Am J Neuroradiol* 1986;7:41-47
8. Gray RF, Evans RA, Freer CEL, Szutowicz HE, Maskell GF. Radiology for cochlear implants. *J Laryngol Otol* 1991;105:85-88
9. Marsh MA, Xu J, Blamey PJ, et al. Radiologic evaluation of multichannel intracochlear implant insertion depth. *Am J Otol* 1993;14:386-391
10. Compere WE, Valvassori GE. *Radiographic Atlas of the Temporal Bone*. Book II. St Paul, Minn: American Academy of Ophthalmology and Otolaryngology, 1964:10-11
11. Goycoolea MV, Muchow DC, Schirber CM, Goycoolea HG, Schellhas K. Anatomic perspective, approach and experience with multichannel intracochlear implantation. *Laryngoscope* 1990;100:1-18
12. Waltzman SB, Cohen NB, Fisher SG. An experimental comparison of cochlear implant systems. *Semin Hearing* 1992;13:195-207