

Are your MRI contrast agents cost-effective?

Learn more about generic Gadolinium-Based Contrast Agents.



**FRESENIUS
KABI**

caring for life

AJNR

Use of transcranial cerebral oximetry to monitor regional cerebral oxygen saturation during neuroendovascular procedures.

G Hernandez-Avila, M Dujovny, K V Slavin, M S Luer, E Nijensohn, G Geremia and J I Ausman

This information is current as of April 16, 2024.

AJNR Am J Neuroradiol 1995, 16 (8) 1618-1625
<http://www.ajnr.org/content/16/8/1618>

Use of Transcranial Cerebral Oximetry to Monitor Regional Cerebral Oxygen Saturation during Neuroendovascular Procedures

Gerardo Hernandez-Avila, Manuel Dujovny, Konstantin V. Slavin, Mark S. Luer, Eduardo Nijensohn, Glen Geremia, and James I. Ausman

Summary: Using transcranial cerebral oximetry, we monitored 30 patients who underwent cerebral angiography by the femoral route. Transcranial cerebral oximetry is a noninvasive technique of regional cerebral oxygen saturation measurement that uses near-infrared spectroscopy to differentiate oxyhemoglobin from reduced hemoglobin. Needle puncture, catheterization, and contrast media injection produced no significant peak changes in saturation from baseline. Acute and persistent decreases in oxygen saturation were associated with vascular complications and were detected before development of clinical symptoms. Greater changes in saturation were observed during several neuroendovascular procedures, indicating the development of complications, signaling a need to stop further endovascular manipulation.

Index terms: Brain, blood supply; Interventional neuroradiology; Oxygen

Neurologic complications of cerebral angiography are reported to occur in 1% to 14% of cases (1). These complications include permanent or transient neurologic deficits related to thrombus embolism, atheromatous debris, vasospasm, air embolism, arterial occlusion, and vessel rupture (1–3). Interventional neuroradiology procedures may lead to ischemic or hemorrhagic complications secondary to vessel manipulation or directly attributable to the material introduced during the procedure. Complication rates in interventional neuroradiology vary according to the procedure and the neuroradiologist's experience. Rates can be as high as 32% in very complicated interventions, such as balloon embolization of intracranial aneurysms (4, 5).

Techniques used to monitor for complications associated with cerebral angiography include electroencephalography, transcranial

Doppler ultrasound, continuous recording of the brain stem auditory responses, and motor and somatosensory evoked potentials (6–9). Each of these methods requires trained personnel to perform, and interpretation of their results may not be immediately available. Therefore, we are investigating other noninvasive monitoring techniques that allow for fast interpretation during angiography.

Cerebral optical spectroscopy is noninvasive and provides real-time, easy-to-interpret results. This technique uses near-infrared light to provide physiologic information about the brain. Infrared light penetrates the skin, skull, and cranial contents and is absorbed by oxyhemoglobin, deoxyhemoglobin, and, to a much lesser degree, oxidized cytochrome c oxidase. These substances all are important in brain oxygen metabolism. Transcranial cerebral oximetry (TCCO) (INVOS 3100, Somanetics, Troy, Mich) uses optical wavelengths between 700 and 900 nm to evaluate regional cerebrovascular supply by differentiating oxyhemoglobin from reduced hemoglobin in the frontal lobe (10–15). Currently, data are limited regarding TCCO evaluations of other vascular regions of the brain.

Near-infrared light is generated from a light source using a light-emitting diode. The light is focused directly on the patient's skin and is scattered through cerebral tissues. Previous studies have shown that the distance between the input source and receiving bundle determines the mean path that photons travel through tissue; the greater the separation, the deeper the mean path of photons penetrates the tissue. Accordingly, the oximeter uses two de-

Received May 17, 1994; accepted after revision November 22.

From the Departments of Neurosurgery (G.H.-A., M.D., K.V.S., J.I.A.), Pharmacy Practice (M.S.L.), and Radiology (E.N.), the University of Illinois at Chicago, and the Department of Radiology, Rush Medical School, Chicago, Ill (G.G.).

Address reprint requests to Manuel Dujovny, MD, the University of Illinois at Chicago, College of Medicine, Neuropsychiatric Institute, Department of Neurosurgery (M/C 799), 912 S Wood St, Chicago, IL 60612-7329.

AJNR 16:1618-1625, Sep 1995 0195-6108/95/1608-1618 © American Society of Neuroradiology

tectors located in a sensor to measure the intensity of diffusely transmitted light at different depths of penetration. One detector gathers light passed through the brain and extracerebral contents, while the second detector measures light passed through extracerebral tissues only (Fig 1). From these data, the system derives the oxygen saturation within the cerebral tissue (16-19). The intensities of the collected infrared light are converted to digital information, and oxygen saturation values are displayed in real time (17-19).

Previous clinical applications of TCCO include intraoperative monitoring of carotid endarterectomy and assessment of oxygen supply in patients experiencing vasospasm or stroke or undergoing hypothermia and circulatory ar-

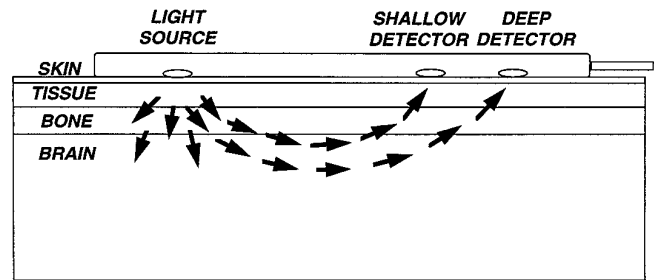


Fig 1. The unique dual sensor design.

rest for repair of difficult aneurysms (1, 16, 18-21). It is a beneficial monitoring device in circumstances in which oxygen supply may be compromised. TCCO provides current physiologic information assisting in the management

TABLE 1: Effect of intravascular catheter manipulation on rSO₂

Case	Diagnosis	Baseline rSO ₂ , R/L	Vessel: Δ _{rSO₂} ^{max}	Final rSO ₂	Comment
1A	R CCF	R : 80-85	ICA : ↓ 11	76	Partial balloon obstruction of ICA lumen
2A	Giant cervical AVM	R : 65-90	highly variable	49-80	Steal phenomenon
3A	R CCF	63/65	R ICA : ↓ 9	64/64	ICA thrombosis, final rSO ₂ after urokinase injection
4A	R occipital AVM	66/68	basilar artery : ↓ 18-30	46/70-76	Basilar artery rupture
5A	L parietal giant AVM	77/81	L MCA : ↑ 7-12	73/79	Catheter occlusion of AVM feeder
6B	L CVA - L carotid artery stenosis	L : 65	L carotid : ↓ 1-2	64	...
7B	L CVA - bilateral carotid stenosis	L : 57	No change	60	Oxygen administered
8B	L CVA - bilateral carotid disease	R : 73	No change	75	Oxygen administered
9B	R CVA - bilateral carotid stenosis	R : 58	R subclavian : ↓ 2	56	...
10B	L CVA - L ICA occlusion	66/55	No change	64/52	...
11B	R CVA - L carotid ulcerated plaque	68/74	L ICA ±1-2	68/76	...
12B	L carotid stenosis	66/60	No change	71/61	Oxygen administered
13B	R carotid stenosis	72/69	R carotid : ↓ 1-2 L vert : ↓ 3 (<1 min)	76/70	Oxygen administered
14B	TIA - L ICA stenosis	58/58	L ICA : ±1-2	58/61	Oxygen administered
15B	Syncope - bilateral ICA occlusion	73/73	L ICA : ↓ 10	74/73	Cerebral infarct
16B	Bilateral occipital infarct - severe Vertebrobasilar atherosclerotic disease	73/72	No change	76/78	Oxygen administered
17B	TIA - L vertebral stenosis	69/73	No change	77/79	Oxygen administered
18B	ICA giant aneurysm	R : 64	No change	64	...
19B	L basal ganglia infarct	81/76	No change	82/74	...
20B	L occipital AVM	68/73	No change	67/73	...
21B	R temporoparietal giant AVM	54/57	No change	54/56	...
22B	L ICH	45/57	No change	47/57	Oxygen administered
23B	R occipital tumor	R : 64	No change	63	Oxygen administered
24B	L temporal meningioma	L : 76	No change	74	...
25B	Brain stem tumor	L : 65	L vert : ↓ 2 R vert : ↑ 3	62	...
26B	L parietal astrocytoma	64/67	No change	66/67	...
27B	Epilepsy	60/70	No change	72/82	...
28B	Epilepsy	69/64	No change	69/63	...
29B	L parietal hemorrhagic contusion	L : 55	No change	56	...
30B	Syncope	R : 79	No change	78	...

Note.—A indicates neuroendovascular therapy in conjunction with cerebral angiography; B, cerebral angiography alone; CVA, cerebrovascular accident; ICH, intracranial hemorrhage; MCA, middle cerebral artery; TIA, transient ischemic attack; vert, vertebral artery; ↓, decrease; and ↑, increase.

TABLE 2: Effect of oxygen administration on rSO₂

Case	Oxygen Dose, L/min	Peripheral Oxygen Saturation Change, %	$\Delta_{rSO_2}^{max}$, R/L	Comment
7B	2	...	L: ↑ 4	...
8B	2	↑ 4	R: ↑ 4	...
12B	3	↑ 3	↑ 7 / ↑ 4	Sedation ↓ 3% on R
13B	...	↑ 6	↑ 3 / ↑ 4	Effect started within 1 min and stabilized at 90 s
14B	3	...	↑ 4 / ↑ 6	Nasal cannula displacement resulted in a decrease in rSO ₂ to baseline; rSO ₂ subsequently increased once the nasal cannula was repositioned
16B	2-5	↑ 6	↑ 4 / ↑ 3	Effect started in 1-2 min and stabilized after 3 min
17B	2	...	↑ 9 / ↑ 6	Nasal cannula displacement resulted in a decrease in rSO ₂ to baseline; rSO ₂ subsequently increased once the nasal cannula was repositioned
22B	3	↑ 9	↑ 12 / ↑ 7	Nasal cannula displacement resulted in a decrease in rSO ₂ to baseline; rSO ₂ subsequently increased once the nasal cannula was repositioned
23B	2	↑ 3	R: ↑ 3	

Note.—↑ indicates increase and ↓, decrease.

and possible prevention of clinical complications.

This report presents data from patients who underwent cerebral angiography with concomitant TCCO monitoring to evaluate the usefulness of continuous regional cerebral oxygen saturation (rSO₂) as a possible means of identifying and preventing clinical complications associated with this procedure.

Materials and Methods

Thirty patients undergoing angiographic procedures were monitored during the procedure with TCCO to detect regional changes in hemoglobin oxygen saturation. Specifications and technology of this device have been previously described (22). Each patient's forehead was prepared with acetone alcohol swabs. Sensor pads were placed bilaterally on the forehead 3 cm from the midline, because the sagittal sinus causes abnormal rSO₂ values. The unit was set up to provide continuous digital readout with data recording into a computer data base. Clinical events were recorded by study personnel, who noted the times of events such as contrast media injection or catheter manipulation. An initial rSO₂ value was obtained before the angiographic procedure. These data served as a baseline value for comparisons between individual events and concurrent rSO₂ value changes from baseline.

In most cases, cerebral angiography was performed under sedation, and, when necessary, oxygen was administered via nasal cannula. A catheter was introduced into the right common femoral artery and selectively directed according to the specific angiographic procedure. Either ioversol (Optiray, Mallinckrodt, St Louis, Mo) or iohexol (Omnipaque, Sterling Pharmaceuticals, Barceloneta, Puerto Rico) was used as the contrast agent. After selective catheterization and contrast injection, digital subtraction angiography was performed.

Results

Of this group of 30 patients, 5 had advanced neurovascular diseases (two carotid cavernous fistulas [CFFs] and three arteriovenous malformations [AVMs]) and underwent procedures that included neuroendovascular therapy in combination with cerebral angiography. The remaining 25 patients all underwent isolated cerebral angiography.

Baseline Values

Baseline rSO₂ values were obtained from both the ipsilateral and contralateral sensor in 18 of 30 patients; in 11 of 30 patients, values were obtained from the ipsilateral sensor only. The remaining patient had values collected from the contralateral sensor only, because of loss of the ipsilateral recording. Baseline rSO₂ values were highly variable between patients with mean stable rSO₂ values ranging from 45% to 90%. Among these patients, baseline rSO₂ values varied by only a few percentage points with one exception. This patient had a giant cervical AVM and was exhibiting a steal phenomenon with rSO₂ values varying from 65% to 90%.

Endovascular Manipulation

Femoral artery catheter placement and advancement up to the aortic arch produced no alterations in peak rSO₂ changes from baseline values ($\Delta_{rSO_2}^{max}$) greater than 1%. Continued progression of the catheter into the cerebral arteries resulted in a more pronounced effect on rSO₂ (Table 1). One patient with syncope un-

dergoing isolated cerebral angiography and 4 of 5 patients undergoing neuroendovascular therapy had the greatest Δ_{rSO_2} max during the course of the procedures. These patients are described in detail below. Of the remaining 25 cases, no Δ_{rSO_2} max greater than 2% for more than 1 minute was observed during catheter placement or manipulation.

A patient with a traumatic right CCF showed significant change in rSO_2 when, in an attempt to occlude the fistula, a balloon was placed bulging into the lumen of the internal carotid artery (ICA). Immediate Δ_{rSO_2} max of -11% was detected. Contrast medium was injected showing partial balloon occlusion of the ICA lumen. The balloon was subsequently deflated with a return of rSO_2 to baseline values. The balloon was repositioned and then inflated without affecting the lumen of the ICA. Again rSO_2 values decreased, but to a lesser extent, developing a new baseline value 6% lower than before.

A second patient with a right CCF had a stable baseline rSO_2 until manipulation of the catheter in the ICA resulted in a Δ_{rSO_2} max of -9%. Mechanical injection of contrast showed a newly developed thrombosis above the origin of the posterior communicating artery. Further patient evaluation showed progressive clinical deterioration resulting in stupor and severe contralateral hemiparesis. Urokinase injections were performed until ICA lumen patency was obtained. Original baseline rSO_2 values were reestablished once the artery lumen was opened.

One patient with an occipital AVM (Fig 2A) who underwent embolization had a stable rSO_2 until catheter manipulation in the basilar artery. This produced an acute Δ_{rSO_2} max of -18% to -30%. (Fig 2B) This drop in rSO_2 was noted before clinical manifestations developed. The procedure was stopped, but the patient became increasingly drowsy and lost consciousness. Computed tomographic scanning confirmed subarachnoid and prepontine hemorrhage (Fig 2C).

No changes in rSO_2 were seen in a patient with a parietal AVM until a catheter was placed in the parietal branch close to the main feeding artery of the AVM. At that point, Δ_{rSO_2} max ranging up to +7% to +12% were observed. Only one patient not undergoing neuroendovascular therapy had significant changes in rSO_2 during the procedure. During manipulation of the catheter in the left ICA, a sudden Δ_{rSO_2} max of -10%

was observed, followed by progressive clinical deterioration of the patient (new onset of agitation, stupor, and right hemiplegia). A computed tomography scan confirmed a left cerebral embolic infarction.

Contrast Injection

Multiple manual and mechanical injections of contrast media were done during catheterization of the vessels. When possible, injections were performed once rSO_2 values had returned to baseline after catheter manipulation. No Δ_{rSO_2} max greater than 2% was observed as the result of the manual injections, and in no case did any change in rSO_2 persist for longer than 1 minute. Immediately after mechanical injections, large fluctuations in Δ_{rSO_2} max were observed; however, beyond 1 minute, a Δ_{rSO_2} max greater than $\pm 1\%$ to 2% was found in only 19 (6.7%) of 282 mechanical injections. Three patients who had a more prolonged and pronounced Δ_{rSO_2} max greater than 2% for longer than 1 minute are discussed below. In every case, changes in rSO_2 were detected only in the ipsilateral sensor.

In one patient with a right CCF, mechanical injection of contrast media produced no changes in rSO_2 as long as the fistula was patent. However, once the balloon was placed, injection produced a Δ_{rSO_2} max of -24% with gradual recovery of baseline values over the next 10 minutes. The second patient with a right CCF experienced a temporary Δ_{rSO_2} max of +4% during concomitant contrast medium and urokinase injection. The patient with syncope had fluctuations in rSO_2 after mechanical injections of contrast media into the left ICA. Catheter manipulation produced a Δ_{rSO_2} max of -10% with no return of baseline values; contrast medium was subsequently injected. A sharp increase in rSO_2 of 23% was observed followed by a sudden decrease in rSO_2 of 34% (net Δ_{rSO_2} max of -11%). A computed tomography scan confirmed the development of a cerebral infarct.

Supplemental Oxygen

Nine patients received supplemental oxygen via nasal cannula at 2 to 5 L/min during the procedure. Changes in both peripheral oximetry and rSO_2 were detected after oxygen was started (Table 2). Stable changes in rSO_2 were

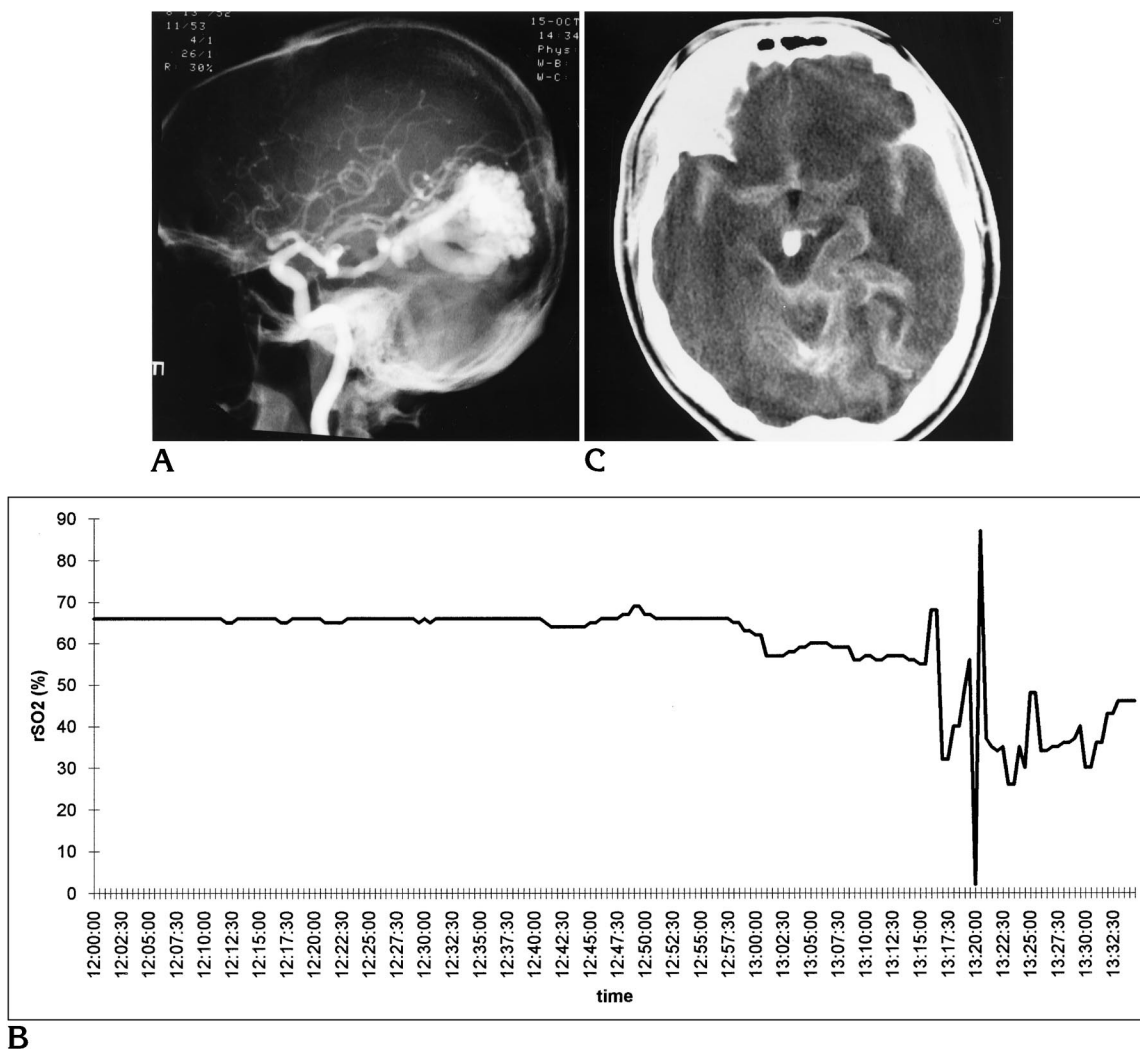


Fig 2. A, Carotid angiogram shows a large occipital arteriovenous malformation. B, rSO₂ during attempted embolization of the right occipital AVM (case 4). The sudden change in saturation pattern indicated a rupture of a branch of the basilar artery. This change preceded the patient's clinical deterioration. C, Computed tomography scan performed after the drop in rSO₂ was recorded, revealing a massive subarachnoid hemorrhage.

usually detected within 1 to 2 minutes after placing the nasal cannula (Fig 3). In three patients, the nasal cannula became displaced during the procedures, resulting in a decrease in rSO₂. Upon cannula repositioning, rSO₂ values stabilized.

Discussion

Baseline Values

A "normal" baseline rSO₂ value has not been established. Subtle differences in skin alter baseline rSO₂ values as the result of differences in melanocyte light absorption (17). Because of this pattern, comparisons among patient base-

line rSO₂ values are not possible. However, looking at changes in rSO₂ ($\Delta_{rSO_2 \max}$) eliminates uncontrolled patient-specific variables such as skin tone or underlying disease state. An rSO₂ value cannot be evaluated individually, and, therefore, each measurement may be considered not independent but only relative as a change over time. The progression or trend in rSO₂ changes provides physiologic information regarding cerebrovascular hemodynamic effects, including compensatory effects, of a procedure or disease state.

Abnormal trends in baseline values of rSO₂ were found in a few patients and felt to be primarily related to the underlying disease. Be-

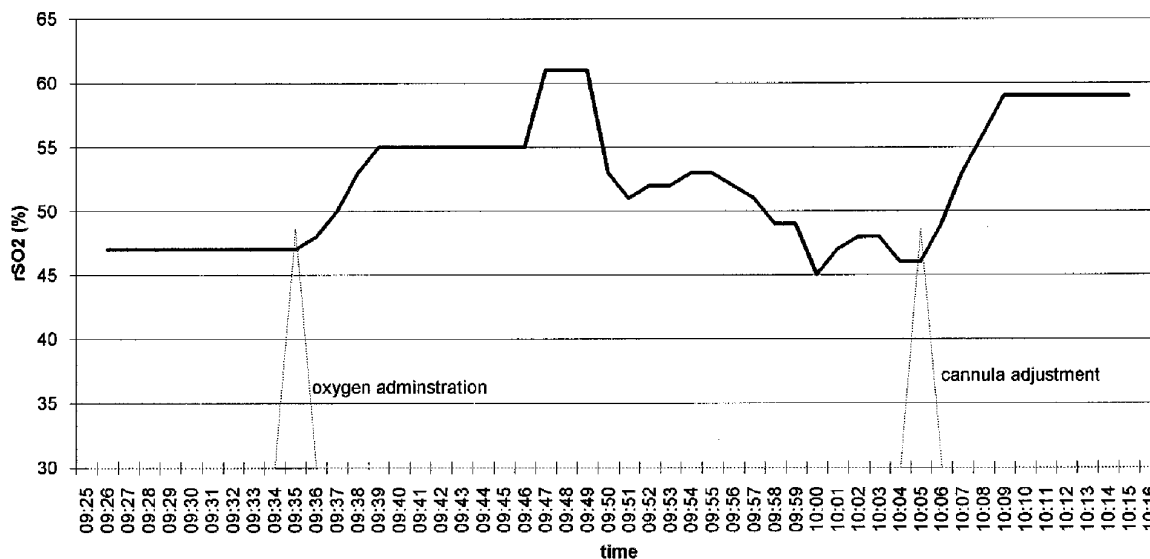


Fig 3. rSO₂ during the administration of supplemental oxygen. The drop in saturation 15 minutes after oxygen administration was started indicated the displacement of the nasal cannula. The adjustment of the cannula resulted in the recovery of saturation values.

cause blood distribution in brain parenchyma is approximately 75% venous and 25% arterial, the rSO₂ obtained by near-infrared light reflects this ratio. The patient with a right CCF who experienced partial lumen occlusion with a balloon exhibited the highest baseline rSO₂ values ranging from 80% to 85%. This high value is explained by the increased venous compartment pressure caused by shunting of arterial blood through the fistula to the ipsilateral ophthalmic vein. A patient with a giant cervical AVM showed a "steal phenomenon" hemodynamic effect reflected as a highly variable baseline rSO₂ value. The higher baseline rSO₂ values in the patient with the giant parietal AVM reflected the presence of available collateral circulation that had developed to compensate a diminished vascular supply. In each case, anatomic anomalies could explain the altered TCCO measurements. These examples accentuate the importance of individualizing baseline rSO₂ values for each patient.

Endovascular Manipulation

The process of catheterization occasionally produced brief changes in rSO₂ from baseline, whereas endovascular manipulation produced prolonged changes in rSO₂. These changes generally persisted as long as the intravascular device was in place. Acute changes occurred in conjunction with clinical events that took place during the procedure. These changes in rSO₂

represented vessel occlusion, hemorrhage, or a redistribution of arterial blood.

Contrast Injection

Changes in rSO₂ after contrast medium injection often fluctuated initially but generally lasted no longer than 1 minute after injection. The only significant decrease in rSO₂ that persisted after contrast injection occurred during concomitant balloon occlusion of a CCF. The initial injections of contrast medium produced no measurable effect as the contrast was shunted through the fistula into the venous system. However, once the fistula was occluded, arterial blood was rerouted to territories normally fed by the ICA. Subsequent contrast medium filled the previously hypoperfused ICA territory with a larger percentage of contrast, producing an endovascular effect decreasing perfusion and rSO₂ and/or an interference with the near-infrared light absorption and unreliable rSO₂ measurements. In no other cases did contrast injections produce a greater than 2% decrease in rSO₂ values for longer than 1 minute. In the patient with a CCF who had an ICA thrombosis requiring thrombolysis, the TCCO also proved useful as a guide for additional mechanical injections of contrast media in the evaluation of lumen patency after urokinase injection by preventing multiple untimed and unnecessary injections of contrast medium.

Supplemental Oxygen

TCCO was a useful tool in evaluating the adequacy of oxygen supply in patients undergoing cerebral angiography. Changes in rSO_2 correlated with changes in peripheral oxygen saturation as measured by pulse oximetry. The TCCO identified nasal cannula displacement once previously stable rSO_2 values dropped more than 1% to 2%; subsequent cannula adjustment resulted in a return of rSO_2 to baseline. Such monitoring might be considered useful in patients with known cerebrovascular disturbances that require supplemental oxygen administration during procedures.

Adverse Effects

Two of 5 patients undergoing neuroendovascular therapy and 1 of 25 patients undergoing isolated cerebral angiography experienced complications during the study. One patient had a thrombosis of the posterior communicating artery, a second patient experienced a prepontine and subarachnoid hemorrhage, and the third patient had an embolic infarction. In each case, the complication occurred during catheter manipulation and was not associated with the concomitant TCCO monitoring. All of the patients studied who underwent endovascular therapy had advanced neurovascular diseases, which selectively enhanced their probability of procedural complications.

Conclusion

Transcranial cerebral oximetry is a noninvasive, real-time technique that provided an easy-to-read method to continuously monitor rSO_2 . The rSO_2 values between patients cannot be compared because of the wide variability in baseline values. Each patient's cerebral oxygenation should be viewed as a change in saturation over time and not as a given value. Acute and permanent changes in rSO_2 were helpful in identifying physical alterations in the cerebral vasculature. Nonionic contrast medium injected by femoral catheterization did not deleteriously affect rSO_2 as determined by TCCO, whereas supplemental oxygen administration by nasal cannula provided increases in rSO_2 .

Immediate changes in rSO_2 provided reliable, real-time assessment of regional brain oxygen supply. In this way, TCCO was useful in the

assessment of neuroendovascular procedures with acute and permanent decreases in rSO_2 being closely related to vascular and neurologic complications. Identifying changes in rSO_2 was useful in the early detection and medical management of these complications. The TCCO appears to be a beneficial device for monitoring neuroendovascular procedures in circumstances in which brain oxygen delivery may be compromised; however, further evaluation is warranted.

The Somanetics INVOS 3100 cerebral oximeter currently has investigational status with the Food and Drug Administration. It is expected to be cleared for commercial sale in the near future at an approximate price of \$8995 for the entire unit and \$59 for disposable sensors (22).

References

1. Kachel R, Jahn U, Schiffmann R, Basche S. Complications in cerebral angiography: a study of 6698 cerebral angiographies. *Rev Med Chir Soc Med Nat Iasi* 1991;95(1-2):97-105
2. Mani R, Eisenberg R, McDonald E, Pollock J, Mani J. Complications of catheter cerebral angiography: analysis of 500 procedures, I: criteria and incidence. *AJR Am J Roentgenol* 1978;131:861-865
3. Markus H, Loh A, Israel D, Buckenham T, Clifton A, Brown MM. Microscopic air embolism during cerebral angiography and strategies for its avoidance. *Lancet* 1993;341(8848):784-787
4. Higashida RT, Halbach VV, Barnwell SL, et al. Treatment of intracranial aneurysms with preservation of the parent vessel: results of percutaneous balloon embolization in 84 patients. *AJNR Am J Neuroradiol* 1990;11:633-640
5. Molsen HP, Grawe A, Nisch G, Siedschlag WD, Winkelmann H. Problems in the balloon occlusion of aneurysms. *Zentralbl Neurochir* 1993;54(1):13-19
6. Dagirmanjian A, Davis D, Rothfus W, Deeb Z, Goldberg A. Silent cerebral microemboli occurring during carotid angiography: frequency as determined by Doppler sonography. *AJNR Am J Neuroradiol* 1993;161:1037-1040
7. Hacke W, Zeumer H, Berg-Dammer E. Monitoring of hemispheric or brainstem functions with neurophysiologic methods during interventional neuroradiology. *AJNR Am J Neuroradiol* 1983;4:382-384
8. Nornes H, Sorteberg W, Nakstad P, Bakke SJ, Aaslid R, Lindgaard KF. Haemodynamic aspects of clinical cerebral angiography: concurrent two vessel monitoring using transcranial Doppler ultrasound. *Acta Neurochir (Wien)* 1990;105:89-97
9. Zentner J, Schumacher M, Bien S. Motor evoked potentials during interventional neuroradiology. *Neuroradiology* 1988;30(3):252-255
10. Chance B, Leigh JS, Miyake H, et al. Comparison of time-resolved and un-resolved measurements of deoxyhemoglobin in brain. *Proc Natl Acad Sci U S A* 1988;85:4971-4975
11. Eggert H, Blazek V. Optical properties of human brain tissue, meninges, brain tumors in the spectral range of 200-900 nm. *Neurosurgery* 1987;21:459-464

12. Gopinath S, Robertson C, Grossman R, Chance B. Near-infrared spectroscopic localization of intracranial hematomas. *J Neurosurg* 1993;79:43-47
13. Hazeki O, Tamura M. Quantitative analysis of hemoglobin oxygenation state in the rat brain in situ by near infrared spectrophotometry. *J Appl Physiol* 1988;64:796-802
14. McCormick P, Stewart M, Ray P, Lewis G, Dujovny M, Ausman J. Measurement of regional cerebrovascular hemoglobin oxygen saturation in cats using optic spectroscopy. *Neurol Res* 1991;13:65-70
15. Smith DS, Levy W, Maris M, Chance B. Reperfusion hyperoxia in brain after circulatory arrest in humans. *Anesthesiology* 1990;73:12-19
16. Ausman J, McCormick P, Stewart M, et al. Cerebral oxygen metabolism during hypothermic circulatory arrest in humans. *J Neurosurg* 1993;79:810-815
17. Dujovny M, Lewis G, Vinas F, Ausman J, Silva P, Flemming JE. Cerebral oxygen saturation as a function of age, sex, and skin color. *SPIE Proceedings* 1992;1641:126-132
18. McCormick P, Stewart M, Lewis G, Dujovny M, Ausman J. Intracerebral penetration of infrared light: technical note. *J Neurosurg* 1992;76:315-318
19. McCormick P, Stewart M, Goetting M, Dujovny M, Lewis G, Ausman JI. Noninvasive cerebral optical spectroscopy for monitoring cerebral oxygen delivery and hemodynamics. *Crit Care Med* 1991;19:89-97
20. Ferrari M, Zanette E, Sideri G, Giannini I, Fieschi C, Carpi A. Effects of carotid compression as assessed by near infrared spectroscopy, upon cerebral blood volume and hemoglobin oxygen saturation. *J R Soc Med* 1987;80:83-87
21. Williams IM, McCollum C. Cerebral oximetry in carotid endarterectomy and acute stroke. In: Greenhalgh RM, Hollier LH, eds. *Surgery for Stroke*. London: WB Saunders, 1993:129-138
22. Dujovny M, Slavin KV, Cui W, Lewis G, Ausman JI. Somanetics INVOS 3100 cerebral oximeter: instrumentation, technique, and technology. *Neurosurgery* 1994;34(5):935-936