

Are your **MRI contrast agents** cost-effective?

Learn more about generic **Gadolinium-Based Contrast Agents**.



FRESENIUS
KABI

caring for life

AJNR

Use of functional MR to map language in multilingual volunteers.

O Yetkin, F Zerrin Yetkin, V M Haughton and R W Cox

AJNR Am J Neuroradiol 1996, 17 (3) 473-477

<http://www.ajnr.org/content/17/3/473>

This information is current as
of April 18, 2024.

Use of Functional MR to Map Language in Multilingual Volunteers

Oguz Yetkin, F. Zerrin Yetkin, Victor M. Haughton, and Robert W. Cox

PURPOSE: To use functional MR imaging to compare brain activation during processing of languages in which multilingual volunteers are fluent with brain activation during processing of languages in which they are not fluent. **METHODS:** Echoplanar images were obtained for five right-handed male multilingual subjects who performed a language task in three languages, one of which was a language in which the subject was not fluent. The functional MR technique included echoplanar images obtained at 1 per second during cycles of rest and performance of the task, from which functional images were processed by means of cross-correlation analysis. The numbers of active pixels in each volunteer and for each language were compared. **RESULTS:** Activation was noted in the left frontal lobe in all subjects performing language tasks. In each subject, the number of activated pixels was greatest for the language in which the subject was least fluent. **CONCLUSION:** Functional MR imaging shows differences in the processing of different languages in multilingual volunteer subjects, depending on the level of fluency in the language, and it is an effective functional imaging method for studying the processing of different languages.

Index terms: Brain, magnetic resonance; Magnetic resonance, functional; Speech

AJNR Am J Neuroradiol 17:473-477, March 1996

Functional magnetic resonance (MR) imaging is a noninvasive imaging technique for studying the organization of cognitive functions in the brain. Functional MR imaging provides maps of cerebral activation, which are registered to anatomic images. Because it is noninvasive, functional MR imaging can be repeated several times without risk to the subject. The functional maps of different tasks obtained with functional MR imaging can be compared without averaging between subjects.

Language organization in the brain has been studied with positron emission tomography (PET) (1-6), intraoperative stimulation mapping (7-11), and functional MR imaging (12-15). PET has shown activation in the left prefrontal cortex (Broca's area) caused by word generation or counting tasks (5). Studies with intraoperative cortical stimulation in multilin-

gual patients support the hypothesis that different groups of neurons may be involved in processing different languages. In multilingual patients, stroke may alter the function of one but not all languages; this clinical observation suggests that different languages may be processed in different regions in the brain (11). The language studies reported to date with functional MR imaging have not included multilingual volunteer subjects. The purpose of this study was to use functional MR imaging to measure the number of pixels activated during the processing of languages in which the multilingual volunteer subjects are fluent or nonfluent.

Subjects and Methods

Five right-handed male multilingual volunteer subjects with no history of neurologic disorder were recruited. Each subject spoke not only his native language but also a second language fluently; each subject also had studied a third language for 2 to 4 years, but he did not regularly converse in this language (Table 1). In this study, *fluent* was defined as speaking the language currently and for at least 5 years. The two languages in which the subject was fluent were labeled languages 1 and 2 (language 1 was always English); each subject's nonfluent was called language 3.

Received June 15, 1995; accepted after revision September 27.

From the Departments of Radiology (O.Y., F.Z.Y., V.M.H.) and Biophysics (R.W.C.), Medical College of Wisconsin, Milwaukee.

Address reprint requests to Victor M. Haughton, MD, Department of Radiology, Doyne Clinic/Box 151, 8700 W Wisconsin Ave, Milwaukee, WI 53226.

AJNR 17:473-477, Mar 1996 0195-6108/96/1703-0473

© American Society of Neuroradiology

TABLE 1: Languages studied in the multilingual volunteer subjects

Subject	Language 1	Language 2	Language 3†
1	English*	German	Russian
2	English	Turkish*	Japanese
3	English*	Norwegian	French
4	English*	Norwegian	Spanish
5	English	Chinese*	Japanese

* Native language.

† Language 3 is the language in which the subject is not fluent.

The protocol for each subject included word-generation tasks in the native language, the other language in which he was fluent, and the language in which he was nonfluent. For the word-generation task (13), the subject was cued by the investigator with a letter selected randomly from the alphabet of the selected language, and the subject silently generated words in that language that began with the letter until cued by the investigator to stop. In each functional MR acquisition, three 20-second periods of word generation were interspersed with four 20-second periods of rest during which the subject refrained from thinking of words. The subjects were instructed in the tasks and rehearsed before they were scanned. All the subjects were right-handed. Word generation was performed sequentially with languages 1 through 3 in each subject.

After signing a consent form and inserting ear plugs, each subject was positioned in a 1.5-T imager equipped with a three-axis gradient coil and an end-capped birdcage receiver coil. A series of seven parallel sagittal anatomic images was obtained with the following parameters: 600/20/1 (repetition time/echo time/excitations), spin-echo, and 10-mm section thickness to encompass the left hemisphere. During each sequence of word generation and rest, echoplanar images were obtained each second in each of the seven planes for a total of 140 seconds (13). The technical factors for each echoplanar image included 1000/40/1, 1-cm section thickness, 64×64 matrix, 24-cm field of view, and 40-millisecond acquisition time. The time course of the signal intensity in each pixel for a period of 140 seconds was plotted and compared with a

reference function by means of a cross-correlation program (16). The reference function used was a modified square wave with a period of 40 seconds. The first 5 seconds of the time course and the first 5 seconds of each rest and task period were disregarded in the cross-correlation calculation. The correlation coefficients were calculated for each pixel. *Activated* pixels were those for which the correlation coefficient exceeded .60 (the selected threshold correlation coefficient for this study). The activated pixels in the functional images were then overlaid on the exactly corresponding anatomic reference images by means of the image-processing program.

Two neuroradiologists evaluated the functional images overlaid on the anatomic images. The anatomic landmarks defining the frontal lobe were identified by consensus and by means of the criteria used in previous functional MR imaging studies (17, 18). We tabulated the number of activated pixels in the frontal and parietal gyri adjacent to the central sulcus, in the frontal lobe exclusive of the precentral gyrus, and in the parietal lobe exclusive of the postcentral gyrus. Pixels outside the frontal and parietal lobes were not counted. An index of activation was used to compare the number of pixels activated by each language task in each subject. The index of activation was calculated as a percentage as follows: (the number of pixels activated by each language/the total number of pixels activated by all three languages) $\times 100$. The significance of the differences was determined by using Student's *t* test.

Results

Temporally correlated activation was observed in all experiments, and all images appeared free of motion artifacts. All subjects claimed to have understood the instructions and to have performed the word-generation tasks according to instructions. In all subjects, activation from the language tasks was observed primarily in the lateral sections (sections 2 and 3) in the left prefrontal cortex (Fig 1). Most of the

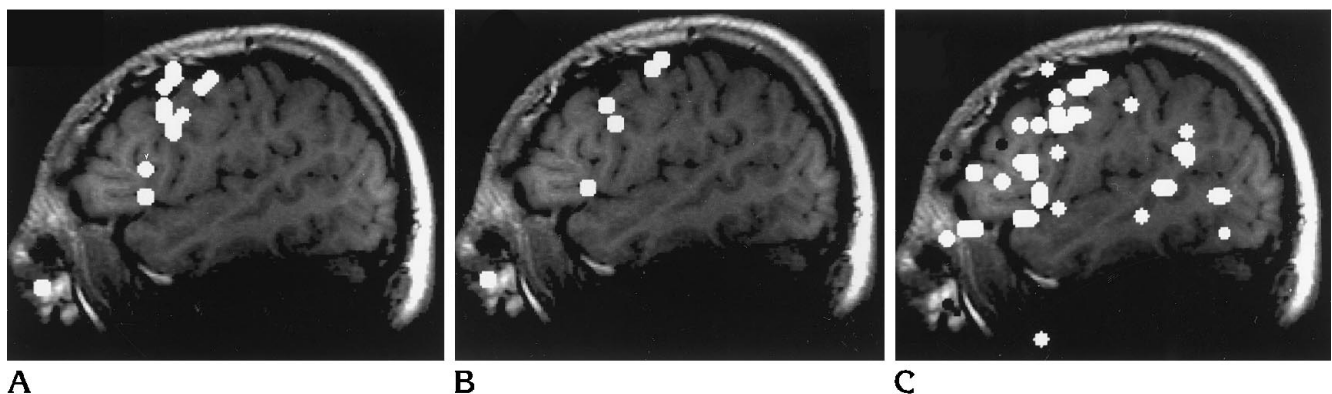


Fig 1. Functional MR images of a volunteer performing silent word generation in his native language (A), in a foreign language in which he is fluent (B), and in a language in which he is not fluent (C). Most of the activation is observed in prefrontal and frontoparietal regions. Note the increased number of activated pixels for the language in which the subject is not fluent (C).

TABLE 2: Number of activated pixels in each volunteer from each language

Subject	Language	Frontal	Frontoparietal	Parietal	Total	Index, %
1	1	8	11	1	20	39
	2	0	10	0	10	20
	3	3	17	1	21	41
2	1	0	6	0	6	18
	2	0	5	0	5	15
	3	5	16	2	23	68
3	1	1	9	2	12	16
	2	6	13	1	20	26
	3	13	31	0	44	58
4	1	7	9	1	17	23
	2	2	5	0	7	10
	3	27	22	0	49	67
5	1	4	15	0	19	29
	2	0	5	0	5	8
	3	20	21	0	41	63

activated pixels were related to the inferior frontal, middle frontal, and precentral gyri.

For all five subjects, the number of activated pixels was greatest for the language in which the person was least fluent. The number of pixels activated in the frontal, frontoparietal, and parietal cortices, respectively, are shown in Table 2. Activation was also noted in more medial sections in the frontoparietal cortex and in supplementary motor areas. The average number of pixels activated by each language is shown in Figure 2.

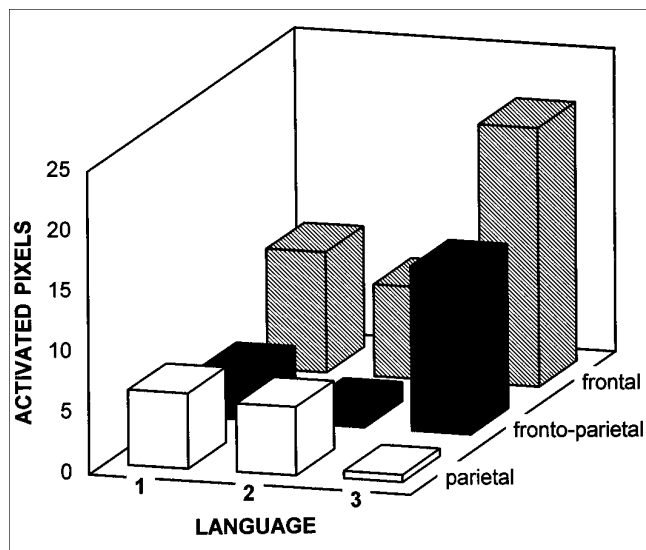


Fig 2. Graph shows the average number of pixels activated by each of three languages in the frontal, frontoparietal, and parietal regions.

The indexes of language activation are shown in Table 2. The indexes for languages 1 and 2 ranged from 8% to 39%, and from 41% to 68% for language 3. The average indexes were as follows: language 1, 25%; language 2, 16%; and language 3, 59% (Fig 3). The differences between the third language and the first or the second language was significant ($P < .001$, Student's *t* test). The differences between languages 1 and 2 were not significant. The index for language 1 was higher than the index for language two in four subjects. The second language in which the subject was fluent had a higher index than that of the native language in three subjects.

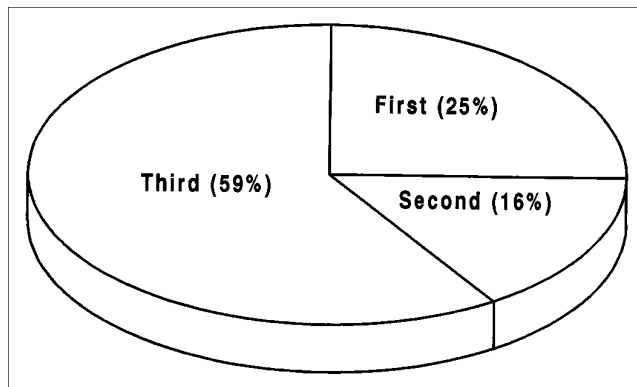


Fig 3. Average activation indexes for the three languages in the subjects.

Discussion

This study suggests that functional MR imaging can show differences in the organization of different languages in a multilingual person. The results of this pilot study are consistent with this previously untested hypothesis: in a multilingual person, language in which the person is not fluent produces more cerebral activation than does a language in which the person is fluent. More pixels were activated when the subject was not fluent than when the subject was fluent. Published results indicate that during craniotomy in multilingual patients, regions of the brain are identified in which cortical stimulation may interrupt functioning in one language but not in another (11). Our results are similar in that the regions of brain activated by the different languages do not overlap completely. A PET study of bilingual subjects, fluent in two languages, showed nearly equal activation in the left inferior frontal region from the two languages (6), results that are similar to those in our study. The lower amount of brain activation needed for a language task conducted in the fluent language can be compared with the results of a PET study that showed that brain glucose metabolism from complex visuospatial-motor tasks decreases as facility increases (19).

The frontal lobe regions activated in our study correspond well to regions activated in previous PET studies (1–6). We did not find a significant difference between the native language and the other language in which the subject was fluent, but our study design was not optimized for this purpose. The order of the languages tasks was not randomized in this study. Practice effects are known to decrease activation in PET imaging. The decrease in activation seen in most subjects performing the second language task may be evidence of a practice effect. English was performed first on the assumption that for all the subjects, it was the most used language. We elected to have the word generation performed silently to minimize the artifacts that occur with audible word generation (13). Therefore, accurate performance of the task was not verified, but our subjects claimed to have complied with the instructions. Differences in the organization of language functions in the brains of male and female subjects have been shown with functional MR imaging (15), so to minimize test variables, all our subjects were male. The

languages included were intentionally diverse to minimize biases caused by language selection. The functional MR imaging techniques for identifying activated pixels have been used extensively, but thresholds, language tasks, and technical parameters may not have been optimized. Eye movements that may contribute to artifacts were not monitored, but the activation identified does not correspond to eye movement fields or the usual location of motion artifacts. The language tasks used in functional MR imaging are not precisely defined in behavioral terms. No precise measure of fluency or the speed of word generation was attempted.

In summary, functional MR imaging in multilingual subjects seems to measure more activation in the cerebral processing of languages in which a subject is not fluent than in the cerebral processing of languages in which the subject is fluent. Although the results of this study are preliminary, they are consistent with the hypothesis that activation decreases as proficiency in a language increases. Functional MR imaging provides an important new tool for studying language functions in patients or in healthy subjects.

References

1. Frith CD, Friston KJ, Liddle PF, Frackowiak RSJ. A PET study of word finding. *Neuropsychologia* 1991;29:1137–1148
2. Leblanc R, Meyer E, Bub D, Zatorre RJ, Evans AC. Language localization with activation positron emission tomography scanning. *Neurosurgery* 1992;31:369–373
3. Haxby JV, Grady CL, Ungerleider LG, Horwitz B. Mapping the functional neuroanatomy of the intact human brain with brain work imaging. *Neuropsychologia* 1991;29:539–555
4. Petersen SE, Fiez JA. The processing of single words studied with positron emission tomography. *Annu Rev Neurosci* 1993;16:509–530
5. Wise R, Hadar U, Howard D, Patterson K. Language activation studies with positron emission tomography. In: *Exploring Brain Functional Anatomy with Positron Tomography*. Chichester, England: Wiley, 1991:218–234
6. Klein D, Milner B, Zatorre RJ, et al. The neural substrates underlying word generation: a bilingual functional imaging study. *Proc Natl Acad Sci USA* 1995;92:2899–2903
7. Ojemann G, Cawthon DF, et al. Localization and physiological correlates of language and verbal memory in human lateral temporoparietal cortex. In: Schiebel AB, Wechsler AF, eds. *Neurobiology of Higher Cognitive Function*. Guilford Press, 1990:185–203
8. Ojemann G. Brain organization for language from the perspective of electrical stimulation mapping. *Behav Brain Sci* 1983;6:189–206
9. Ojemann GA, Creutzfeldt OD, et al. Neuronal activity in human temporal cortex related to naming and short-term verbal memory. In: Engel J Jr, ed. *Fundamental Mechanisms of Human Brain Function*. New York, NY: Raven Press, 1987:61–68

10. Schaffler L, Luders HO, Dinner DS, Lesser RP, Chelune GJ. Comprehension deficits elicited by electrical stimulation of Broca's area. *Brain* 1993;116:695-715
11. Ojemann G, Whitaker H. The bilingual brain. *Arch Neurol* 1978;35:409-412
12. Hinke RM, Hu X, Stillman AE, et al. Functional magnetic resonance of Broca's area during internal speech. *Neuroreport* 1993;4:675-678
13. Yetkin FZ, Mueller WM, Morris GL, Hammeke TA, Haughton VM. A comparison of functional MR activation patterns during silent and audible language tasks. *AJNR Am J Neuroradiol* 1995;16:1087-1092
14. Binder JR, Rao SM, Hammeke TA, et al. Functional magnetic resonance imaging of human auditory cortex. *Ann Neurol* 1994;35:662-672
15. Shaywitz BA, Shaywitz SE, Pugh KR, et al. Sex differences in the functional organization of the brain for language. *Nature* 1994;3:607-609
16. Bandettini PA, Jasmanowicz A, Wong AC, et al. Processing strategies for time-course data sets in functional MRI of the human brain. *Magn Reson Med* 1993;30:161-173
17. Rademacher J, Gallaburda AM, Kennedy DN, et al. Human cerebral cortex: localization, parcellation and morphometry with magnetic resonance imaging. *J Cog Neurosci* 1992;4:352-374
18. Ebelling V, Steinmetz H, Yanxiong H, et al. Topography and identification of the inferior precentral sulcus on MR imaging. *AJNR Am J Neuroradiol* 1989;10:937-942
19. Haier RG, Siegel BV, MacLachlan A, et al. Regional glucose metabolic changes after learning a complex visuospatial/motor task: a positron emission tomographic study. *Brain Res* 1992;570:134-143