

Are your **MRI contrast agents** cost-effective?

Learn more about generic **Gadolinium-Based Contrast Agents**.



FRESENIUS
KABI

caring for life

AJNR

Balance and equilibrium, II: The retrovestibular neural pathway.

J D Swartz, D L Daniels, H R Harnsberger, J L Ulmer, S Harvey,
K A Shaffer and L Mark

AJNR Am J Neuroradiol 1996, 17 (6) 1187-1190

<http://www.ajnr.org/content/17/6/1187.citation>

This information is current as
of April 19, 2024.

Balance and Equilibrium, II: The Retrovestibular Neural Pathway

Joel D. Swartz, David L. Daniels, H. Ric Harnsberger, John L. Ulmer, Steven Harvey, Katherine A. Shaffer, and Leighton Mark

In this article, we will consider the anatomy of the retrovestibular pathways: the superior and inferior vestibular nerves and related intraaxial structures. The reader is encouraged to review previous installments if questions arise regarding terminology.

The internal auditory canal (IAC) is highly variable in size, shape, and orientation (1). As a general rule, there is symmetry between the right and left canals in the same person. The IAC is defined as having a *porus* (meatus) medially along the petrous surface and a *fundus* laterally abutting the labyrinth. At the fundus, a transverse (falciform) crest separates the canal into superior and inferior compartments. Furthermore, a vertical crest (Bill's bar) subdivides the superior compartment into anterior and posterior portions (Figs 1 and 2). The facial nerve is located in the anterosuperior compartment. The cochlear nerve is anteroinferior to the facial nerve. These structures will be discussed further in subsequent installments.

Impulses from the utricular macula and the ampullae of the superior and lateral semicircular canals travel via the superior vestibular nerve in the *posterosuperior compartment* of the IAC (2, 3) (Figs 3 and 4). Impulses from the saccular macula and posterior semicircular canal travel primarily via the inferior vestibular nerve within the *posteroinferior compartment* of the internal auditory canal (the saccule is actually innervated by all three segments of the vestibulocochlear nerve (Fig 5). The nerve of the posterior semicircular canal (singular nerve) travels separate from the inferior vestibular

nerve within this quadrant (Fig 3). This anatomic arrangement allows for surgical denervation of the posterior semicircular canal (singular neurectomy), a procedure indicated for many patients with chronic benign positional vertigo (cupulolithiasis) (4).

The vestibular (Scarpa's) ganglion is situated within the IAC and is responsible for mediation of afferent and efferent impulses of the saccule, utricle, and all three semicircular canals (3). As such, the vestibular nerve has five terminal branches. Four vestibular nuclei are located in the brain stem at the pontomedullary junction medial to the cochlear nuclei at the level of the floor of the fourth ventricle (2, 5) (Fig 6). Fibers of the vestibular nerves synapse in these nuclei. Activity within the brain stem is quite complex and beyond the realm of this communication. Suffice it to say that fibers travel via the vestibulospinal tract (regulation of muscle tone), vestibulocerebellar tract (coordination), reticular formation (regulation of consciousness), and medial longitudinal fasciculus (eye movement).

When the vestibular apparatus is rendered dysfunctional (such as by inflammation or neoplasm), a sense of disequilibrium results (5). True *vertigo* is a particular form of disequilibrium specific to disease of the vestibular system and is often associated with other visceral disturbances such as nausea, vomiting, sweating, and tachycardia. This is to be clinically distinguished from dizziness, which is a nonspecific symptom frequently caused by disease elsewhere.

From the Department of Radiology, Germantown Hospital and Medical Center, Philadelphia, Pa (J.D.S.), the Section of Neuroradiology, Department of Radiology (D.L.D., J.L.U., K.A.S., L.M.) and Department of Otolaryngology (S.H.), Medical College of Wisconsin, Milwaukee, and the Section of Neuroradiology, Department of Radiology, University of Utah Medical Center, Salt Lake City (H.R.H.).

Address reprint requests to David L. Daniels, MD, Section of Neuroradiology, Department of Radiology/DH 151, Doyne Clinic, Medical College of Wisconsin, 8700 W Wisconsin Ave, Milwaukee, WI 53226.

Index terms: Balance; Nerves, anatomy; Temporal bone, anatomy; Anatomic moments

AJNR 17:1187-1190, Jun 1996 0195-6108/96/1706-1187 © American Society of Neuroradiology

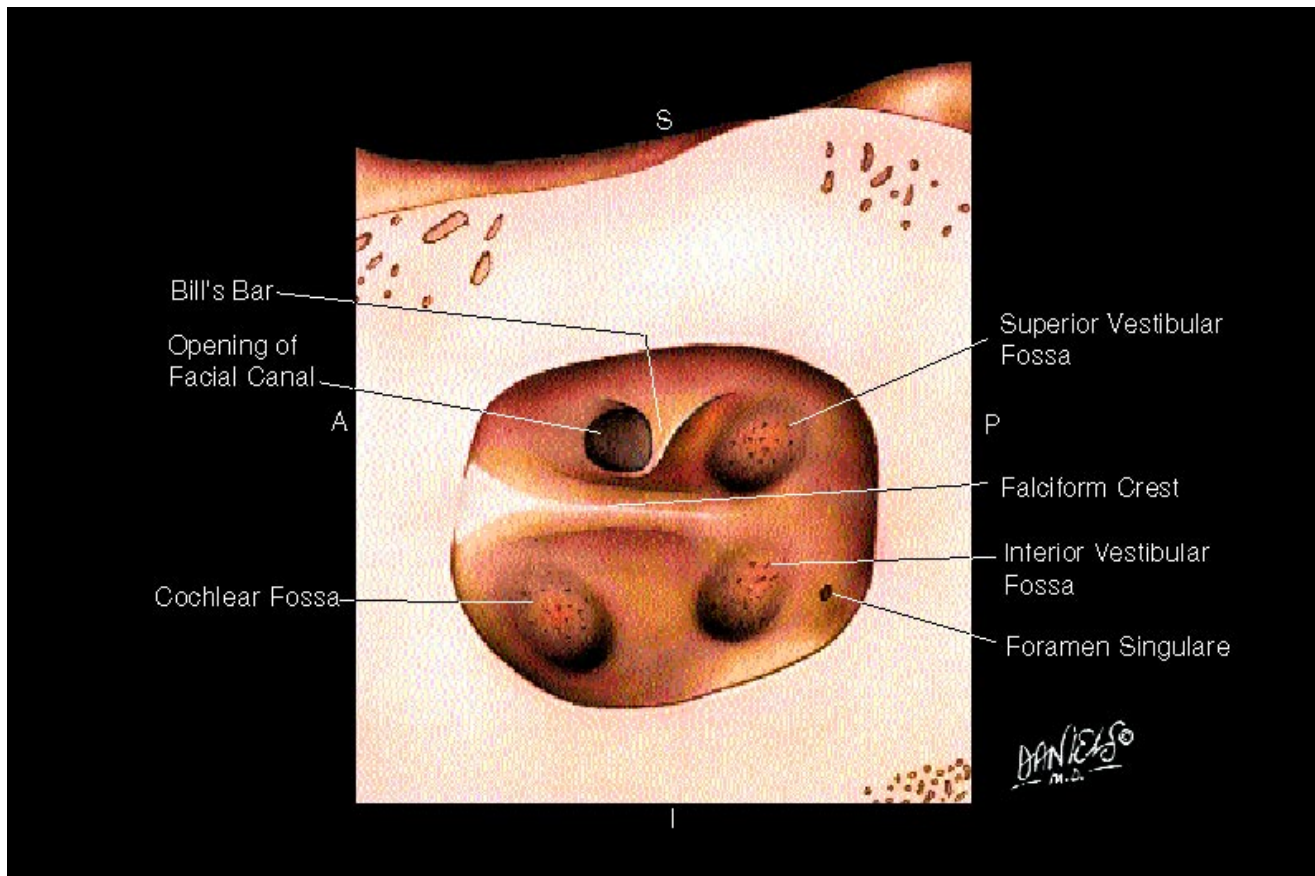
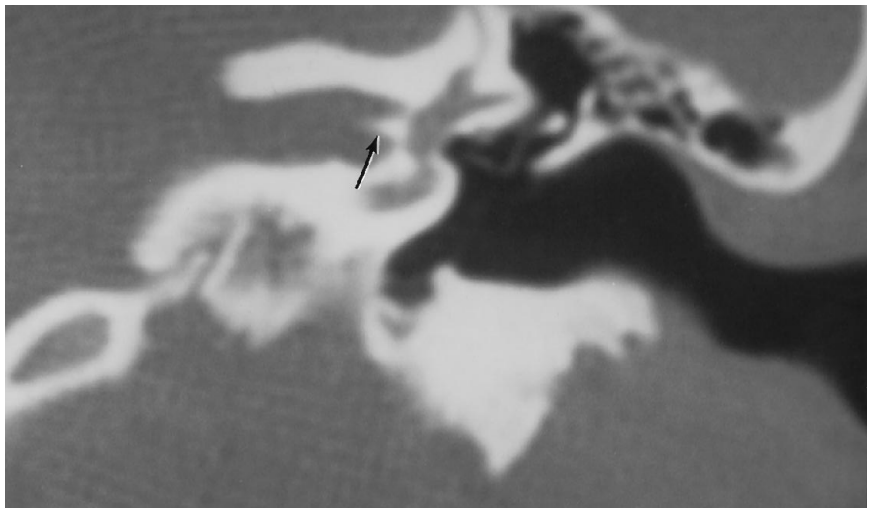


Fig 1. Medial view of the fundus of the internal auditory canal. Located at the fundus are the opening of the facial canal and the cochlear and superior and inferior vestibular fossae, through which nerve fibers extend to form the cochlear and vestibular nerves. The falciform crest separates the anterior two thirds of the fundus into superior and inferior compartments, then curves anteriorly to form a ridge at the anterolateral aspect of the internal auditory canal. Bill's bar is a small osseous ridge projecting medially from the posterior wall of the facial canal; it separates the canal from the superior vestibular fossa. *A* indicates anterior; *P*, posterior; *S*, superior; and *I* inferior (modified from Proctor [6] and Ferner [7]).

Fig 2. Thin-section coronal computed tomographic scan demonstrates the internal auditory canal separated by the horizontal falciform crest (*arrow*).



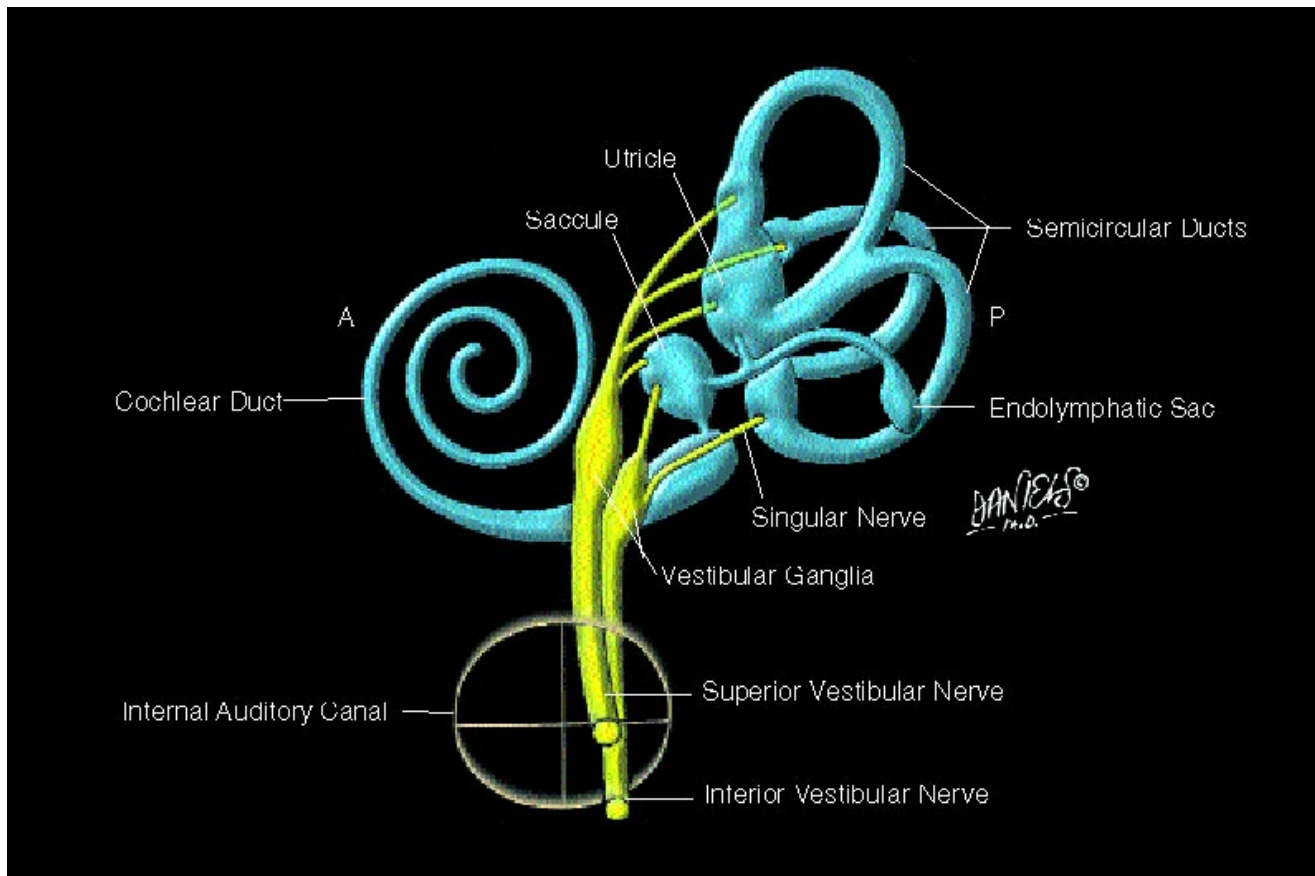


Fig 3. Medial view of the membranous labyrinth. Shown are nerve fibers arising from the maculae of the saccule and utricle and the ampullae of the semicircular ducts, the vestibular ganglia located in the lateral aspect of the internal auditory canal, and the vestibular nerves. The superior and inferior vestibular nerves course through the posterosuperior and posteroinferior compartments, respectively, of the internal auditory canal. The classic appearance of the endolymphatic sac is illustrated; a subsequent Anatomic Moment will discuss current concepts of the endolymphatic sac and duct. A indicates anterior; P, posterior (modified from Proctor [6] and Ferner [7]).

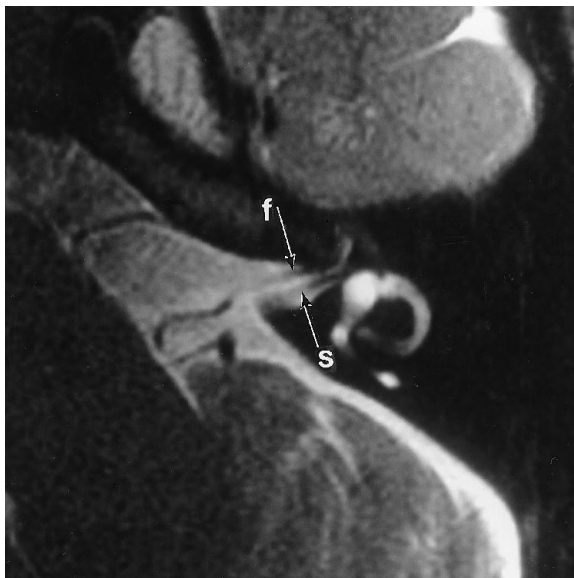

Fig 4. Axial thin-section T2-weighted fast spin-echo magnetic resonance image through the superior aspect of the internal auditory canal demonstrates the facial nerve (*f*) anteriorly and the superior vestibular nerve (*s*) posteriorly (arrows).

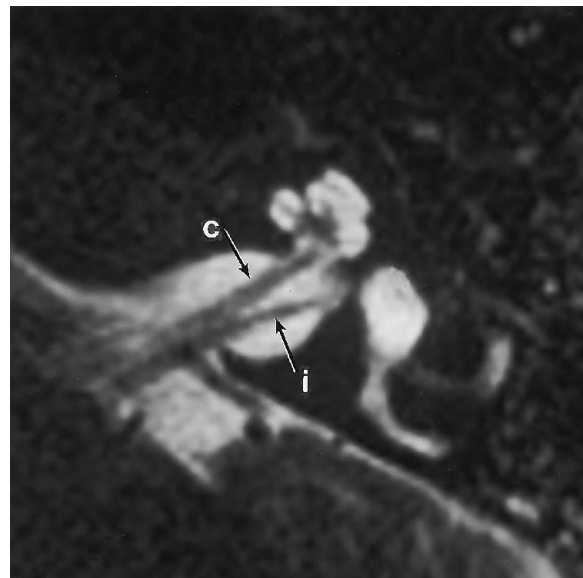


Fig 5. Axial thin-section T2-weighted fast spin-echo magnetic resonance image through the inferior aspect of the internal auditory canal demonstrates the cochlear nerve (*c*) anteriorly and the inferior vestibular nerve (*i*) posteriorly (arrows).

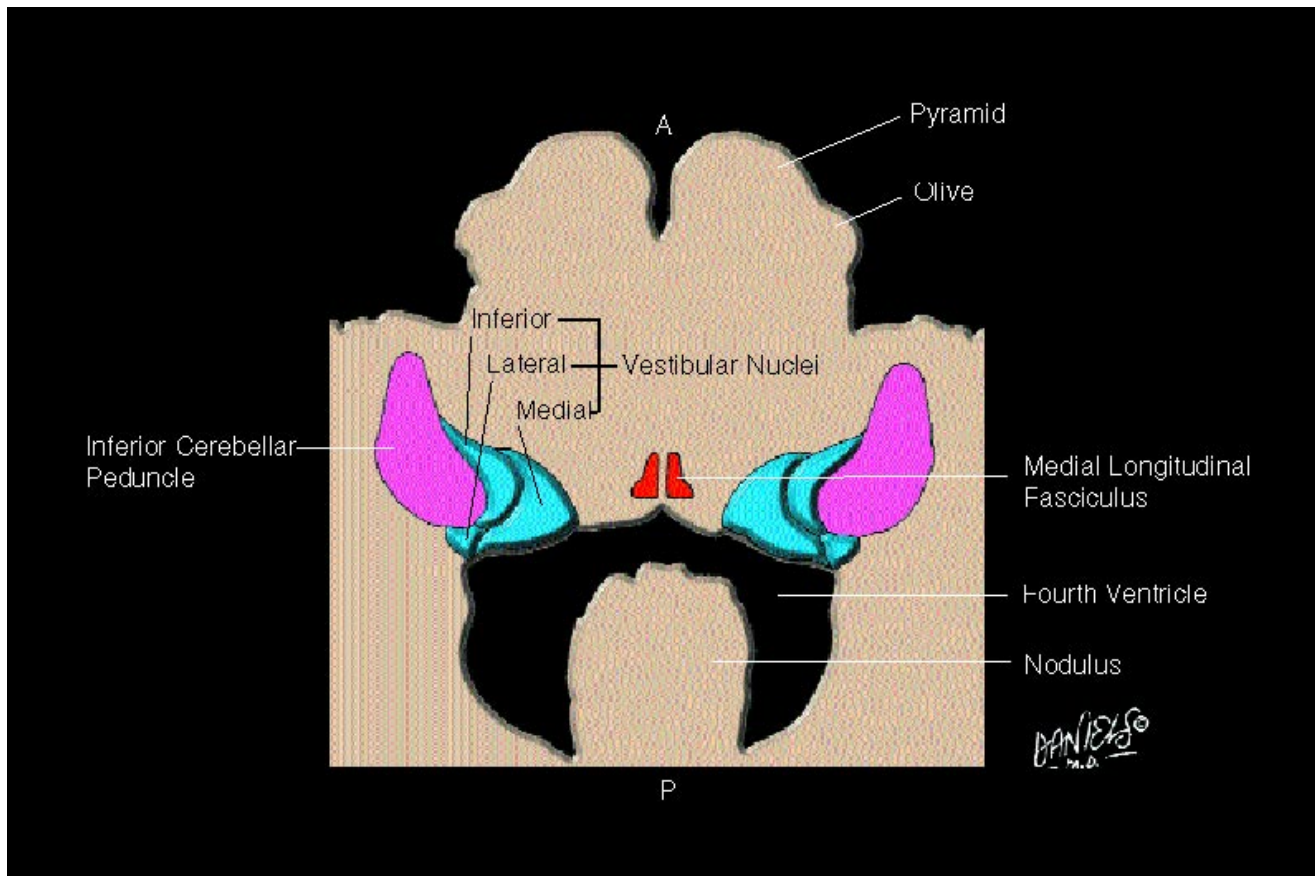


Fig 6. Axial view at the level of the upper medulla and floor of the fourth ventricle shows the vestibular nuclear complex (excluding the superior nucleus) located medial to the inferior cerebellar peduncle. The vestibular nuclei are positioned to send fibers to the paramidline medial longitudinal fasciculi. A indicates anterior; P, posterior (modified from DeArmond et al [8] and Netter and Colacino [9]).

References

- Schuknecht HF, Gulya AJ. *Anatomy of the Temporal Bone with Surgical Implications*. Philadelphia, Pa: Lea & Febiger; 1986
- Wilson-Pauwels L, Akesson EJ, Stewart PA, ed. *Cranial Nerves: Anatomy and Clinical Comments*. Toronto, Canada: BC Decker Inc; 1988:97-112
- Nager GT. *Pathology of the Ear and Temporal Bone*. Baltimore, Md: Williams & Wilkins; 1993:3-49
- Schuknecht H. *Pathology of the Ear*. 2nd ed, Philadelphia, Pa: Lea & Febiger; 1993:45-66
- Daube JR, Reagan TJ, Sandok BA, Westmoreland BF. *Medical Neurosciences: An Approach to Anatomy, Pathology and Physiology by Systems and Levels*. New York, NY: Little Brown & Co; 1986:357-365
- Proctor B. *Surgical Anatomy of the Ear and Temporal Bone*. New York, NY: Thieme Medical Publishers Inc; 1989:90,125,127
- Ferner H, ed. *Pernkopf Atlas of Topographical and Applied Human Anatomy*. Baltimore, Md: Urban & Schwarzenberg; 1980:162,168
- DeArmond SJ, Fusco MM, Dewey MM. *Structure of the Human Brain: A Photographic Atlas*. New York, NY: Oxford University Press; 1989:94
- Netter H, Colacino S. *Atlas of Human Anatomy*. Summit, New Jersey: Ciba-Gigy Corp; 1989: plate 118