Are your MRI contrast agents cost-effective?
Learn more about generic Gadolinium-Based Contrast Agents.
FRESENIUS KABI
caring for life

AJNR

MR characteristics of primary extramedullary plasmacytoma in the head and neck.

T J Vogl, W Steger, G Grevers, J Balzer, M Mack and R Felix

AJNR Am J Neuroradiol 1996, 17 (7) 1349-1354
http://www.ajnr.org/content/17/7/1349

This information is current as of April 23, 2024.

MR Characteristics of Primary Extramedullary Plasmacytoma in the Head and Neck

Thomas J. Vogl, Wolfgang Steger, Gerd Grevers, Jörn Balzer, Martin Mack, and Roland Felix

PURPOSE: To define MR characteristics of primary extramedullary plasmacytoma in the head and neck using a variety of plain and contrast-enhanced MR protocols. **METHODS:** Six patients with primary extramedullary plasmacytoma in the head and neck were examined clinically and with MR imaging at 1.5 T. The morphologic appearance and signal intensities of the lesions were analyzed and the results of the imaging findings were compared with histopathologic findings. **RESULTS:** Qualitative analysis showed that five lesions were oval and sharply demarcated without signs of infiltration; the other lesion filled the parapharyngeal space bilaterally. On T2-weighted sequences, the lesions had moderate signal intensity. On plain T1-weighted sequences, the tumors were isointense or slightly hyperintense with respect to surrounding muscles; after administration of contrast medium, four lesions showed notable enhancement, with distinct central inhomogeneity. **CONCLUSION:** Although morphologic features or evidence of contrast enhancement do not assure certain diagnosis of extramedullary plasmacytoma, these MR imaging characteristics should prompt the radiologist to include this rare lesion in the differential diagnosis.

Index terms: Neck, magnetic resonance; Neck, neoplasms

AJNR Am J Neuroradiol 17:1349–1354, August 1996

A wide variety of tumorous lesions with different morphologic appearances and growth patterns arise in the head and neck region. In the past decade, magnetic resonance (MR) imaging has proved to be of great diagnostic value in this area. Primary extramedullary plasmacytoma in the head and neck is rare, but therapeutic consequences necessitate accurate diagnosis. Criteria for the diagnosis of primary extramedullary plasmacytoma include differentiated plasma cells (according to the Kiel classification) in the pathologic specimen (Fig 1), immunohistologic proof of monoclonal k-chains or l-chains, and negative results of a bone marrow biopsy. Furthermore, an inconspicuous plasma electrophoresis, the absence of Bence-Jones proteins in urine, as well as the absence of anemia, osteolysis in radiologic and scintigraphic staging, or of any other signs of generalization within a period of 1 year must be shown.

The goal of this study was to define characteristics that could enable primary diagnosis of extramedullary plasmacytoma with MR imaging.

Materials and Methods

A retrospective analysis of 2600 patients examined during a period of 10 years in routine clinical protocols yielded six patients with primary extramedullary plasmacytoma of the head and neck region by a review of medical records. In two patients with intraoral lesions, the histologic diagnosis had already been established with biopsy; the other four patients were examined preoperatively and underwent excisional biopsy afterward.

In three patients, the plasmacytoma was found in the nasopharynx and the parapharyngeal space; other locations included the tonsillar area, the base of the tongue, and the neck. The age of the patients ranged from 15 to 75 years. All patients were male. Dysphagia was the leading clinical symptom among patients with oropharyngeal and parapharyngeal lesions; the patient with involvement of the neck felt a progressive swelling. None of the patients

Received September 22, 1995; accepted after revision January 29, 1996.

From the Department of Radiology, Humboldt-University, Berlin (T.J.V., W.S., J.B., M.M., R.F.), and the Department of Otorhinolaryngology, Ludwig-Maximilians-University of Munich (G.G.), Germany.

Address reprint requests to Prof Dr Thomas J. Vogl, Humboldt-University, Berlin, Clinic Rudolf Virchow, Augustenburger Platz 1, 13353 Berlin, Germany.

AJNR 17:1349–1354, Aug 1996 0195-6108/96/1707–1349
© American Society of Neuroradiology

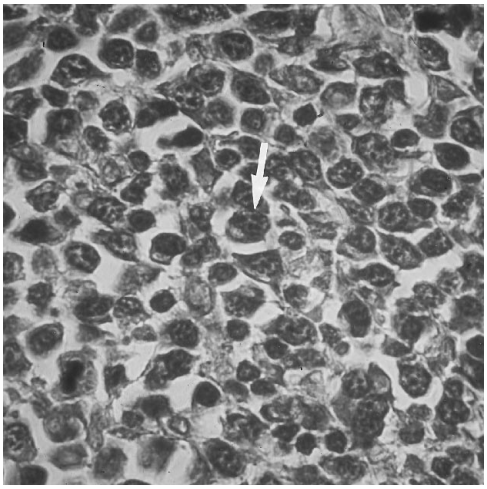

Fig 1. Differentiated plasma cells. Note the characteristic clockface nucleus of the plasma cells with perinuclear halo (*arrow*) (Giemsa stain, magnification × 400).

had anemia, Bence-Jones proteinuria, or other signs of myeloma at the time of MR examination. Three patients who underwent primary radiation therapy were examined several times during a 3-month follow-up period to monitor effectiveness of therapy. Thus, one patient reached a follow-up period of 18 months; the other two patients of more than a year.

MR imaging was performed on a 1.5-T Magnetom unit equipped with either a head coil or a Helmholtz neck coil, depending on the location of the tumor. Axial T2-weighted (3000/25,90 [repetition time/echo time]) and T1-weighted (500/17) spin-echo sequences were obtained for all patients. After intravenous administration of gadopentetate dimeglumine (0.1 mmol/kg body weight), additional T1-weighted sequences in axial, coronal, and sagittal planes followed. The signal intensities of the lesions were measured using a region-of-interest technique before and after administration of contrast material; the percentage of enhancement was calculated with the following formula:

$$\text{Percentage of enhancement} = \frac{SI_{enhanced} - SI_{plain}}{SI_{plain}} \times 100.$$

Results

Growth Pattern

In five cases the extramedullary plasmacytoma was oval and well-marginated without any evidence of infiltration; the other lesion filled the parapharyngeal space bilaterally. Surrounding soft tissues were greatly displaced by the lesion, presumably an indication of slow growth rate. Four tumors had a distinctly inhomogeneous internal structure with no apparent central necrosis and with homogeneous morphology in the periphery. Tumors of the oropharynx and the neck narrowed the pharyngeal or laryngeal airway (Fig 2); the nasal cavity lesion filled the space and displaced the maxillary sinus wall on one side (Fig 3). In four patients, lymph nodes were seen in the adjacent regions of drainage; however, they measured less than 1 cm in diameter and showed no evidence of malignant infiltration.

Signal Intensities

On the T2-weighted sequences, the tumors showed an intermediate signal intensity (Fig 4). On plain T1-weighted sequences, the lesions appeared isointense or slightly hyperintense with respect to the surrounding muscles and could therefore not be delineated from them clearly. After administration of contrast material, the tumors showed notable enhancement in the peripheral zones and intermediate central enhancement; in four cases, distinct areas of inhomogeneity were seen in the center of the lesions. A primary diagnosis based only on the MR imaging findings was not possible in any case. The differential diagnosis included lymphoma, adenoma and adenocarcinoma, schwannoma, and nonmelanotic melanoma. Furthermore, mesenchymal processes such as fibroma, rhabdomyoma, hemangiopericytoma, and a chondroid lesion in the nasal area were considered.

Follow-up Examinations

Follow-up MR examinations during radiation therapy (performed in three patients) clearly revealed a reduction in tumor size. The mass was reduced symmetrically without change in morphology. MR imaging enabled sufficient differentiation between tumor, scar, and inflammatory or edematous reactions due to different signal intensities on T2-weighted sequences and certain patterns of contrast enhancement. Tumor margins could be detected in all cases. In no patient had the tumor disappeared.

Discussion

Generalized multiple myeloma is typically verified by microscopic findings of plasma cells on bone marrow biopsy specimens, by immunohistologic proof of monoclonal immunoglobulins, and by monoclonal paraproteinemia.

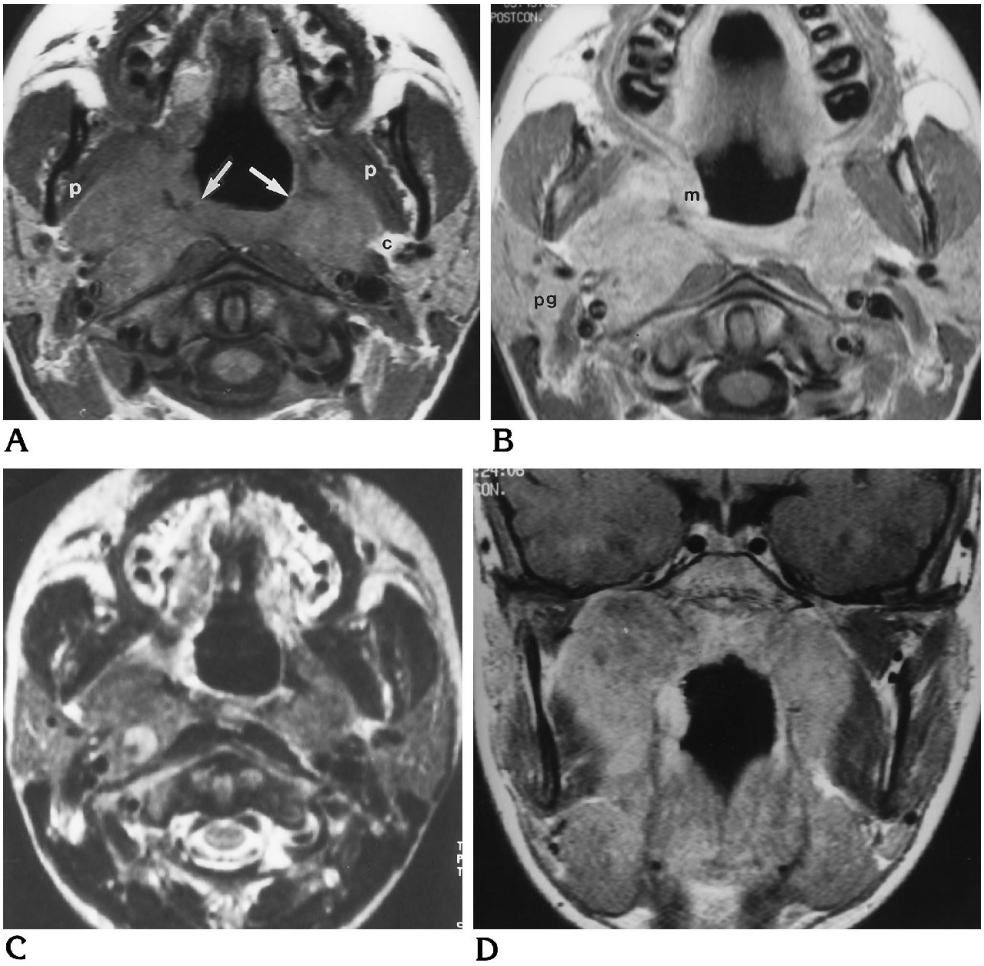

Fig 2. Case 6: primary extramedullary plasmacytoma in the oropharynx with bilateral involvement of the parapharyngeal space.

A, Unenhanced T1-weighted (500/17) spin-echo sequence shows a mass in the submucosal region of the oropharynx extending into the prestyloid and poststyloid parapharyngeal and retropharyngeal spaces with intermediate signal intensity (*arrows*). The medial pterygoid muscle (*p*) is compressed and displaced anterolaterally. The lateral vessel compartment is displaced posterolaterally. The fatty tissue of the prestyloid compartment (*c*) of the parapharyngeal space can be identified.

B, Contrast-enhanced T1-weighted spin-echo sequence shows homogeneous contrast enhancement; the tumor can be clearly delineated from adjacent structures, such as the parotid glands (*pg*). Note the enhancement of the thickened mucosa (*m*) outlining the oropharyngeal cavity.

C, T2-weighted (3000/90) sequence shows intermediate signal intensity, similar to the signal of the adjoining parotid glands.

D, Coronal T1-weighted spin-echo image shows the tumor extending to skull base structures while narrowing the oropharynx considerably. In the right portion of the tumor, some central inhomogeneities are apparent.

Furthermore, osteolytic bony lesions are seen in multiple myeloma (1). In contrast, primary extramedullary plasmacytoma may present with such clinical symptoms as swelling, dyspnea, dysphagia, or epistaxis. Immunologically, only monoclonal k-chains or l-chains are found. Serum electrophoresis is often inconclusive, owing to the relatively small size of the tumor. In contrast to multiple myeloma, in which IgG immunoglobulin is prevalent, extramedullary plasmacytoma is associated with increased IgA (2–4).

The frequency of occurrence of primary extramedullary plasmacytoma in relation to myeloma is 1 to 40. Men are affected four times more frequently than women, usually between the ages of 40 and 70 years; nevertheless, one of our patients was a 15-year-old boy. Some authors consider extramedullary plasmacytoma to be a unique disease (5) while others regard it as a variation of plasmacytoma (6, 7). Approximately 80% of all extramedullary plasmacytomas occur in the head and neck area: in

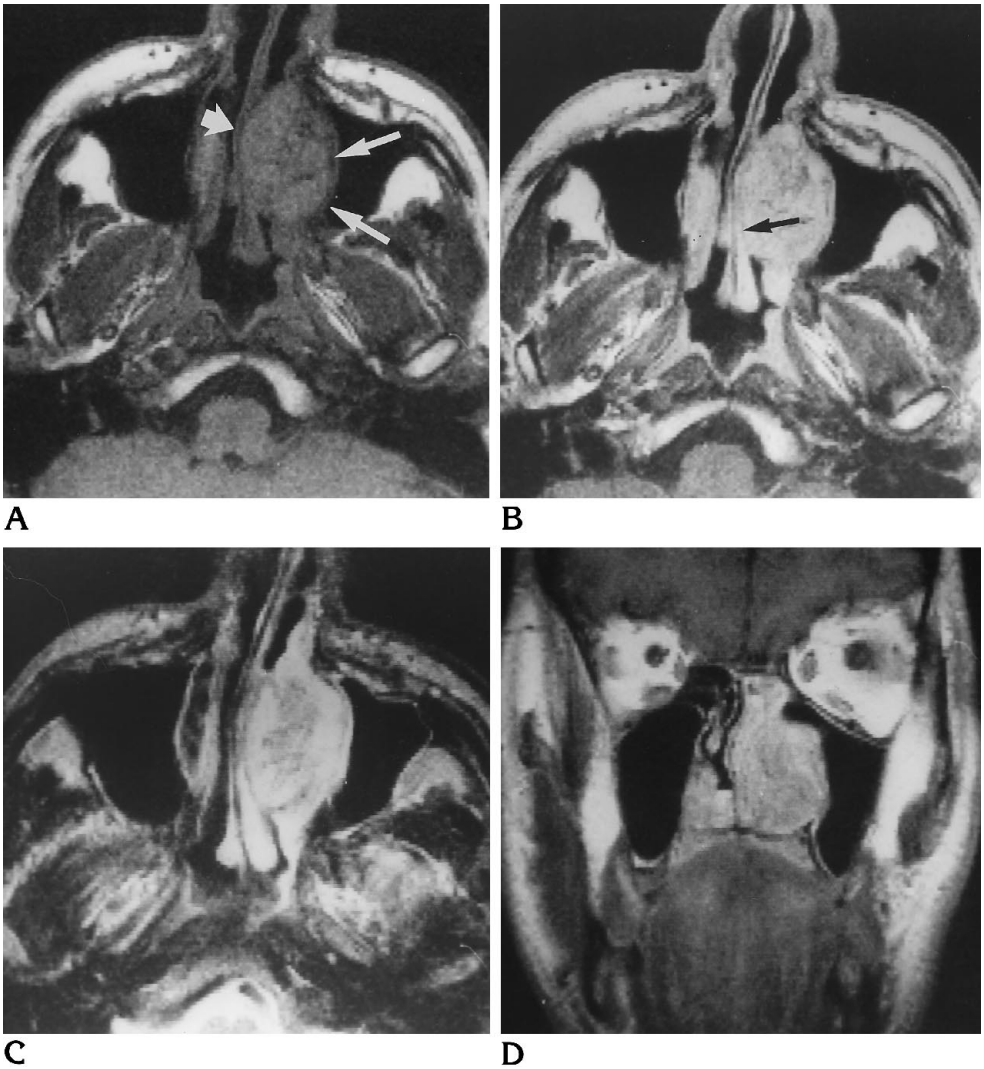

Fig 3. Case 2: primary extramedullary plasmacytoma in the nasal cavity.

A, Unenhanced T1-weighted (500/17) spin-echo sequence shows a homogeneous lesion (*long arrows*) with distinct margins involving the left nasal cavity and the turbinates, displacing the nasal septum (*short arrow*) and the left maxillary sinus wall.

B, Contrast-enhanced T1-weighted sequence at the same position shows the high contrast uptake of the lesion, which can be clearly distinguished from the nasal mucosa (*arrow*).

C, On this T2-weighted (3000/90) image, the central inhomogeneity of the tumor becomes apparent.

D, Coronal contrast-enhanced T1-weighted spin-echo sequence shows tumor with homogeneous enhancement and without signs of infiltration. No inflammatory changes in the maxillary sinuses were apparent.

declining frequency, they are found in the nose and paranasal sinus, nasopharynx, and the tonsillar area (6). We also found a predilection in areas of lymphatic tissue with intranodal and extranodal involvement among our cases. However, owing to the paucity of documented cases, it cannot be stated unequivocally that extramedullary plasmacytoma does not occur outside the head and neck area.

In addition to numerous other tumorous lesions, inflammatory and reactive lymphatic tissue and granulation tissue must be ruled out in these regions (8–10). The diagnosis of solitary extramedullary plasmacytoma is a crucial one, as completely different therapeutic options result (11). A resectable primary extramedullary plasmacytoma is treated with surgery and postoperative radiation. If the tumor is too large or the general condition of the patient obviates surgery, primary radiation to a total dose of 60 Gy should be used. Tumor and local lymph nodes should be irradiated whether or not they

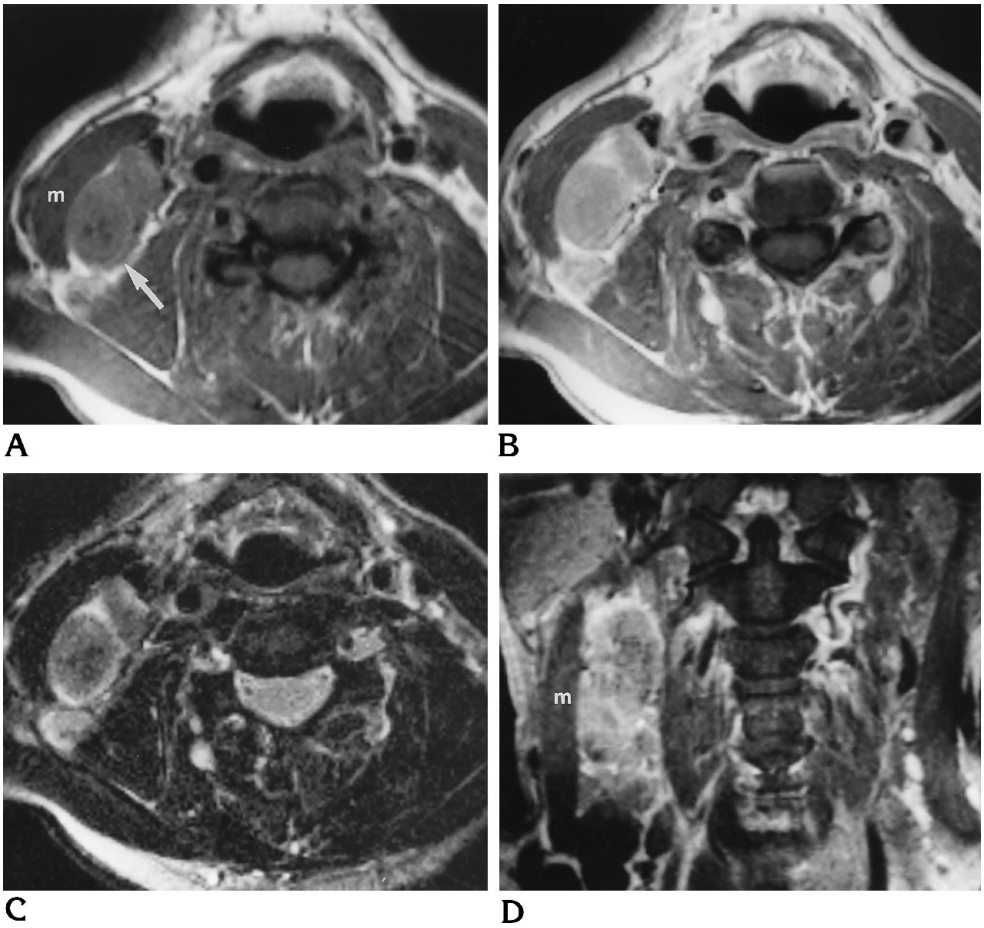

Fig 4. Case 4: primary extramedullary plasmacytoma of the neck at the level of the piriform sinus.

A, Unenhanced T1-weighted (500/17) spin-echo sequence shows an oval lesion (*arrow*) posterior to the right internal jugular vein and medial to the sternocleidomastoid muscle (*m*).

B, On the contrast-enhanced T1-weighted (500/17) sequence, three tumors can be clearly distinguished from one another. There is homogeneous enhancement with distinct margins.

C, T2-weighted (3000/90) spin-echo sequence shows moderate signal intensity. Note the inhomogeneous central signal intensities.

D, Coronal T1-weighted spin-echo sequence reveals the degree of craniocaudal extension with displacement of the right sternocleidomastoid muscle (*m*).

are conspicuous at clinical examination or on imaging studies. Chemotherapy (melphalan and cyclophosphamide, corticosteroids) (7) and combined radiation/chemotherapy regimens (11) have shown promise.

Clinical observations include both complete remission over a 20-year period and generalization of the disease. In the latter cases, it remains unclear whether the extramedullary plasmacytoma was the first manifestation of myeloma or whether it represented metastasis from such a primary lesion. Furthermore, death caused by continuing local growth is possible. Provided that treatment is adequate, patients with primary extramedullary plasmacytoma have a much better prognosis than do patients with multiple myeloma (5); survival rates can range from 53% to 75% per year (12).

MR imaging offers several advantages over conventional imaging methods, such as high soft-tissue contrast and multiplanar imaging, without exposing the patient to ionizing radiation (13–15). Several characteristics of primary plasmacytoma in the head and neck area can be identified. Although morphologic features or evidence of contrast enhancement do not assure certain diagnosis of extramedullary plasmacytoma, these MR imaging characteristics

offer crucial information that allows the radiologist to include this rare lesion in the differential diagnosis. MR imaging is excellent for use in follow-up examinations during therapy, as it allows verification of reduction in tumor size (16, 17). However, clinical/serologic and radiographic follow-up are mandatory for ruling out generalized multiple myeloma.

References

1. Linden A, Gückel C, Widder R, Jungehülsing M, Diehl V, Schicha H. Kernspintomographie beim Plasmozytom. *Fortschr Rontgenstr* 1992;156,1:83–88
2. Abemayor E, Canalis RF, Greenberg P, Worthan DG, Rowland JP. Plasma cell tumours of the head and neck. *J Otolaryngol* 1988; 17:376–381
3. Corwin J, Lindberg RD. Solitary plasmacytoma of bone vs. extramedullary plasmacytoma and their relationship to multiple myeloma. *Cancer* 1979;42:1007–1013
4. Woodruff RK, Whittle JM, Malpas JS. Solitary plasmacytoma, I: extramedullary soft tissue plasmacytoma. *Cancer* 1979; 43:2340–2343
5. Wiltshaw E. The natural history of extramedullary plasmacytoma and its relation to solitary myeloma of bone and myelomatosis. *Medicine* 1976;55:217–238
6. Batsakis JG, Freis GT, Goldman RT, Karlsberg RC. Upper respiratory tract plasmacytoma. *Arch Otolaryngol* 1964;79:613–618
7. Kapadia SB, Uma Desai BS, Cheng VS. Extramedullary plasmacytoma of the head and neck. *Medicine* 1982;61:317–329
8. Castro EB, Lewis JS, Strong EW. Plasmacytoma of paranasal sinuses and nasal cavity. *Arch Otolaryngol* 1973;97:326–329
9. Dolin S, Dewar JP. Extramedullary plasmacytoma. *Am J Pathol* 1965;32:83–103
10. Kautzky M, Susani M, Steurer M, Youssefzadeh S. Plasmozytom der Nase und der Nasennebenhöhlen mit intrakranieller und orbitaler Ausdehnung. *LaryngorhinoOtologie* 1993;72:352–355
11. Mill WB, Griffith R. The role of radiation therapy in the management of plasma cell tumors. *Cancer* 1980;45:647–652
12. Fu YS, Perzin KH. Nonepithelial tumors of the nasal cavity, paranasal sinuses and nasopharynx: a clinicopathologic study, IX: plasmacytomas. *Cancer* 1978;42:2399–2406
13. Glazer HS, Niemeyer JH, Balfe DM, et al. Neck neoplasmas: MR imaging, 2. *Radiology* 1986;160:349–354
14. Lufkin RB, Hanafee WN. MRI of the head and neck. *Magn Reson Imaging* 1988;6:69–88
15. Stark D, Moss A, Gamsu G, Clark OH, Gooding GAW, Webb WR. Magnetic resonance imaging of the neck, 1. *Radiology* 1984;150: 447–454
16. Van den Brekel MWM, Stel HV, Castelijns JA, et al. Cervical lymph node metastasis: assessment of radiologic criteria. *Radiology* 1990;177:379–384
17. Hasso AN, Brown KD. Use of gadolinium chelates in MR imaging of lesions of the extracranial head and neck. *J Magn Reson Imaging* 1993;3:247–263