

**Are your MRI contrast agents cost-effective?**

Learn more about generic Gadolinium-Based Contrast Agents.



**FRESENIUS  
KABI**

caring for life

**AJNR**

This information is current as  
of April 17, 2024.

**Identification of the feeding arteries of spinal  
vascular lesions via phase-contrast MR  
angiography with three-dimensional  
acquisition and phase display.**

M Mascalchi, N Quilici, G Ferrito, S Mangiafico, F Scazzari,  
P Torselli, P Petruzzi, M Cosottini, C Tessa and C Bartolozzi

*AJNR Am J Neuroradiol* 1997, 18 (2) 351-358

<http://www.ajnr.org/content/18/2/351>

# Identification of the Feeding Arteries of Spinal Vascular Lesions via Phase-Contrast MR Angiography with Three-dimensional Acquisition and Phase Display

Mario Mascalchi, Nello Quilici, Giampiero Ferrito, Salvatore Mangiafico, Fabio Scazzari, Paolo Torselli, Pasquale Petruzzi, Mirco Cosottini, Carlo Tessa, and Carlo Bartolozzi

**PURPOSE:** To determine whether identification of the feeding arteries of spinal vascular lesions with phase-contrast MR angiography benefits from the higher spatial resolution of three-dimensional (volume) acquisitions and flow-direction information provided by the phase reconstruction of two-dimensional acquisitions. **METHODS:** Fifteen patients with high- or low-flow spinal vascular lesions proved by spinal arteriography underwent MR angiography with phase-contrast techniques. Arteriographic and MR angiographic studies were reviewed to identify the arterial feeders of spinal vascular lesions. **RESULTS:** On modulus reconstructions of coronal 2-D or 3-D acquisitions, three of four arteries feeding high-flow lesions and three of 14 arteries feeding low-flow lesions were identified as hypertrophic vessels joining the parent intercostal or cervical arteries. Of 11 intradural veins draining dural arteriovenous fistulas, three were identified on coronal 2-D acquisitions and six on coronal 3-D acquisitions as vessels that coursed from a neural foramen to a midline tangle of vessels. Phase reconstruction showed ascending and descending flow patterns in two patients with intramedullary arteriovenous malformations, and diverging flow in perimedullary veins draining a hemangioblastoma. In nine patients with dural arteriovenous fistulas, phase reconstruction provided information as to the level of the arterial feeders. Phase reconstruction in coronal plane acquisitions also provided evidence of centripetal flow. **CONCLUSION:** Three-dimensional acquisitions and phase display of 2-D acquisitions improved the visibility of arterial pedicles of spinal vascular lesions at phase-contrast MR angiography.

**Index terms:** Arteriovenous malformations, spinal; Magnetic resonance angiography; Spine, magnetic resonance

*AJNR Am J Neuroradiol* 18:351-358, February 1997

Selective spinal arteriography is the ultimate technique for use in diagnosing, classifying, and planning therapy for spinal vascular lesions (1). However, it is invasive, time consuming, expensive, and dependent on the skills of the operator. Modulus reconstruction of two-dimensional phase-contrast magnetic resonance

(MR) angiographic acquisitions in the sagittal plane is a useful and rapid complement to MR imaging for the identification of abnormal vessels within the spinal canal (2, 3). Modulus reconstruction of three-dimensional (volume) phase-contrast MR angiographic acquisitions in the coronal plane was reported to show abnormally dilated midline serpiginous vessels in a single case of dural arteriovenous fistula (4). One goal in the use of MR angiography is the identification of arterial feeders of vascular lesions of the spine. Such an identification may direct the selective spinal arteriographic examination to specific spinal levels, thus shortening catheterization time. In a previous study (3), modulus reconstruction of 2-D phase-contrast MR angiographic acquisitions in the coronal

---

Received April 23, 1996; accepted after revision August 14.

From the Cattedra di Radiologia, Università di Pisa (M.M., P.T., P.P., M.C., C.T., C.B.); the Department of Neuroradiology, Ospedali Riuniti, Livorno (N.Q., G.F., F.S.); and the Department of Neuroradiology, Ospedale Careggi, Firenze (S.M.); Italy.

Address reprint requests to Mario Mascalchi MD, PhD, Cattedra di Radiologia, Università di Pisa, Via Roma 67 56100, Pisa, Italy.

*AJNR* 18:351-358, Feb 1997 0195-6108/97/1802-0351

© American Society of Neuroradiology

plane provided evidence of arterial feeders of high-flow malformations, including intramedullary arteriovenous malformations (AVMs) and perimedullary arteriovenous fistulas (AVFs), whereas it often failed to show the source of low-flow dural AVFs, which are the most common vascular lesions in adults or elderly persons (5).

We investigated whether the identification of feeding arteries of spinal vascular lesions via phase-contrast MR angiography benefits from the higher spatial resolution of 3-D (volume) acquisition (6) and flow-direction information provided by phase reconstruction of 2-D acquisitions.

## Materials and Methods

From September 1994 to March 1996, 15 patients (seven women and eight men; 21 to 84 years old) with native ( $n = 12$ ), residual ( $n = 1$ ), or recurrent ( $n = 2$ ) spinal vascular lesions proved by arteriography were examined with the use of either a 1.5-T ( $n = 12$ ) or a 0.5-T ( $n = 3$ ) MR imaging unit. Selective spinal arteriographic diagnoses included intramedullary AVMs ( $n = 2$ ), high-flow perimedullary AVF ( $n = 1$ ), dural AVFs ( $n = 11$ ), and hemangioblastoma ( $n = 1$ ). All patients previously had enhanced MR imaging at different centers on 0.5-T or 1.5-T systems.

MR angiography included sagittal 5-mm-thick T1-weighted spin-echo sequences (360–500/20–25/2–4 [repetition time/echo time/excitations]) with a 25-cm field of view and a  $160 \times 224$  matrix. Since paramagnetic contrast agents reduce the effects of spin saturation in phase-contrast MR angiography, thereby enabling visualization of small low-flow vessels and improving the intravascular signal/background noise ratio (7), most ( $n = 13$ ) of our examinations were performed after intravenous bolus injection of (0.3 mmol/kg) gadopentetate dimeglumine. Single-section 2-D phase-contrast MR angiography was then performed in the midsagittal plane with a gradient-recalled echo sequence (38/11/8–12 with a flip angle of  $30^\circ$ ) incorporating bipolar flow-encoding gradients. Amplitude and duration of the bipolar gradients were set to optimally detect velocity of 20 to 30 cm/s in high-flow malformations and 6 to 10 cm/s in low-flow malformations (3). Three acquisitions with bipolar gradients encoding flow along superoinferior, anteroposterior, and left-right body axes were acquired. Section thickness was 15 mm with a 25-cm field of view and a  $160 \times 224$  matrix. Anterior presaturation slabs, 80- to 120-mm thick, were used for thoracolumbar spinal MR angiographic examinations.

Coronal 2-D (38/11/8–12 with a flip angle of  $20^\circ$  to  $30^\circ$ ) and 3-D (29/11/1–2 with a flip angle of  $20^\circ$  to  $30^\circ$ ) phase-contrast MR angiograms were then obtained with single 15-mm-thick sections and 28 to 60 sections 1 to 1.5 mm thick. Coronal acquisitions were centered on the ab-

normal intraspinal vessels detected on sagittal 2-D phase-contrast images. No spatial presaturation was used for coronal acquisitions. Flow was encoded along the superoinferior, anteroposterior, and left-right axes with amplitude and duration of flow-encoding gradients identical to those used for sagittal 2-D MR angiography.

In all phase-contrast acquisitions, first-order flow compensation was used; projection dephasing gradients were not used. Total examination time was less than 1 hour for all patients. Phase-contrast MR angiograms were reconstructed using complex-difference or phase-difference techniques (7). The resulting superoinferior, anteroposterior, and left-right flow modulus images were then combined in a total flow modulus image. This phase-difference technique also provides phase images in which flow along each encoded axis is displayed as black or white according to its direction, whereas background stationary tissues are gray. In our MR systems, superoinferior flow is displayed as white and inferosuperior flow as black, anteroposterior flow is white and posteroanterior flow is black; right-left and left-right flow appears white and black. All 3-D coronal phase-contrast acquisitions were reconstructed using the complex-difference technique and the maximum-intensity projection (MIP) algorithm. Sagittal ( $n = 12$ ) and coronal ( $n = 9$ ) 2-D acquisitions were reconstructed with the phase-difference technique in 12 patients and with the complex-difference technique in three patients. Hard copies of selective spinal arteriograms and MR angiograms were reviewed jointly by two observers to try to identify the arterial feeders of spinal vascular malformations.

## Results

Abnormal vessels within the spinal canal were demonstrated by sagittal 2-D MR angiography in all patients. On corresponding unenhanced or enhanced MR images, the abnormal vessels were identified in 11 patients (Figs 1–5), whereas they were barely detectable in four patients with dural AVFs.

The Table provides a summary of the results of attempts to identify the arterial feeders of the spinal vascular lesions on phase-contrast MR angiograms. On the total flow modulus images of coronal 3-D acquisitions, three of four feeding arteries in three patients with high-flow vascular malformations were identified as hairpin, S-shaped, or short hypertrophic vessels joining the intercostal ( $n = 2$ ) or cervical ( $n = 1$ ) parent arteries (Figs 1 and 2). Total flow modulus reconstruction images of coronal 2-D acquisitions in three patients showed only two arterial feeders, with lesser conspicuity and sharpness (Fig 2). One feeder of a high-flow perimedullary AVF was missed on both 2-D and 3-D acquisitions (Fig 1).

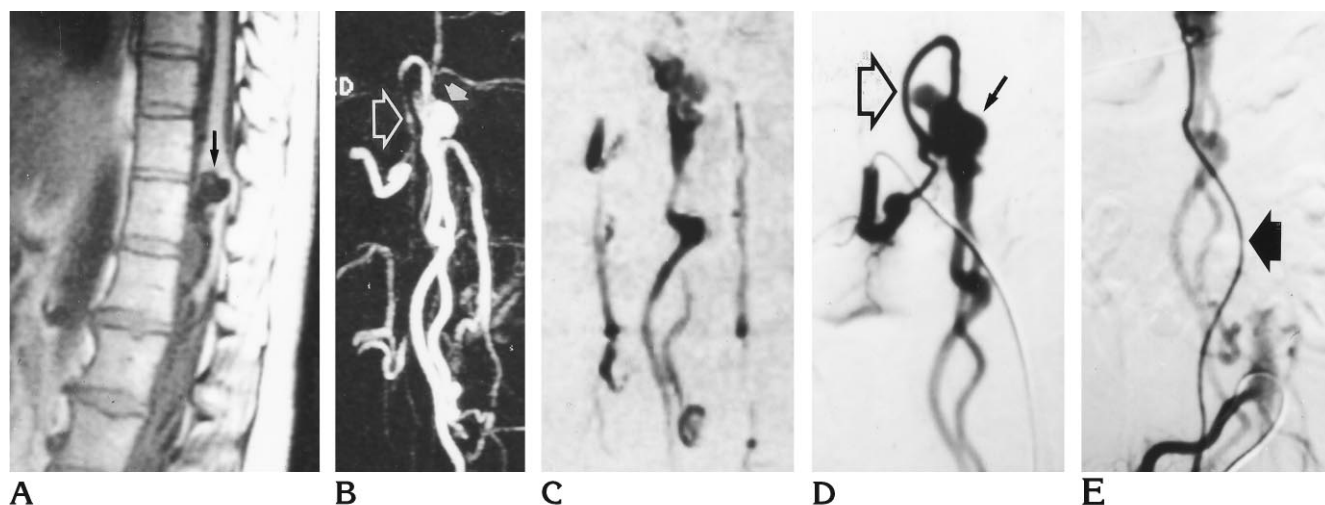


Fig 1. Perimedullary AVF.

A, Unenhanced sagittal T1-weighted (400/20/2) MR image shows large round area of signal void (arrow) displacing and deforming the conus medullaris.

B, Modulus reconstruction of contrast-enhanced 3-D phase-contrast MR angiogram (29/11/1, 20° flip angle) with velocity encoding of 30 cm/s in the coronal plane shows an S-shaped vessel (open arrow) joining a varix (solid arrow) from above.

C, The feeding artery is not seen on this modulus reconstruction of enhanced 2-D phase-contrast MR angiogram (38/11/10, 20° flip angle) with velocity encoding of 30 cm/s in the coronal plane.

D, Selective spinal arteriogram (frontal projection) with catheterization of right L-1 artery shows the arterial feeder (open arrow) joining a large venous pouch (solid arrow) without an intervening nidus, and is consistent with high-flow perimedullary fistula.

E, Selective spinal arteriogram with catheterization of right L-4 artery shows an additional ascending feeder (arrow) missed on B and C.

On total flow modulus reconstruction images of coronal 2-D or 3-D acquisitions, only three of 14 feeding arteries from low-flow vascular lesions were identified (Figs 3 and 4).

Of 11 single intradural veins draining dural AVFs, three were identified on coronal 2-D and 3-D acquisitions as large vessels that coursed from the region of a neural foramen to the midline tangle of serpiginous vessels. In three patients, tiny vessels approaching the midline tangles were barely seen on the 3-D acquisitions (Fig 5) and were missed on the 2-D acquisitions.

On coronal modulus 2-D or 3-D images, prevertebral or retrovertebral vessels that were inadvertently included in the section or volume of interest could have been misinterpreted as feeding arteries (Fig 3) when they approached or crossed the midline tangle of abnormal vessels; however, axial reconstructions of the 3-D data set using the MIP algorithm helped to avoid such pitfalls. Targeted MIPs in the coronal plane of 3-D acquisitions more clearly showed arterial feeders or intradural draining veins than did MIP reconstructions of the whole data set, but in no case did they reveal vessels undetected in the latter.

Phase reconstruction of superoinferior flow in sagittal or coronal 2-D acquisitions showed ascending and descending flow patterns in two patients with intramedullary AVMs and diverging flow in the perimedullary veins draining the hemangioblastoma (Figs 2 and 3). In nine patients with dural AVFs, phase reconstruction of the superoinferior flow provided an indirect clue as to the level of the arterial feeders by showing diverging ( $n = 4$ ), ascending ( $n = 3$ ), or descending ( $n = 2$ ) flow direction in the perimedullary plexus (Fig 5). The point of divergence corresponded to the anastomosis between the medullary vein draining the fistula and the perimedullary venous plexus. This point was always located within two levels of the arterial feeder. Phase reconstruction of the superoinferior flow direction in the dilated perimedullary vessels constituted the only clue as to the level of the arterial feeder in four patients with dural fistula whose intradural draining vein was missed on coronal 2-D or 3-D modulus reconstructions.

Phase images of left-right flow in the coronal plane provided evidence of centripetal flow, that is, from outside to inside the spinal canal, in the case of the feeding arteries of high-flow lesions ( $n = 2$ ) (Fig 2) and intradural veins draining

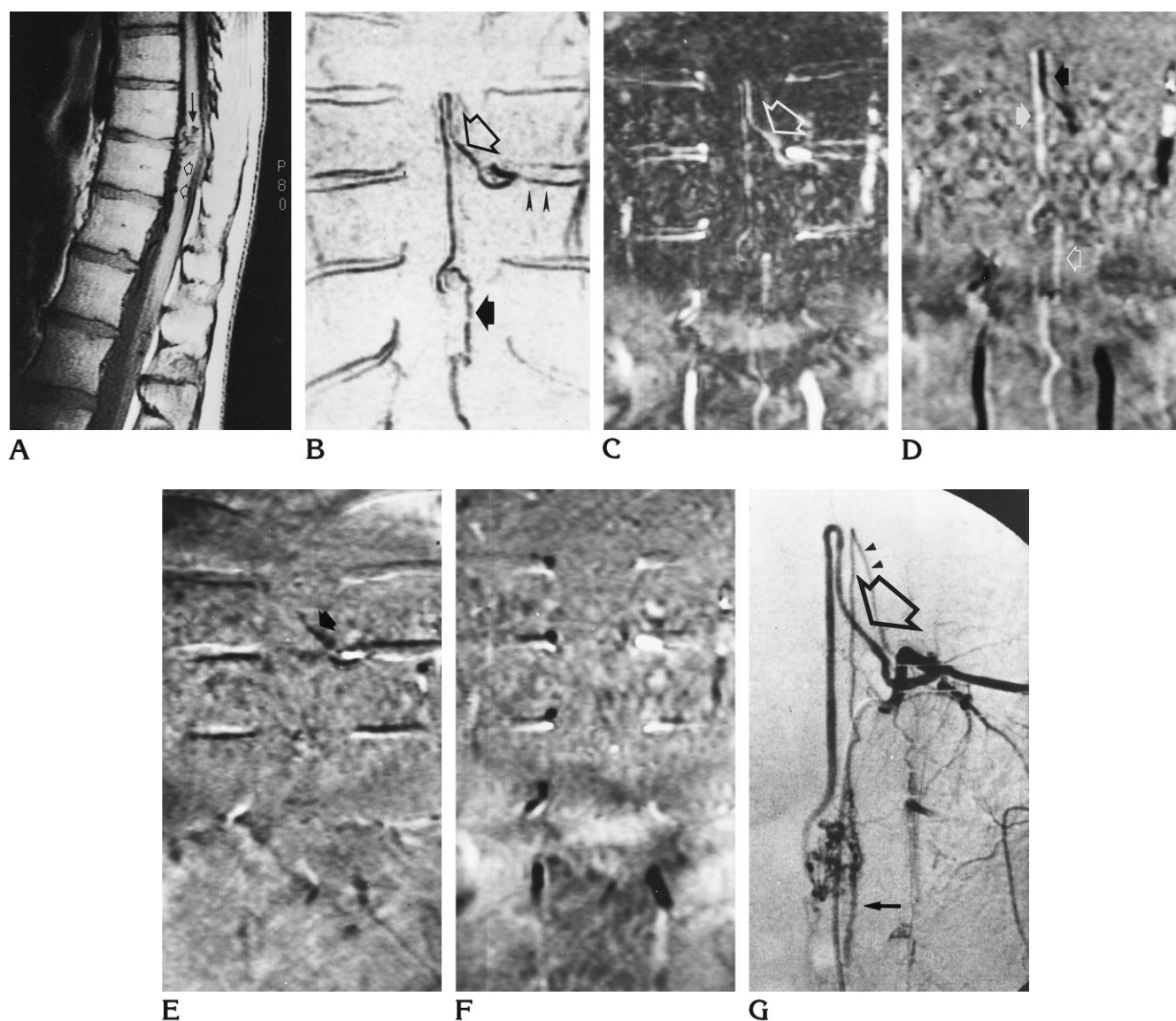


Fig 2. Intramedullary AVM partially occluded by glue embolization 1 year before present MR examination.

A, Unenhanced sagittal T1-weighted (360/20/2) MR image shows tiny areas of signal void within (solid arrow) and in front of (open arrows) the spinal cord.

B Modulus reconstruction of contrast-enhanced 3-D phase-contrast MR angiogram (29/11/1, 20° flip angle) with velocity encoding of 20 cm/s in the coronal plane shows the feeder (open arrow), which arises from the left T-9 intercostal artery (arrowheads) and joins the partially occluded nidus and the descending draining vein (solid arrow).

C, In modulus reconstruction of enhanced 2-D phase-contrast MR angiogram (38/11/10, 20° flip angle) with velocity encoding of 20 cm/s in the coronal plane, the arterial feeder is visible (arrow) but the abnormal intraspinal vessels are less sharply defined.

D, Phase reconstruction of C shows ascending (solid black arrow) and descending (solid white arrow) superoinferior flow in the proximal and distal portions of the feeding artery, and descending flow (open white arrow) in the draining vein.

E, Reconstruction of C shows left-to-right flow in the proximal portion of the arterial feeder (arrow).

F, Phase reconstruction of C shows anteroposterior flow is noncontributory.

G, Selective spinal arteriogram (anteroposterior projection) with catheterization of left T-9 shows the arterial feeder (open arrow) nourishing the partially occluded nidus and the descending vein (solid arrow). Note artery of Adamkiewicz (arrowheads), which was missed on all phase-contrast MR angiographic acquisitions.

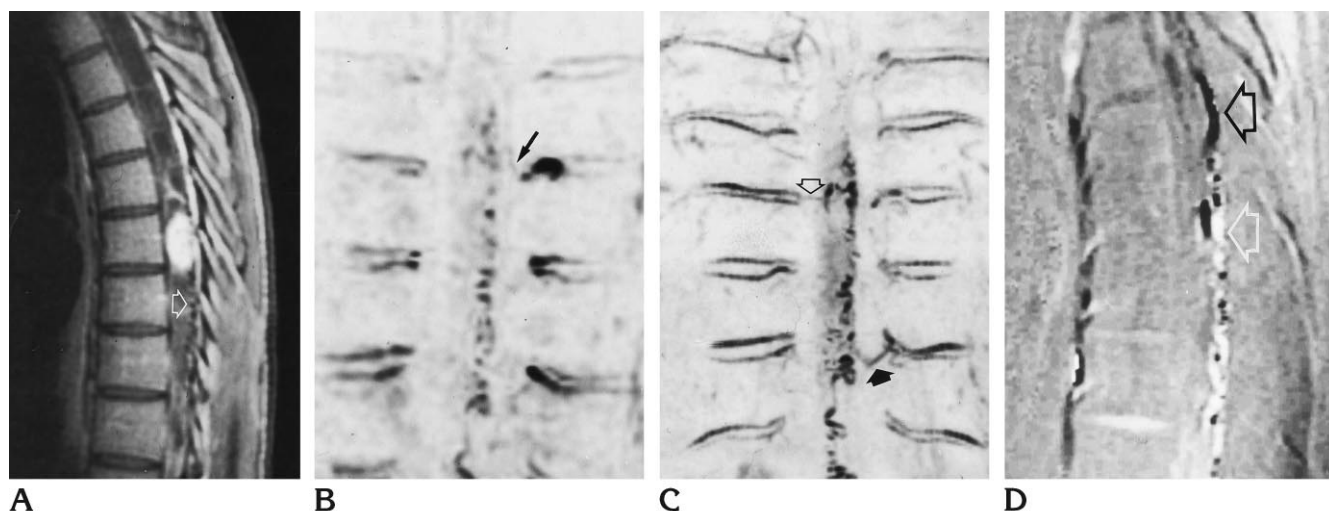


Fig 3. Intramedullary hemangioblastoma.

A, Contrast-enhanced sagittal T1-weighted (360/20/2) MR image shows intramedullary nodule within an extensive septated syrinx. Tiny retromedullary areas of signal voids (*arrow*) are seen below the lesion.

B, Modulus reconstruction of contrast-enhanced 2-D phase-contrast MR angiogram (38/11/12, 20° flip angle) with velocity encoding of 6 cm/s in the coronal plane shows extensive tangle of serpiginous vessels joining the left T-7 vascular pedicle through a small vessel (*arrow*).

C, The abnormal vessels are defined better on this modulus reconstruction of enhanced 3-D phase-contrast MR angiogram (29/11/1, 20° flip angle) with velocity encoding of 6 cm/s in the coronal plane. No connection of the left T-7 vascular pedicle is seen, whereas vessels apparently joining the right T-7 pedicle (*open arrow*) and the left T-9 intercostal vein (*solid arrow*) are present.

D, Phase reconstruction of enhanced 2-D phase-contrast MR angiogram (38/11/12, 20° flip angle) with velocity encoding of 6 cm/s in the sagittal plane shows ascending superoinferior flow (*black arrow*) in the upper retromedullary vessels and descending flow (*white arrow*) in the lower retromedullary vessels.

dural AVFs ( $n = 1$ ) and of centrifugal flow in the case of radicular veins draining an intramedullary AVM ( $n = 1$ ). Phase images of the left-right flow in the sagittal plane and anteroposterior flow in the sagittal and coronal planes were noncontributory in helping to define the feeding arteries to the vascular lesions.

## Discussion

Identification of the arterial pedicles of intramedullary AVMs is not usually possible with MR imaging; however, the intramedullary nidus is well shown (8) and can be regarded as a rough indicator of the level of the arterial feeder. Identification of the arterial feeders of spinal perimedullary and dural AVFs is not always possible with MR imaging. Since perimedullary AVFs lack a nidus, and the nidus of dural AVFs is often microscopic, enlarged perimedullary vessels extending over a considerable length of the spinal canal are the only finding at MR imaging (5, 8, 9). This precludes any a priori identification of the arterial pedicles and leads to catheterization of many spinal vascular pedicles before the fistula is seen.

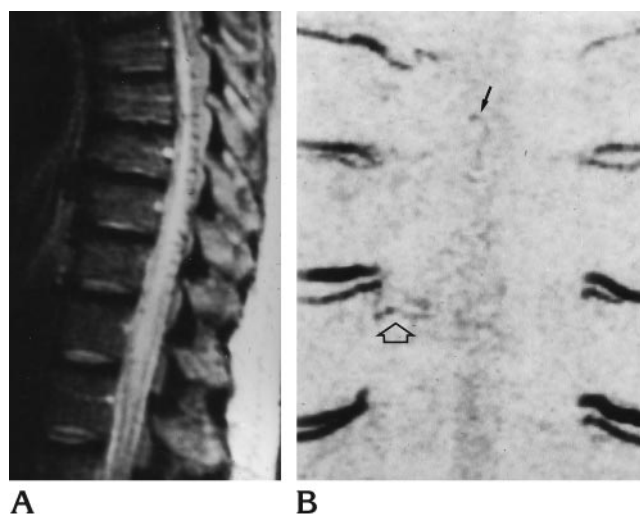


Fig 4. Dural AVF.

A, Sagittal T2-weighted (2000/100/1) spin-echo MR image shows high signal intensity in the thoracic spinal cord and conus medullaris with retromedullary serpiginous areas of signal void.

B, Modulus reconstruction of unenhanced 3-D phase-contrast MR angiogram (29/11/2, 30° flip angle) with velocity encoding of 6 cm/s in the coronal plane shows a small vessel (*open arrow*) that from the right T-7 intercostal artery courses toward faint serpiginous midline vessels (*solid arrow*). Selective spinal arteriogram with catheterization of right T-7 intercostal artery confirmed the arterial feeder of the dural fistula and the intradural draining vein (*not shown*).

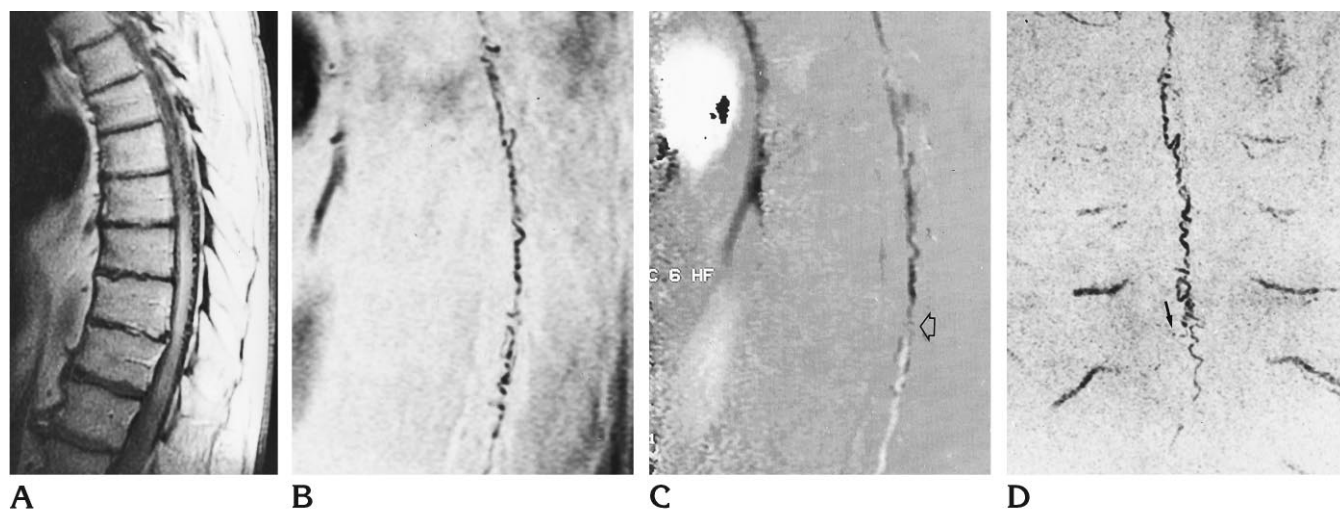


Fig 5. Dural AVF (imaged at 0.5 T).

A, Sagittal contrast-enhanced T1-weighted (400/20/4) MR image shows diffuse enhancement of the lower thoracic spinal cord and retromedullary vessels of low signal intensity.

B, Modulus reconstruction of contrast-enhanced 2-D phase-contrast MR angiogram (38/11/12, 30° flip angle) with velocity encoding of 6 cm/s in the sagittal plane shows retromedullary serpiginous vessels.

C, Phase reconstruction of B shows diverging superoinferior flow in the retromedullary vessels (arrow) at T-12.

D, On modulus reconstruction of enhanced 3-D phase-contrast MR angiogram (29/11/2, 30° flip angle) with velocity encoding of 6 cm/s in the coronal plane, a tiny vessel (arrow) in the right paramedian site at T-12 joins the midline tangle of serpiginous vessels (confirmed by selective spinal arteriography).

The distinction between high- and low-flow spinal vascular lesions is fundamental in planning phase-contrast MR angiography because the value of flow-velocity encoding needs to be chosen before the examination begins. Our study confirms that identification of arterial feeders with the use of phase-contrast MR angiography is easier in high-flow than in low-flow lesions (3). Our results indicate that modulus reconstruction of 3-D acquisitions improves detection of the arterial feeder of spinal vascular lesions as compared with modulus reconstruction of 2-D phase-contrast acquisitions, presumably because of the intrinsically poor spatial resolution of the latter. In only one of our patients was the arterial feeder identified on coronal modulus 2-D acquisitions, and it was missed on the 3-D acquisitions. Because this was a low-flow lesion (hemangioblastoma), we speculate that saturation phenomena, which are more prominent in 3-D than in 2-D acquisitions, may have accounted for this exception. The 3-D modulus acquisitions enabled us to directly or indirectly identify the arterial feeders in seven of 11 patients with dural AVFs. Our data are similar to those reported by Bowen et al (10), who identified the intradural draining vein and indirectly the source of dural AVFs in six of eight patients by using enhanced 3-D time-of-

flight MR angiography. It is noteworthy that whereas those authors were able to see the entire course of intradural draining veins, we were able to show only portions of the intradural draining vein in some of our patients (see Fig 5). We speculate that this difference presumably reflects the fact that in enhanced time-of-flight imaging, T1 shortening induced by the paramagnetic contrast agent is to some extent independent of flow. While this may create some problems in differentiating enhanced stationary tissue (10), it will considerably help to delineate very low flow vessels (11). Unenhanced and enhanced phase-contrast MR angiographic techniques rely entirely on flow to demonstrate the vessels (6, 7), and, as such, it is possible that they may not show very low flow vessels or portions of them (at least with the velocity-encoding value used in our study). The fact that, ultimately, enhanced time-of-flight imaging might seem to be more sensitive to very slow flow than is phase-contrast MR angiography supports the observations made in recent reports that normal veins anterior and posterior to the spinal cord can be seen on contrast-enhanced time-of-flight MR angiograms and MR images of the thoracolumbar spine in subjects without spinal vascular lesions at selective spinal arteriography (11, 12). These

Arterial feeders of 15 spinal vascular lesions and their identification with phase-contrast MR angiography

Case	Age, y/Sex	Selective Spinal Arteriography		Phase-Contrast MR Angiography		
		Diagnosis	Arterial Feeder	3-D Modulus Reconstruction	2-D Modulus Reconstruction	2-D Phase Reconstruction
1	49/F	Perimedullary AVF	R L-1 L-4	L-1 arterial feeder	...	...
2	24/F	Intramedullary AVM (after incomplete treatment)	L T-9	Arterial feeder	Arterial feeder	Arterial feeder
3*	21/F	Intramedullary AVM	L SIA	Arterial feeder	Arterial feeder	Arterial feeder
4	21/M	Hemangioblastoma	L T-7	...	Arterial feeder	Diverging flow in perimedullary veins
5*	34/M	Dural AVF	R T-5 T-7	Arterial feeder	...	...
6	84/F	Dural AVF (recurrence)	R T-12	Intradural draining vein	...	Ascending flow in perimedullary veins
7	73/F	Dural AVF	R L-1	Intradural draining vein	Intradural draining vein	...
8	82/F	Dural AVF	L T-9 T-11	...	...	Diverging flow in perimedullary veins
9	73/M	Dural AVF	R T-12	Intradural draining vein	Intradural draining vein	Ascending flow in perimedullary veins
10	72/M	Dural AVF	R T-12	Intradural draining vein	Intradural draining vein	Ascending flow in perimedullary veins
11	58/F	Dural AVF	R T-7	...	...	Diverging flow in perimedullary veins
12	72/M	Dural AVF	R T-12	Intradural draining vein	...	Diverging flow in perimedullary veins
13	74/M	Dural AVF	L T-9	...	...	Descending flow in perimedullary veins
14	71/M	Dural AVF	R T-5	...	...	Descending flow in perimedullary veins
15	55/M	Dural AVF	R T-8	Arterial feeder; intradural draining vein	...	Diverging flow in perimedullary veins

\* Patients who did not receive contrast administration before MRA.

Note.—AVM indicates arteriovenous malformation; AVF, arteriovenous fistula; and SIA, supreme intercostal artery.

veins correspond to the median veins and medullary or radicular veins, and may actually create some problems in determining a differential diagnosis for true vascular lesions, in particular for dural AVFs (11). By using the enhanced phase-contrast techniques described in this study, we observed normal posterior median veins in only two of 10 patients with normal arteriographic findings (personal unpublished observations). Interestingly, these two patients had spi-

nal cord astrocytoma and lupus myelitis, two conditions that can increase spinal cord blood flow.

In the present study, considerable information as to detection of arterial feeders was provided by phase reconstruction of sagittal and coronal 2-D acquisitions, which showed superior-inferior and left-right flow direction in the abnormal intraspinal vessels. This information was always indirect in the patients with dural AVFs, focusing on flow direction in the perimed-



ullary plexus, but it proved particularly valuable in the four patients in whom only dilated perimedullary slow-flow vessels were seen on 3-D modulus reconstructions.

In cases of dural AVFs, selective spinal arteriograms usually show a single ascending draining vein, which joins the perimedullary plexus on the dorsal surface of the spinal cord (1). The flow in the perimedullary plexus commonly diverges from the point of anastomosis. Since the flow in, or the caliber of, vessels cranial or caudad to the anastomosis can be asymmetric, visibility of these vessels with phase-contrast MR angiography may differ with appreciation of only ascending or descending flow, as it did in five of nine of our patients. Admittedly, some problems in the use of phase display for the identification of arterial feeders may be foreseen. In particular, the panoramic simultaneous visibility of arterial and venous structures on phase-contrast MR angiograms with lack of selectivity and temporal resolution of selective spinal arteriograms may create a problem in evaluating the entangled vascular anatomy typical of some spinal vascular lesions (see Figs 1 and 4). This may be especially true when thick sagittal or coronal 2-D sections, such as those used in the present study, are obtained. Phase reconstruction of multiple thin sections acquired with 2-D or 3-D techniques may help to improve spatial resolution and overcome these problems; but this was not done in our investigation.

Although, other approaches can be used to identify arterial feeders, including dynamic contrast-enhanced T2\*-weighted imaging (13) or MR myelography, we believe that the flow-direction information provided by phase display, possibly combined with 3-D acquisition schemes, is most specific and promising.

In conclusion, the deficient spatial resolution of currently available MR angiographic techniques renders this an inadequate substitute for careful, multiple-level, selective spinal arteriography in diagnosing and planning treatment for

spinal vascular lesions (1). However, our results indicate that 3-D acquisitions and phase display of 2-D acquisitions independently improve the visibility of arterial feeders of spinal vascular lesions at phase-contrast MR angiography. This information may have significant impact on the planning and execution of selective spinal arteriography, and possibly on its duration.

## References

1. Berenstein A, Lasjaunias P. Endovascular treatment of spine and spinal cord lesions. In: *Surgical Neuro-Angiography*. Berlin, Germany: Springer-Verlag; 1992;5:1-85
2. Gelbert F, Guichard JP, Mourier KL, et al. Phase-contrast MR angiography of vascular malformations of the spinal cord at 0.5T. *J Magn Reson Imaging* 1992;2:631-636
3. Mascalchi M, Bianchi MC, Quilici N, et al. MR angiography of spinal vascular malformations. *AJNR Am J Neuroradiol* 1995;16:289-297
4. Provenzale JM, Tien RD, Felsberg GJ, Hacıen-Bey L. Spinal dural arteriovenous fistula: demonstration using phase contrast MR angiography. *J Comput Assist Tomogr* 1994;18:811-814
5. Terwey B, Becker H, Thron AK, Vahldiek G. Gadolinium-DTPA enhanced MR imaging of spinal dural arteriovenous fistulas. *J Comput Assist Tomogr* 1989;13:30-37
6. Dumoulin CL, Hart HR Jr. Magnetic resonance angiography. *Radiology* 1986;161:717-720
7. Tu R, Kennel T, Turski P, Polzin J, Korosec F, Mistretta C. Preliminary assessment of gadodiamide-enhanced, complex difference phase-contrast magnetic resonance angiography. *Acad Radiol* 1994;S47-S55
8. Turski P, Korosec F. Technical features and emerging clinical applications of phase-contrast magnetic resonance angiography. *Neuroimaging Clin North Am* 1992;2:785-800
9. Dormont D, Gelbert F, Assouline E, et al. MR imaging of spinal cord arteriovenous malformations at 0.5T: study of 34 cases. *AJNR Am J Neuroradiol* 1988;9:833-838
10. Bowen BC, Fraser K, Kochan JP, Pattany PM, Green BA, Quencer RM. Spinal dural arteriovenous fistulas: evaluation with MR angiography. *AJNR Am J Neuroradiol* 1995;16:2029-2043
11. Bowen BC, DePrima S, Pattany PM, Marcillo A, Madsen P, Quencer RM. MR angiography of normal intradural vessels of the thoracolumbar spine. *AJNR Am J Neuroradiol* 1996;17:483-494
12. Lane JI, Koeller KK, Atkinson JDL. MR imaging of the lumbar spine: enhancement of the radicular veins. *AJR Am J Roentgenol* 1996;166:181-185
13. Thorpe JW, Kendall BE, Mac Manus DG, McDonald W, Miller D. Dynamic gadolinium enhanced MRI in the detection of spinal arteriovenous malformations. *Neuroradiology* 1994;36:522-529