

Are your **MRI contrast agents** cost-effective?

Learn more about generic **Gadolinium-Based Contrast Agents**.



**FRESENIUS
KABI**

caring for life

AJNR

**Endovascular extraction of malpositioned
fibred platinum microcoils from the
aneurysm sac during endovascular therapy.**

G H Zoarski, H M Bear, J C Clouston and J Ragheb

AJNR Am J Neuroradiol 1997, 18 (4) 691-695

<http://www.ajnr.org/content/18/4/691>

This information is current as
of April 19, 2024.

Endovascular Extraction of Malpositioned Fibered Platinum Microcoils from the Aneurysm Sac during Endovascular Therapy

Gregg H. Zoarski, Howard M. Bear, John C. Clouston, and John Ragheb

Summary: We describe two cases of coil malpositioning that occurred during endovascular occlusion of saccular basilar tip aneurysms with fibered platinum microcoils. The technique of endovascular coil extraction, accomplished successfully and without complication in both cases, is described and may be applicable to recently available controlled-detachment coil systems.

Index terms: Aneurysm, therapeutic blockade; Interventional instruments, coils

Endovascular occlusion of saccular intracranial aneurysms with fibered platinum microcoils is subject to the immediate risk of perforation of the aneurysmal dome with resultant subarachnoid hemorrhage or migration of a coil or a portion of a coil into a normal component of the circulation.

Prior to the availability of the Guglielmi detachable coil (GDC) system, we treated 15 intracranial aneurysms in 14 patients by using fibered platinum microcoils (Target Therapeutics, Fremont, Calif). In two cases, both acutely ruptured basilar tip aneurysms, coils that had partially herniated back into the normal circulation through the aneurysmal neck were extracted without complication via a commercially available microvascular retrieval device.

Case Reports

Case 1

The patient, a 50-year-old man with a history of migraine headaches, ulcerative colitis, and mild hypertension, was admitted after respiratory arrest. A computed tomographic (CT) scan showed diffuse subarachnoid hemorrhage. Hunt and Hess grade on admission was 3. An initial angiogram obtained on the day after admission

showed a questionable basilar tip abnormality (Fig 1A). A partial palsy of the left third cranial nerve that was noted on the day after admission had resolved by the sixth day of hospitalization. Findings at transcranial Doppler sonography performed on the fourth and sixth days after admission were consistent with posterior circulation vasospasm. A repeat cerebral angiogram on the seventh day of hospitalization showed a lobulated 6-mm aneurysm of the basilar tip (Fig 1B). There was no angiographic evidence of vasospasm.

Endovascular occlusion of the aneurysm with fibered platinum microcoils was performed on the 14th day after admission. Under systemic heparinization, a Tracker-18 microcatheter and Taper Flex Tip 16 guidewire (Target Therapeutics) were advanced into the basilar artery through a 6F guiding catheter that had been positioned in the distal cervical segment of the left vertebral artery via right common femoral artery access. The microcatheter was advanced into the dome of the aneurysm. An intraneurysmal angiogram obtained without complication showed a 6-mm basilar tip aneurysm. The aneurysmal dome was directed superiorly and anteriorly and had a small lateral lobulation. The filling defect within the dome of the aneurysm was presumed to represent resolving thrombus (Fig 1C). Eighteen fibered platinum microcoils were advanced through the microcatheter and into the aneurysmal lumen. The 18th coil, which was 10 mm long (5 mm × 2 mm unconstrained dimension), failed to completely enter the aneurysmal dome, herniating through the neck of the aneurysm into the left posterior cerebral artery (Fig 1D). Attempts to retrieve the coil using 2- and 4-mm angled snare devices were unsuccessful. An adjustable-size, nonangled microcatheter retrieval device was subsequently navigated into the left posterior cerebral artery. The aberrant coil was snared and removed without disruption of the coil cluster within the aneurysmal sac. There was no clinical or angiographic evidence of propagation of emboli. A postembolization angiogram showed complete occlusion of the aneurysm with bilateral patency of the posterior cerebral arteries (Fig 1E).

Received March 20, 1996; accepted after revision July 17.

Presented at the annual meeting of the American Society of Neuroradiology, Chicago, Ill, April 1995.

From the Departments of Radiology (G.H.Z., H.M.B., J.C.C.) and Neurosurgery (J.R.), University of Maryland Medical Center, Baltimore; and Alexandra Hospital, Brisbane, Australia (J.C.C.).

Address reprint requests to Gregg H. Zoarski, MD, Department of Radiology, University of Maryland Medical Center, 22 S Greene St, Baltimore, MD 21201.

AJNR 18:691-695, Apr 1997 0195-6108/97/1804-0691 © American Society of Neuroradiology

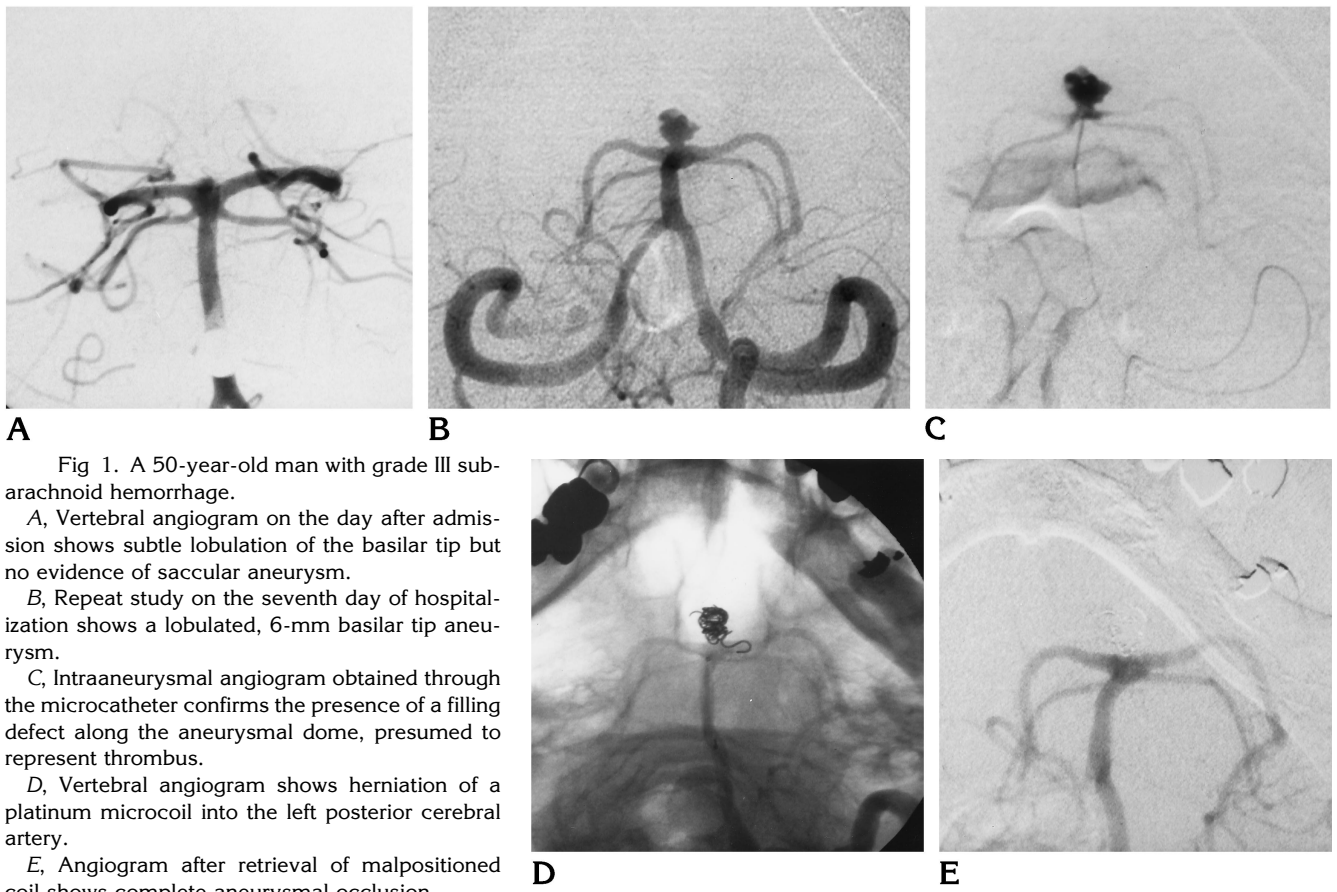


Fig 1. A 50-year-old man with grade III subarachnoid hemorrhage.

A, Vertebral angiogram on the day after admission shows subtle lobulation of the basilar tip but no evidence of saccular aneurysm.

B, Repeat study on the seventh day of hospitalization shows a lobulated, 6-mm basilar tip aneurysm.

C, Intraaneurysmal angiogram obtained through the microcatheter confirms the presence of a filling defect along the aneurysmal dome, presumed to represent thrombus.

D, Vertebral angiogram shows herniation of a platinum microcoil into the left posterior cerebral artery.

E, Angiogram after retrieval of malpositioned coil shows complete aneurysmal occlusion.

Case 2

The patient, a 41-year-old man with a history of ankylosing spondylitis, was admitted to an outside hospital with grade 1 subarachnoid hemorrhage and negative findings on a CT study. Magnetic resonance images revealed a basilar tip aneurysm. The patient was transferred to our institution for angiography and endovascular therapy.

Diagnostic angiography revealed a 5- to 6-mm basilar tip aneurysm without evidence of vasospasm (Fig 2A). The aneurysmal neck was small and distinct from the adjacent P1 segments. The dome was directed superiorly and slightly posteriorly.

A 6F guiding catheter was carefully advanced into the distal cervical segment of the left vertebral artery. A Tracker-18 microcatheter and Taper Flex Tip 16 guidewire were advanced coaxially with the patient systemically heparinized. The tip of the catheter was navigated into the aneurysmal dome using a roadmapping technique, and this position was confirmed with intraaneurysmal angiography. Ten fibered platinum microcoils were advanced into the dome of the aneurysm without complication. The proximal limb of an 11th coil (unconstrained circular diameter of 7 mm) herniated into the P1 segment of the right posterior cerebral artery (Fig 2B). Attempts to retrieve the coil using 2- and 4-mm angled snare devices were unsuccessful. The coil was subsequently snared and removed by

using a nonangled retrieval device (Fig 2C) without disruption of the endosaccular coil cluster or clinical evidence of distal emboli. Final angiograms showed near total (95%) occlusion of the basilar tip aneurysm with patency of the posterior cerebral arteries (Fig 2D). A noncontrast CT scan obtained immediately after the embolization procedure showed no evidence of subarachnoid hemorrhage.

Discussion

Endovascular occlusion of intracranial aneurysms has been performed with the use of detachable balloons (1-3), acrylic tissue adhesives (4), and cellulose acetate polymer (5, 6). Electrolytically detachable microcoils (3, 7-10) and, more recently, mechanically detachable microcoils (11, 12) have been used for aneurysmal occlusion. Use of fibered platinum microcoils for endovascular treatment of saccular aneurysms has also been described (13, 14).

Use of a microcatheter delivery system and coil device in the endovascular treatment of intracranial aneurysms carries the risk of sub-

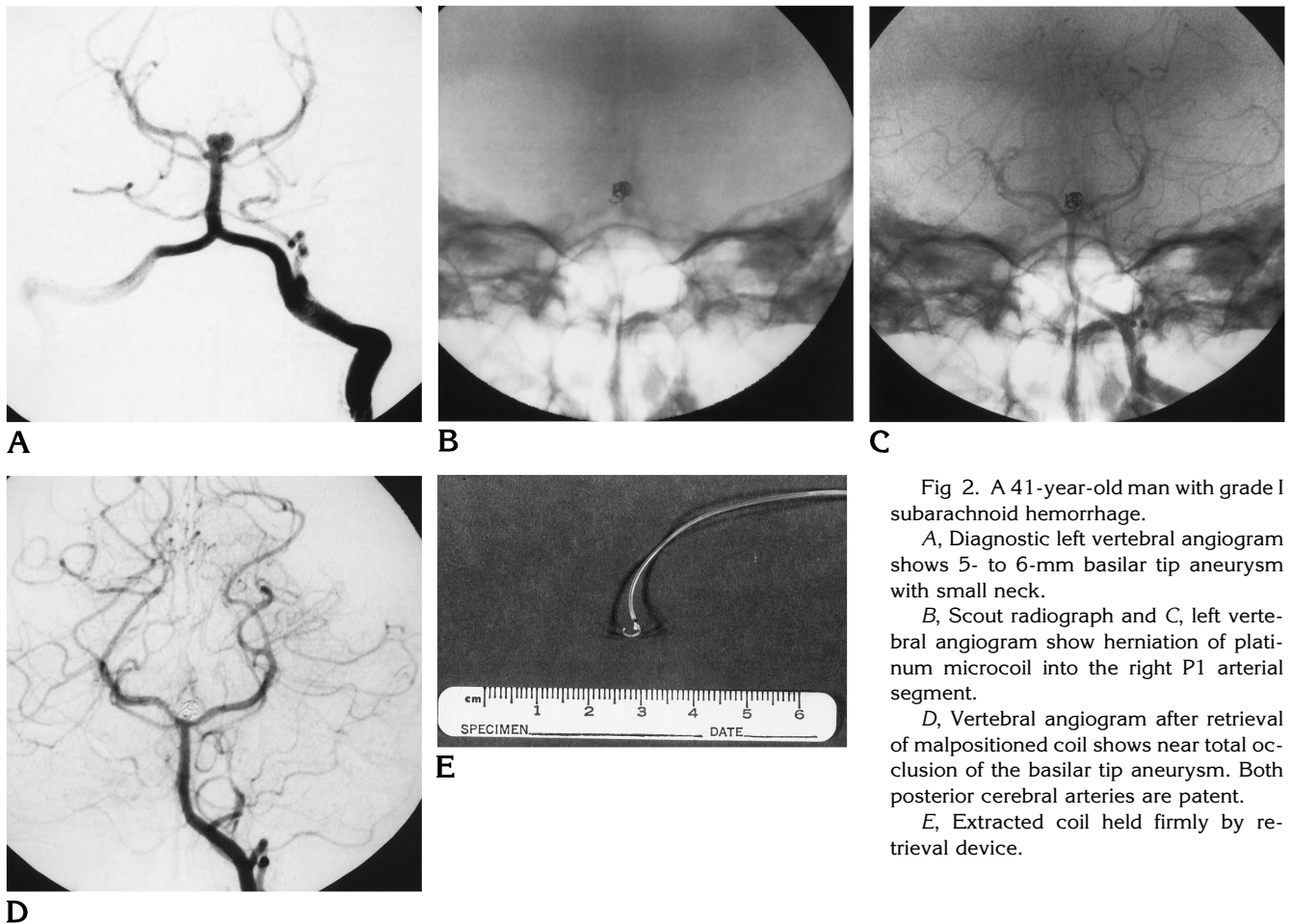


Fig 2. A 41-year-old man with grade I subarachnoid hemorrhage.

A, Diagnostic left vertebral angiogram shows 5- to 6-mm basilar tip aneurysm with small neck.

B, Scout radiograph and C, left vertebral angiogram show herniation of platinum microcoil into the right P1 arterial segment.

D, Vertebral angiogram after retrieval of malpositioned coil shows near total occlusion of the basilar tip aneurysm. Both posterior cerebral arteries are patent.

E, Extracted coil held firmly by retrieval device.

arachnoid hemorrhage caused by perforation of the aneurysmal dome either by the catheter tip or the coil system. Coil migration or malposition could also lead to occlusion of a portion of the normal circulation. While this risk may be reduced with the use of detachable systems that allow more precise placement of coils before their release into the circulation, the possibility of this complication has not yet been completely removed.

In a series of 71 patients (67% of whom had subarachnoid hemorrhage), Casasco et al (13) performed endovascular occlusion of 71 intracranial aneurysms using fibered platinum microcoils. In four cases, the parent vessel was occluded during positioning of the last coils. Two of these patients died of massive infarction and two had a moderate deficit at long-term clinical assessment (13). Poor outcome in the patients with parent vessel occlusion is compelling evidence for aggressive endovascular retrieval of malpositioned coils.

Various devices have been constructed to facilitate the retrieval of intravascular foreign bodies (15–22). In both our cases, initial attempts to retrieve the malpositioned coils were made by using Amplatz gooseneck microsnares (Microvena Corp, White Bear Lake, Minn) (Fig 3) with loop diameters of 2 mm and 4 mm, respectively. Although this snare is packaged within its own 2.3F microcatheter, the snare wire itself can be advanced through any microcatheter that allows passage of a 0.016-in diameter guidewire. The snare may thus be advanced through a microcatheter that is already positioned within the intracranial circulation. The 90° angulation of the snare loop in relation to its guiding wire theoretically facilitates the advancement of the loop over an intravascular foreign body in a perpendicular fashion. The foreign body is held firmly in place when the microcatheter is advanced up to and over the snare loop, reducing the loop's functional diameter. Alternatively, especially in retrieving larger

Fig 3. Gooseneck microsnares.

A, The wire and snare loop, although packaged within its own 2.3F microcatheter, can be advanced through any catheter that allows passage of a 0.016-in diameter guidewire. Perpendicular orientation of the snare loop with respect to the wire should facilitate removal of intravascular objects.

B, The diameter of the snare loop is reduced by withdrawing the wire into the microcatheter.

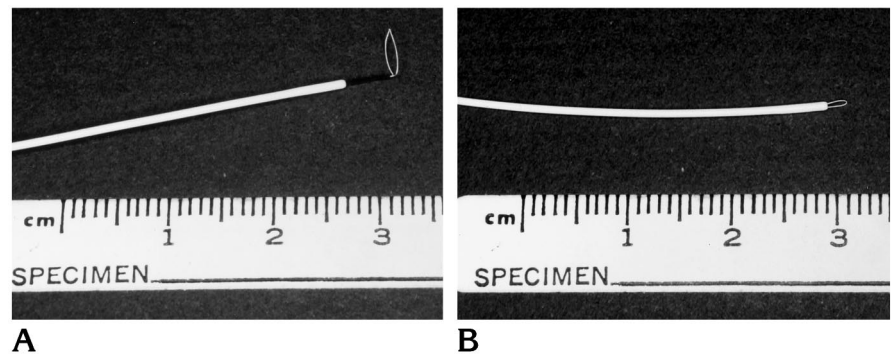
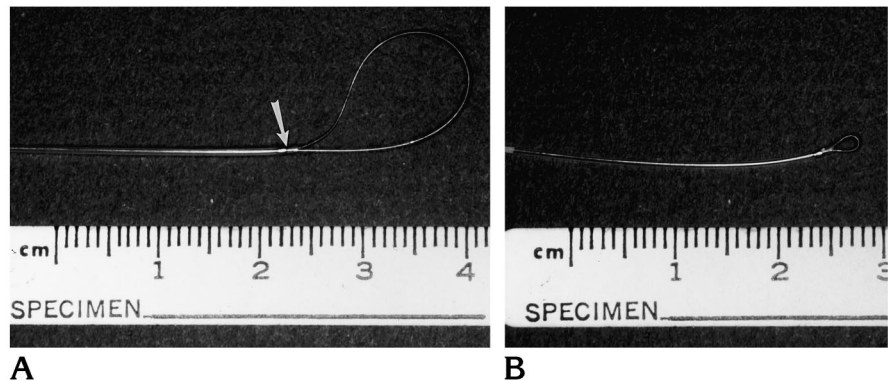


Fig 4. Nonangled Retriever device.

A, The snare wire is attached at its distal end to the catheter tip (arrow).

B, The snare diameter is reduced by withdrawing the wire at the catheter hub.



objects, the snare loop may be withdrawn into the microcatheter tip in order to grasp the foreign body. This device, however, was unable to encircle and retrieve the malpositioned coils in either of our patients.

In both patients, we subsequently advanced a nonangled Retriever device (Fig 4) (Target Therapeutics) into the basilar artery. The design of this device enables the operator to fashion a snare loop of variable diameter. A flexible stainless steel wire is permanently fixed near the catheter tip. The snare loop that protrudes from the tip of the 2.3F or 2.0F microcatheter is enlarged or diminished by advancing or withdrawing, respectively, the wire at the hub of the Retriever catheter. The Retriever cannot be advanced through an existing microcatheter; use of this device requires passage of the integral microcatheter and snare wire. As such, access to the more distal intracranial vasculature may be unattainable with this system. This device, however, performed well at the level of the circle of Willis, and did allow for successful retrieval of the malpositioned coils in both our patients. In each case, a large snare loop was advanced into one of the posterior cerebral arteries; the coil was engaged within the snare loop as the snare wire was withdrawn and the loop diameter di-

minished. Although a portion of the malpositioned coil was located within the aneurysmal dome in each patient, these coils were extracted without dislodgment of the remaining coil cluster or clinical evidence of embolic phenomena. Systemic heparinization, used throughout in both cases, most likely conferred significant protection against the formation of emboli.

More widespread availability of detachable coil systems may diminish the frequency of coil herniation into the parent vessel (23, 24), but it does not completely obviate its possibility or the use of the technique of microvascular foreign body retrieval.

References

1. Higashida RT, Halbach VV, Cahan LD, Hieshima GB, Konishi Y. Detachable balloon embolization therapy of posterior circulation intracranial aneurysms. *J Neurosurg* 1989;71:512-519
2. Higashida RT, Halbach VV, Dowd C, et al. Endovascular detachable balloon embolization therapy of cavernous carotid artery aneurysms: results in 87 cases. *J Neurosurg* 1990;72:857-863
3. Higashida RT, Halbach VV, Dowd CF, Barnwell SL, Hieshima GB. Intracranial aneurysms: interventional neurovascular treatment with detachable balloons: results in 215 cases. *Radiology* 1991; 178:663-670
4. Teng MMH, Chen CC, Lirng JF, Chen SS, Lee LS, Chang T. N-butyl-2-cyanoacrylate for embolization of carotid aneurysm. *Neuroradiology* 1994;36:144-147

5. Kinugasa K, Mandai S, Kamata I, et al. Prophylactic thrombosis to prevent new bleeding and to delay aneurysm surgery. *Neurosurgery* 1995;36:661-667
6. Kinugasa K, Mandai S, Tsuchida S, et al. Cellulose acetate polymer thrombosis for the emergency treatment of aneurysms: angiographic findings, clinical experience, and histopathological study. *Neurosurgery* 1994;34:694-701
7. Guglielmi G, Viñuela F, Dion J, Duckwiler G. Electrothrombosis of saccular aneurysms via endovascular approach. *J Neurosurg* 1991;75:8-14
8. Guglielmi G, Viñuela F, Duckwiler G, et al. Endovascular treatment of posterior circulation aneurysms by electrothrombosis using electrically detachable coils. *J Neurosurg* 1992;77:515-524
9. Dowd CF, Halbach VV, Higashida RT, Barnwell SL, Hieshima GB. Endovascular coil embolization of unusual posterior inferior cerebellar artery aneurysms. *Neurosurgery* 1990;27:954-961
10. Zubillaga AF, Guglielmi G, Viñuela F, Duckwiler GR. Endovascular occlusion of intracranial aneurysms with electrically detachable coils: correlation of aneurysm neck size and treatment results. *AJNR Am J Neuroradiol* 1994;15:815-820
11. Marks MP, Chee H, Liddell RP, Steinberg GK, Panahian N, Lane B. A mechanically detachable coil for the treatment of aneurysms and occlusion of blood vessels. *AJNR Am J Neuroradiol* 1994;15:821-827
12. Saatci I, Cikirge HS, Firat MM, et al. Placement of mechanically detachable spiral coils in the endovascular treatment of intracranial aneurysms: work in progress. *J Vasc Interv Radiol* 1996;7:75-79
13. Casasco AE, Aymard A, Gobin P, et al. Selective endovascular treatment of 71 intracranial aneurysms with platinum coils. *J Neurosurg* 1993;79:3-10
14. Numaguchi Y, Pevsner PH, Rigamonti D, et al. Platinum coil treatment of complex aneurysms of the vertebrobasilar circulation. *Neuroradiology* 1992;34:252-255
15. Vujic I, Moore L, McWey RE. Retrieval of coil after unintentional embolization of ileocolic artery. *Radiology* 1986;160:563-564
16. Yedlicka JW Jr, Carlson JE, Hunter DW, Castaneda-Zuniga WR, Amplatz K. Nitinol gooseneck snare for removal of foreign bodies: experimental study and clinical evaluation. *Radiology* 1991;178:691-693
17. Hawkins J, Quisling RG, Mickle JP, Hawkins IF. Retrievable Gianturco-coil introducer. *Radiology* 1986;158-262-264
18. Chuang VP. Nonoperative retrieval of Gianturco coil from abdominal aorta. *AJR Am J Roentgenol* 1979;132:996-997
19. Chuang VP, Wallace S, Gianturco C, Soo CS. Complications of coil embolization: prevention and management. *AJR Am J Roentgenol* 1981;137:809-813
20. Weber J. A complication with the Gianturco coil and its non-surgical management. *Cardiovasc Intervent Radiol* 1980;3:156-158
21. Smith TP, Graves VB, Halbach VV, et al. Microcatheter retrieval device for intravascular foreign body removal. *AJNR Am J Neuroradiol* 1993;14:809-811
22. Graves VB, Rappe AH, Smith TP, Sepetka I, Ahuja A, Strother CM. An endovascular retrieving device for use in small vessels. *AJNR Am J Neuroradiol* 1992;14:804-808
23. Gurian JH, Martin NA, King WA, Duckwiler GR, Guglielmi G, Viñuela F. Neurosurgical management of cerebral aneurysms following unsuccessful or incomplete endovascular embolization. *J Neurosurg* 1995;83:843-853
24. Standard SC, Chavis TD, Wakhloo AK, Ahuja A, Guterman LR, Hopkins LN. Retrieval of a Guglielmi detachable coil after unraveling and fracture: case report and experimental results. *Neurosurgery* 1994;35:994-999