

Are your MRI contrast agents cost-effective?

Learn more about generic Gadolinium-Based Contrast Agents.



**FRESENIUS
KABI**

caring for life

AJNR

**Mapping of the sensorimotor cortex:
functional MR and magnetic source imaging.**

T P Roberts and H A Rowley

AJNR Am J Neuroradiol 1997, 18 (5) 871-880

<http://www.ajnr.org/content/18/5/871>

This information is current as
of April 19, 2024.

Mapping of the Sensorimotor Cortex: Functional MR and Magnetic Source Imaging

Timothy P. L. Roberts and Howard A. Rowley

PURPOSE: To assess the reliability and comparability of functional MR imaging and magnetic source imaging for mapping the somatosensory cortex. **METHODS:** Parallel studies were performed in eight volunteer subjects in whom both hemispheres were measured with the use of painless tactile stimulation of the tip of each index finger. Magnetic source imaging was performed using a 37-channel biomagnetometer; evoked magnetic fields were analyzed using the single-equivalent dipole representation to ascertain the neuronal source. Functional MR imaging was performed on a 1.5-T MR unit. Blocks of images during periods of rest and activation were acquired using gradient-echo echo-planar imaging. Correlation analysis identified pixels in which signal intensity correlated with the stimulus function. A subsequent requirement for spatial connectivity of activation was imposed to reduce the random occurrence of pixels satisfying the correlation criteria. **RESULTS:** Using temporal and spatial statistical criteria for activation, we found that functional MR imaging showed activation in 11 of 16 hemispheres. In three cases, this was accompanied by activity either frontally or ipsilateral to the stimulus. Magnetic source imaging showed parietal contralateral location in all 16 cases. Where successful localization was achieved with both methods, the separation between sources appeared to be between 1 and 4 cm. Functional MR imaging localizations tended to lie more superficially than the magnetic source imaging localizations. Performance of a simple motor task, rather than use of somatosensory stimulation, resulted in a cortical signal change detectable with a similar functional MR imaging approach in all cases, suggesting the more robust nature of this stimulus. **CONCLUSIONS:** Functional mapping of the somatosensory cortex can be achieved with functional MR imaging or magnetic source imaging. Functional MR imaging yields more spurious locations and fails to show localization more often. If neuronal signal propagation pathways are of interest, the temporal resolution of functional MR imaging alone may be inadequate. A combination of magnetic source imaging and functional MR imaging may allow improved sensitivity, fewer false-positive results, and high spatial and temporal resolution.

Index terms: Magnetic resonance, functional; Magnetic resonance, technique

AJNR Am J Neuroradiol 18:871–880, May 1997

Clinical implementation of echo-planar imaging (1, 2) combined with appreciation of the blood oxygen level-dependent (BOLD) (3–5) contrast mechanism has given rise to a rapid

explosion in functional magnetic resonance (MR) imaging of the cortical response to peripheral stimulation and cognitive task performance (6). These studies tend to involve stimulation paradigms lasting from seconds to minutes, with high-speed MR images being acquired at a frame rate on the order of one per second. The BOLD contrast mechanism relies on the fact that an increase in regional cortical blood flow occurs in response to task performance or stimulation but that this is not accompanied by a concomitant increase in local tissue oxygen extraction (6–8). This consequence can be detected with magnetic susceptibility (T_2^*)–sensitive imaging sequences such as gradient-echo

Received July 2, 1996; accepted after revision November 22.

Supported in part by Biomagnetic Technologies Inc.

Presented in part at the annual meeting of the Radiological Society of North America, Chicago, Ill, November 1995.

From the Biomagnetic Imaging Laboratory, Department of Radiology, Box 0628, University of California, San Francisco, 513 Parnassus Ave, San Francisco, CA 94143. Address reprint requests to Timothy P. L. Roberts, PhD.

AJNR 18:871–880, May 1997 0195-6108/97/1805-0871

© American Society of Neuroradiology

and echo-planar imaging (9–13). The hemodynamic response to stimulation is not instantaneous but rather has a time constant on the order of a few seconds and thus essentially limits the meaningful temporal resolution achievable in such studies.

However, studies of the electrical activity associated with brain function have demonstrated that significant events occur within tens of milliseconds of stimulus presentation (14–24). Particularly if the goal of a study is to track the propagation of signal from one brain area to another, higher temporal resolution is required. Electroencephalographic studies with scalp-placed electrodes, while providing such temporal resolution, may not be adequate for locating the neuronal current source.

Magnetoencephalography shares the high temporal resolution of electroencephalography, being limited only by analog-to-digital conversion rates (typically, 1 to 4 kHz). However, since it detects the magnetic rather than the electric component of the extracranial field, it can form the basis of a more robust method of neuronal source localization, provided an array of magnetic field detectors can be used to cover sufficient spatial extent to allow adequate modeling of the current source. When source localizations modeled from the magnetoencephalographic signal are registered with high-resolution MR imaging, the resulting magnetic source images display functional information in an anatomic context (15, 21, 25).

One of the important clinical applications of functional brain imaging is presurgical mapping to allow definition of eloquent cortex in relation to mass lesions that may be treated by resection or by alternative nonsurgical approaches, such as focused irradiation (gamma knife) or chemotherapy/radiation therapy, according to the functional nature of nearby brain tissue.

The purpose of our study was to compare functional MR imaging and magnetic source imaging for functional mapping of the sensorimotor cortex. The methods were assessed in healthy volunteers for the rate at which localizations were detected using comparable stimuli.

Materials and Methods

All studies were performed with the approval of our Institutional Human Studies Committee. Eight healthy volunteers (three women and five men; mean age, 30 years; range, 25 to 36 years) were studied with both MR imaging

and magnetic source imaging techniques. Functional MR imaging and magnetic source imaging examinations were performed on separate occasions and analyzed by a single reviewer. For four subjects, magnetic source imaging data were analyzed before functional MR imaging and in the other four, analysis order was reversed. Analysis of functional MR imaging and magnetic source imaging data for any individual subject was not performed on the same day.

Stimulation

Painless tactile stimulation of the fingertips was used as the mode of activation in all studies. In both MR and magnetic source imaging environments, a compressed air-driven balloon diaphragm was clipped to the tip of the index finger of the subjects' left and subsequently right hands. The diaphragm was driven with bursts of compressed air (15 to 30 psi) lasting approximately 30 milliseconds and repeated at an interval of 0.5 to 1 second. Additionally, to test the adequacy of the functional MR imaging and analysis strategy, functional MR imaging was used to observe the cortical activity associated with the performance of a simple motor task, involving the flexion of the index finger, reported by many groups as providing a reliably reproducible response.

Functional MR Imaging

Functional MR imaging was performed on a 1.5-T system equipped with gradient coils that can produce ± 20 mT/m with a rise time of 230 mT/m per millisecond, which allows echo-planar imaging capability.

For functional MR imaging studies, periods of activation were interleaved with similar periods of rest. Each period, or block, was of 20 seconds' duration. Throughout the entire protocol, multisection echo-planar images (128×128 matrix, 40×20 -cm field of view [FOV]) were acquired with a period of 2.5 seconds between successive images of the same section. Thus, eight multisection image sets were acquired during each 20-second block according to the paradigm below (R represents a multisection image set acquired during rest and A during activation).

RRRRRRRRRAAAAAAAAAARRRRRRRRRAAAAAAAAAARRRRRRRR

In each multisection set, five sections with a thickness of 7 mm and an intersection gap of 3 mm were acquired in an axial plane covering an area from the corpus callosum to the vertex. In addition to gradient echo-planar imaging (2500/60/1 [repetition time/echo time/excitations]), spin-echo (2500/100/1) echo-planar imaging sequences were obtained in three subjects.

Functional MR Imaging Postprocessing

The series of functional MR images were analyzed in the following manner. The first four images were discarded to eliminate signal intensity variations arising from progressive saturation. Subsequently, on a pixel-by-pixel basis, signal intensity variations over the course of the series

were correlated with the stimulus function (26) to determine the r , correlation coefficient, and the corresponding t statistics. A t test was then performed to determine the significance of the correlation. Correlations were regarded as significant if P was less than .01. Further, a spatial constraint was imposed. To eliminate spurious random activation noise, it was required that at least five contiguous pixels (with no geometric constraints) be similarly correlated (27). This effectively placed a requirement for the cortical extent to exhibit BOLD-related signal enhancement to exceed $5 \times 0.7 \times 0.31 \times 0.16 = 0.17 \text{ cm}^3$.

Magnetic Source Imaging

Magnetoencephalography was performed using a 37-channel biomagnetometer positioned over the parietal portion of each subject's head, contralateral to the stimulation site. Data were collected in 300-millisecond epochs, centered on the stimulation trigger, with a sampling rate of 297.8 Hz per channel. Two hundred fifty-six to 512 epochs, collected with identical stimuli and pseudorandom interstimulus intervals in the range of 500 milliseconds to 1 second, were averaged to improve signal-to-noise ratio. Latencies within the range of 30 to 70 milliseconds after stimulation onset were examined. Extracranial magnetic fields were modeled by using the single-equivalent dipole method to obtain the spatial coordinates of the neuronal current source (21). The anatomic location of the activity source was found by coregistration with high-resolution three-dimensional gradient-echo MR imaging, using anatomic landmarks (nasion, left and right preauricular points) marked during magnetic source imaging examination, and used to define the magnetic source imaging spatial reference frame. These landmarks were subsequently identified on the high-resolution MR image, and the appropriate spatial transformation matrix was calculated and applied to magnetic source imaging source localizations (Fig 1).

Results

With a total of 16 stimulation sites (eight subjects, left and right index finger independently stimulated), functional MR imaging did show pericentral sulcal localization in 11 cases; of the stimulations that failed to elicit a detectable functional MR imaging response, one case was bilateral and the remaining three were unilateral. Magnetic source imaging showed satisfactory localization in all cases (Fig 2), satisfying standard clinical criteria for model-data agreement (correlation coefficient, $> .98$; statistical confidence volume, $< 1 \text{ cm}^3$; latency range, 30 to 70 milliseconds). Furthermore, all magnetic source imaging localizations were found to lie close to the central sulcus (the anterior bank of the postcentral gyrus being the presumed origin

of this type of early component of the somatosensory evoked neuromagnetic field). Erroneous ipsilateral and frontal/premotor activation was detected with functional MR imaging in three cases; this was inherently avoided with magnetic source imaging by the spatial position of the detector probe and its restricted FOV. It is clear from Figures 3 through 6 that functional MR imaging and magnetic source imaging localizations appear in accordant gyri and at similar axial levels. There was an observed tendency for the functional MR imaging localization to lie more superficially than the magnetic source imaging location, attributable to the signal contribution from sulcal veins. Figures 3 through 6 show examples of functional MR imaging and magnetic source imaging localizations corresponding to similar, tactile stimulation of the left and right index fingers. A typical time course of signal intensity changes from pixels, identified on such overlay maps as activated, is illustrated in Figure 7. The tendency toward spurious artifactual localization with functional MR imaging is illustrated in Figure 8A, which shows apparent significant activation of anterior areas in response to stimulation of the right index finger; the corresponding postcentral localization identified with magnetic source imaging in response to a similar stimulus is shown in Figure 8B. Figure 9 illustrates the potential for false-negative results with functional MR imaging. In that subject, there was no clearly identifiable activation with functional MR imaging; however, magnetic source imaging provided a reliable postcentral localization with a similar stimulus (Fig 9B). In the three subjects in whom spin-echo echo-planar imaging was performed with a similar stimulus protocol, no significant activation was detected using the above statistical approach. This observation is in accordance with the reduced signal-to-noise ratio expected from the spin-echo experiment, associated with its (desired) insensitivity to signal from larger (venous) structures (28–30). Further investigations probing the experimental paradigm (number of activation/rest images) required to elicit robustly detectable signal changes on spin-echo echo-planar images are underway.

Discussion

Mapping of the sensorimotor cortex provides the neurosurgeon with vital information regard-

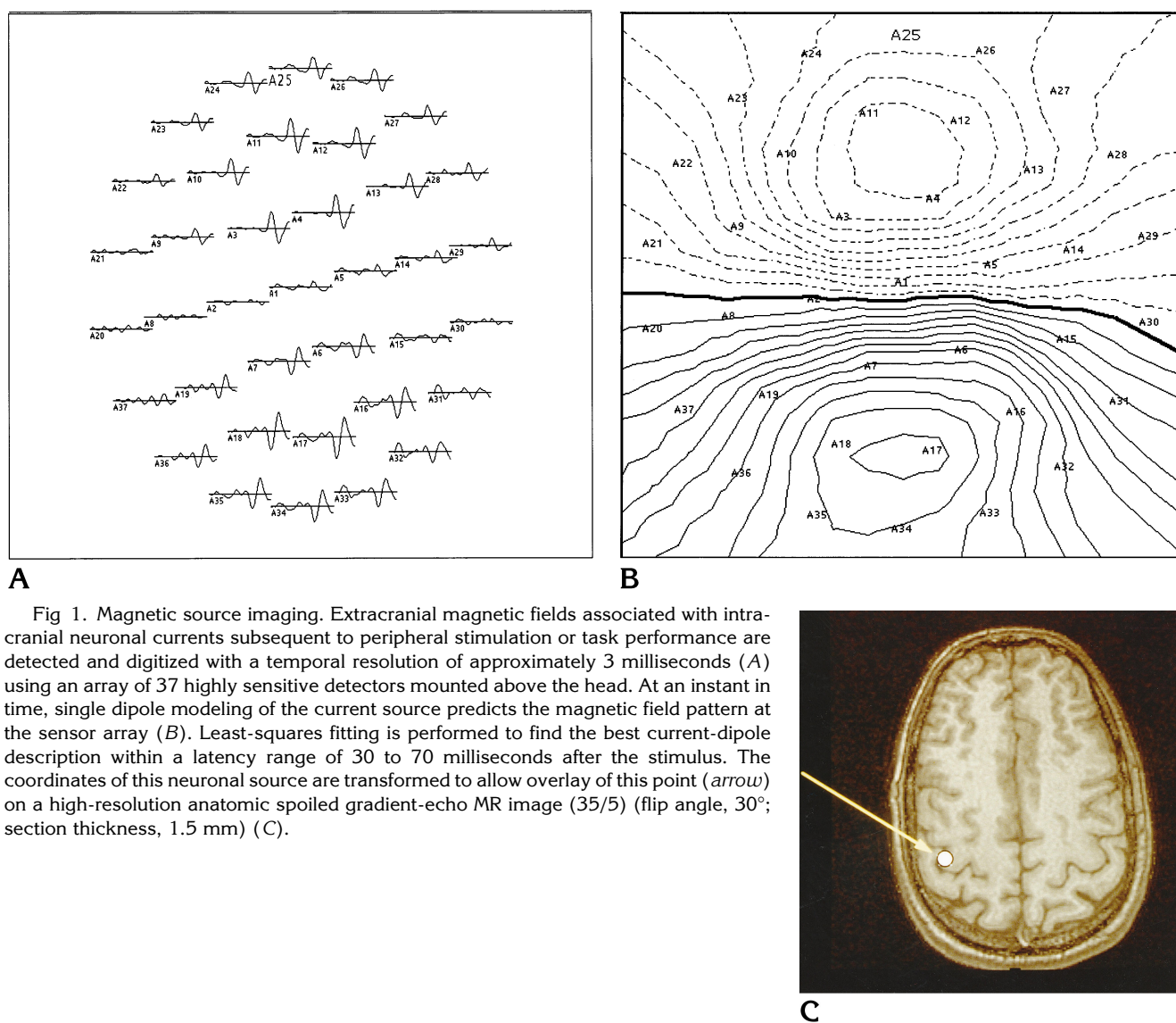


Fig 1. Magnetic source imaging. Extracranial magnetic fields associated with intracranial neuronal currents subsequent to peripheral stimulation or task performance are detected and digitized with a temporal resolution of approximately 3 milliseconds (A) using an array of 37 highly sensitive detectors mounted above the head. At an instant in time, single dipole modeling of the current source predicts the magnetic field pattern at the sensor array (B). Least-squares fitting is performed to find the best current-dipole description within a latency range of 30 to 70 milliseconds after the stimulus. The coordinates of this neuronal source are transformed to allow overlay of this point (arrow) on a high-resolution anatomic spoiled gradient-echo MR image (35/5) (flip angle, 30°; section thickness, 1.5 mm) (C).

ing the functional organization of cortical tissue, particularly in the planning of a surgical approach route for the resection of mass lesions, epileptogenic tissues, and other intracranial anomalies (24, 25, 31–33). Both functional MR imaging and magnetic source imaging offer a potential for noninvasive preoperative cortical mapping. The purpose of this study was to compare the two techniques for the reliability with which they allowed description of the sensorimotor cortical organization.

It is worth considering the scale of the neurosurgical requirement: it is rarely required to define sensory or motor homuncular organization precisely, but rather to identify areas of somatosensory and motor control in general (24, 25, 31–33). In many cases this reduces to a “func-

tional” identification of the central sulcus, separating the precentral from postcentral gyri. Even in healthy volunteers and with high-resolution anatomic MR imaging, the central sulcus is not always unequivocally identifiable; it is certainly the case that in the presence of mass lesions, sulcal and gyral definition is commonly degraded (34). It is particularly in these cases that identification of functional organization assumes such importance, and thus anatomic-based morphologic methods alone are unlikely to be adequate for presurgical mapping (33, 34).

Functional MR imaging offers attractive benefits for clinical cortical mapping. Most neurosurgery candidates undergo a preoperative MR examination, and therefore a functional mapping protocol could simply be incorporated into

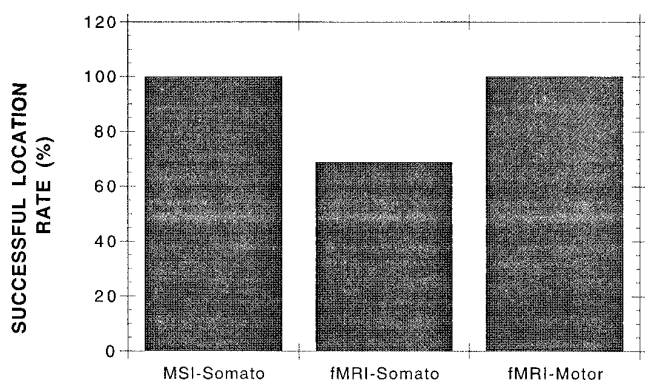


Fig 2. Magnetic source imaging (MSI) versus functional MR imaging (fMRI): true-positive rate. For somatosensory stimulation, magnetic source imaging provided a 100% true-positive rate. With a similar stimulus, functional MR imaging showed satisfactory pixel identification in only 69% of cases. However, with performance a more robust motor task, functional MR imaging with similar acquisition protocol and statistical analysis provided 100% successful locations, confirming the methodologic efficacy.

the standard, avoiding the need for a separate study and associated errors of image coregistration (as well as penalties associated with time and cost). Furthermore, the sensitivity of functional MR imaging does not vary with the depth or geometric extent or orientation of the activated source and so it is appropriate for use with a wide variety of stimuli to map a range of primary and associated functional activities. Some regions (eg, brain stem and perisinus frontal lobe) may be less successfully imaged with functional MR imaging, since the technique is inherently sensitive to magnetic susceptibility (this is indeed the basis of the signal increase observed in response to stimulation, the BOLD effect). In these anatomic areas, however, this sensitivity leads to image distortion and signal-voiding magnetic susceptibility artifacts, associated with interfaces between media with different magnetic susceptibilities (specifically, air, bone, and tissue).

To achieve clinical utility, it is necessary to have functional MR imaging coverage of more than a single anatomic plane or section. This is particularly important in cases in which functional areas might be displaced from their expected anatomic site, either by mass lesions or adaptation. To this end, multisection or 3-D approaches should be advocated. To achieve this and maintain adequate temporal resolution (on the order of 1 to 2 seconds), echo-planar imaging sequences are required. Conventional gradient-echo imaging, while providing appropriate contrast, cannot satisfy such multisection

capabilities without incurring a loss of temporal resolution.

A number of statistical approaches for the analysis of functional MR imaging data have been proposed (9, 12, 26). All share the common goal of identifying pixels within the image that respond to stimulation or task performance. Since the observed response is only on the order of a few percent and image signal-to-noise ratio itself may be poor, these methods must attempt to provide a rigorous basis for the unequivocal identification of cortical activation. Simple subtraction of "resting state" from "activated state" images generally suffers from inadequate signal intensity difference compared with random image noise. To counter this, several acquisitions in each state may be averaged (9). However, this necessarily reduces temporal resolution. If a large number of images is acquired while a periodic stimulus is applied, a Fourier transform of the image series may be performed to identify pixels with signal intensity variations of a similar periodicity. Following the method of Bandettini et al (26), we performed a correlation analysis in this study, which allows identification of pixels whose signal intensity variations correlate significantly with the stimulus presentation. However, a simple temporal correlation is insufficient (with a threshold of $P < .01$, an image matrix of 128×128 may contain many random or false-positive correlations). Thus, we invoked a requirement for spatial connectivity, reducing the frequency of such correlation noise. This spatial connectivity or clustering algorithm has been modeled recently by Forman et al (27), who concluded that isolated false-positive pixels could be effectively eliminated with this approach.

Locations of neuronal activity based on magnetoencephalographic data were analyzed using the single-equivalent dipole approach. This simplification of the neuronal environment, although not a faithful description of human brain activation, has been widely used because of its practical implementation (21, 35, 36). Furthermore, several studies have indicated that in the case of simple cortical processes, such as the primary response to somatosensory stimulation, the model provides adequate accuracy of location compared with alternative standards, such as invasive electrocorticography (24, 34). Additionally, when anatomic landmarks are used to define precentral and postcentral gyri, magnetic source imaging was able to identify

Fig 3. Left index finger stimulation: functional MR imaging (A) and magnetic source imaging (B). Pixels identified as activated by functional MR imaging are overlaid on acquired gradient-echo echo-planar image (echo time, 60; flip angle, 90°; FOV, 40 × 20 cm; matrix, 128 × 128). Magnetic source imaging locations are overlaid on a spoiled gradient-echo MR image (35/5) (flip angle, 30°; section thickness, 1.5 mm).

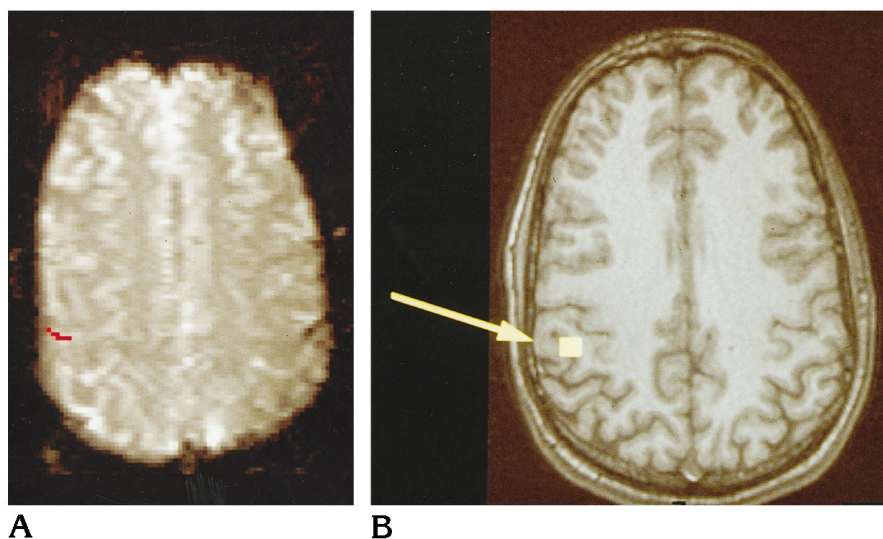


Fig 4. Right index finger stimulation (same subject as in Figure 3): functional MR imaging (A) and magnetic source imaging (B). Pixels identified as activated by functional MR imaging are overlaid on an acquired gradient-echo echo-planar image (echo time, 60; flip angle, 90°; FOV, 40 × 20 cm; matrix, 128 × 128). Magnetic source imaging locations are overlaid on a spoiled gradient-echo MR image (35/5) (flip angle, 30°; section thickness, 1.5 mm).

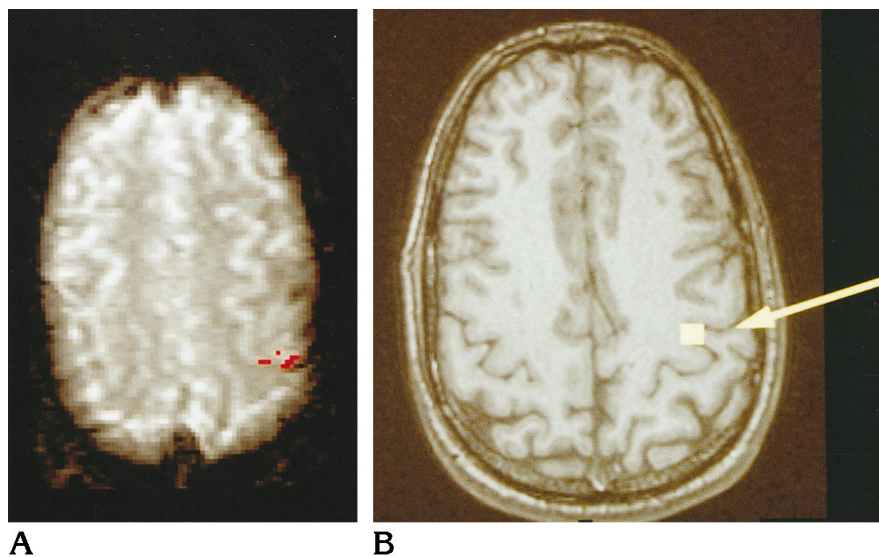
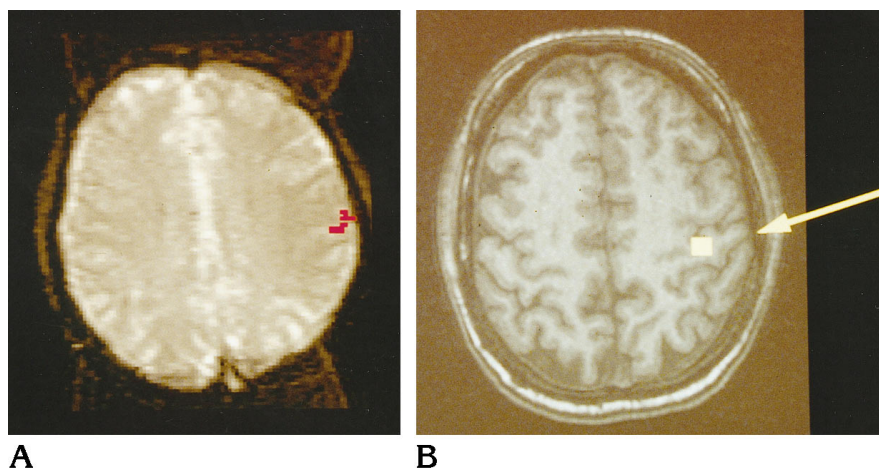


Fig 5. Right index finger stimulation: functional MR imaging (A) and magnetic source imaging (B). Pixels identified as activated with functional MR imaging are overlaid on an acquired gradient-echo echo-planar image (echo time, 60; flip angle, 90°; FOV, 40 × 20 cm; matrix, 128 × 128). Magnetic source imaging locations are overlaid on a spoiled gradient-echo MR image (35/5) (flip angle, 30°; section thickness, 1.5 mm).



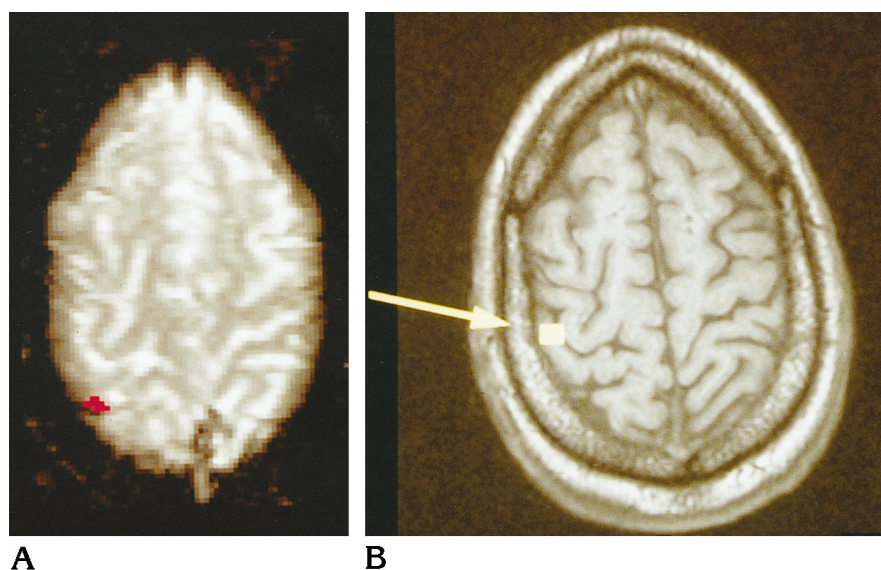


Fig 6. Left index finger stimulation: functional MR imaging (A) and magnetic source imaging (B). Pixels identified as activated by functional MR imaging are overlaid on an acquired gradient-echo echo-planar image (echo time, 60; flip angle, 90°; FOV, 40 × 20 cm, matrix, 128 × 128). Magnetic source imaging locations are overlaid on a spoiled gradient-echo MR image (35/5) (flip, 30°; section thickness, 1.5 mm). Both techniques show agreement on the superior level of somatosensory digit representation in this subject.

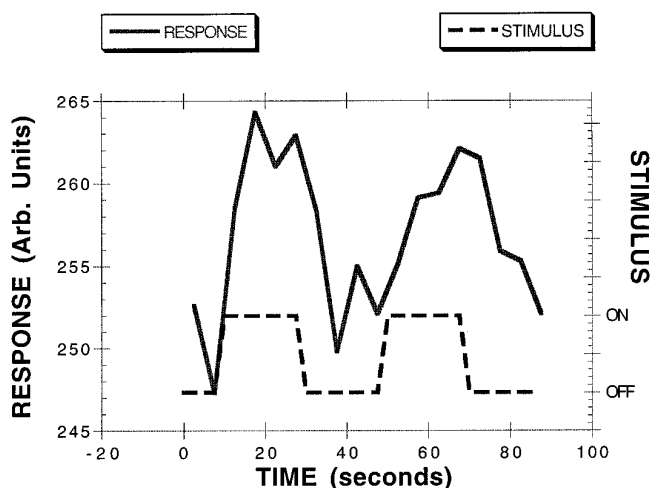


Fig 7. Typical functional MR imaging signal intensity changes in activated pixels as a function of activation state. This example corresponds to subject in Figure 5 and was obtained by measuring signal intensity changes in the region of interest indicated in Figure 5A.

the central sulcus by the postcentral location of the single-equivalent dipole representing the response to somatosensory stimulation (33). The single-equivalent dipole model provides an estimate of a single current source that might give rise to the measured extracranial fields. The modeling process involves the nonlinear least-squares fitting of dipole strength, location, and orientation to minimize the difference between observed and predicted extracranial fields (based on Biot Savart law computation). The fitting process provides a measure of data-model correlation and goodness-of-fit and 95% confidence volume. In accord with previous investigators, we chose to accept dipole locations

that satisfied the observed data with a confidence volume of less than 1 cm³ and with a correlation coefficient of r greater than .98 (30, 37–39). Clearly, changing such dipole selection criteria influences the rate of localization success.

In our study, somatosensory stimulation with painless pneumatic tapping to the fingertips proved inadequate for routine use with functional MR imaging (69% acceptable locations), although in the 11 of 16 instances in which localization was shown, good correspondence with magnetic source imaging and anatomic expectation was found. Thus, it seems that failure to find localization results from poor signal-to-noise ratio and statistical power rather than to an inherent inability of the technique. Furthermore, incomplete spatial coverage (five sections with a thickness of 7 mm and a 3-mm separation were used) and weakness of the stimulus itself might account for some of the failures. Stronger, but still painless, somatosensory stimulation methods are under development. Also, although attempts were made to provide identical somatosensory stimuli for functional MR imaging and magnetic source imaging studies, the pressure and duration of the stimulus pulse, as well as the interstimulus interval, may have varied in the different operating environments (the magnetic source imaging stimulus was computer-generated and automatically regulated; however, to operate in the strong fringe fields of the 1.5-T magnet during functional MR imaging, the stimulus generation system was manually driven). This issue con-

Fig 8. Functional MR imaging has a tendency toward spurious locations (overlaid on a gradient-echo echo-planar image) (echo time, 60; flip angle, 90°; FOV, 40 × 20 cm; matrix, 128 × 128). This case shows anterior activation in response to right-hand index finger stimulation (A). This apparent location is presumed attributable to signal in draining veins remote from the neuronal activation site. The corresponding magnetic source imaging location (B) appears as predicted in the post-central gyrus (seen coregistered with a spoiled gradient-echo image (35/5) (flip angle, 30°; section thickness, 1.5 mm).

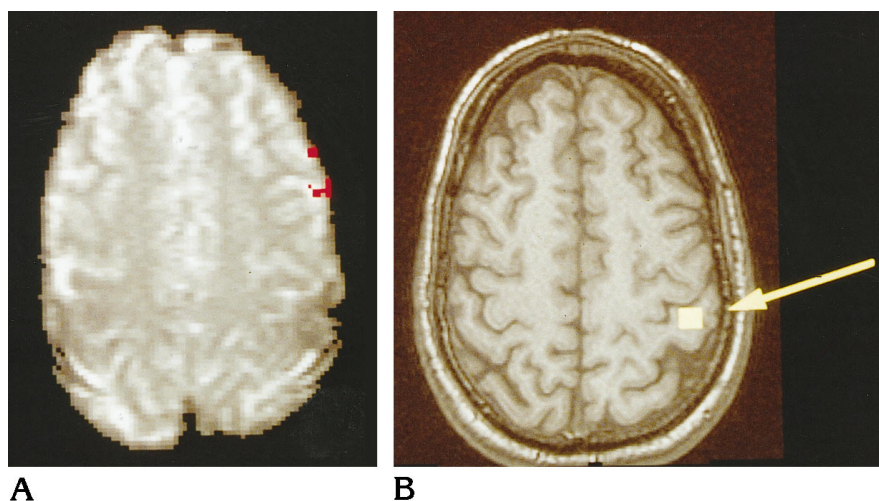
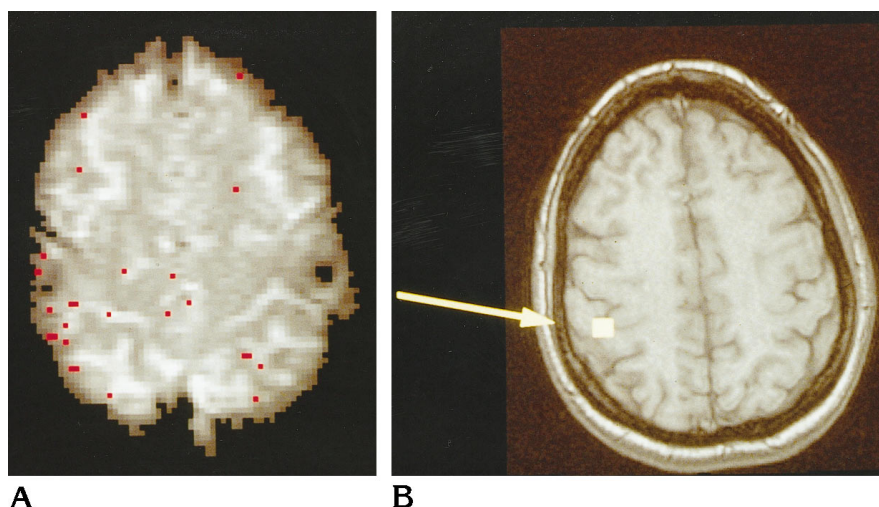


Fig 9. In some cases, functional MR imaging fails to show significant activation (A), wherein multiple individual pixels satisfy the correlation requirement (red dots) but fail to satisfy the requirement for spatial connectivity. This observation, made in several subjects, presumably reflects the lack of sufficient spatial extent, or insufficient magnitude, of stimulus-dependent hemodynamic changes. Magnetic source imaging, however, reveals expected neuronal activity in the postcentral gyrus (B), overlaid on a spoiled gradient-echo image (35/5) (flip angle, 30°; section thickness, 1.5 mm). This example corresponds to stimulation of the left index finger.



cerning stimuli also should be considered in comparisons between other functional imaging techniques. Alternatively, simple motor task performance seems more reliable, having provided 16 of 16 successful locations with functional MR imaging.

The general agreement between the two techniques is encouraging, particularly when considering the different physiological aspects they probe (hemodynamic versus electrical activity). The lack of precise colocalization might be anticipated, especially because to achieve detectable functional MR imaging we adopted the gradient-echo echo-planar imaging sequence with its dominant venous contribution. It seems likely that the early poststimulus negative BOLD effect, seen as signal loss caused by increased tissue oxygen uptake immediately before increased cerebral blood flow (40), might compare more closely with the locations

on the magnetic source images. However, this effect was not studied with our 1.5-T system. Furthermore, the simplistic magnetic source imaging modeling adopted (single-equivalent dipole) limits the confidence of magnetic source imaging location to a few millimeters (38).

Improved magnetic source imaging modeling strategies with more complex current source descriptions might become feasible if limited in range by some prior spatial knowledge, provided, for example, by functional MR imaging (41). However, clearly strict spatial constraints imposed by functional MR imaging should be avoided, because of underlying physiological differences. Although not specifically required in the application of presurgical mapping of the sensorimotor strip, it also appears that the temporal resolution of magnetic source imaging might allow the elucidation of temporal sequences of multiple sites of activation identified

by functional MR imaging (and inherently time-averaged and thus unresolvable in time and apparently simultaneous with this technique). Thus, the combination of techniques, even without the requirement for strict spatial colocalization, might provide valuable information about neural signal propagation, unobtainable from either method alone.

Acknowledgments

We are grateful to Dan Vigneron for his advice regarding the echo-planar imaging implementation, Gary Cicirello for excellent technical assistance, and William P. Dillon and David Poeppel for invaluable discussions. We also thank Biomagnetic Technologies Inc for technical support of the magnetic source imaging component of the study.

References

- Mansfield P. Multiplanar image formation using NMR spin echoes. *J Physiol* 1977;C10:L55-L58
- Edelman RR, Wielopolski P, Schmitt F. Echo planar MR imaging. *Radiology* 1994;192:600-612
- Ogawa S, Lee TM, Kay AR, Tank DW. Brain magnetic resonance imaging with contrast dependent on blood oxygenation. *Proc Natl Acad Sci U S A* 1990;87:9868-9872
- Ogawa S, Lee TM. Magnetic resonance imaging of blood vessels at high fields: in vivo and in vitro measurements and image simulation. *Magn Reson Med* 1990;16:9-18
- Ogawa S, Lee TM, Nayak AS, Glynn P. Oxygenation sensitive contrast in magnetic resonance image of rodent brain at high magnetic fields. *Magn Reson Med* 1990;14:68-78
- Kwong KK. Functional magnetic resonance imaging with echo planar imaging. *Magn Reson Q* 1995;11:1-20
- Fox P, Raichle M. Focal physiological uncoupling of cerebral blood flow and oxidative metabolism during somatosensory stimulation in human subjects. *Proc Natl Acad Sci U S A* 1986;83:1140-1144
- Fox PT, Raichle ME, Mintun MA, Dence C. Nonoxidative glucose consumption during focal physiologic neural activity. *Science* 1988;241:462-464
- Frahm J, Bruhn H, Merboldt K-D, Hénicke W. Dynamic MR imaging of human brain activation during rest and photic stimulation. *J Magn Reson Imaging* 1992;2:501-505
- Bandettini PA, Wong EC, Hinks RS, Tikofsky RS, Hyde JS. Time course EPI of human brain function during task activation. *Magn Reson Med* 1992;25:390-397
- Hammeke TA, Yetkin FZ, Mueller WM, et al. Functional magnetic resonance imaging of somatosensory stimulation. *Neurosurgery* 1994;35:677-681
- Kwong KK, Belliveau JW, Chesler DA, et al. Dynamic magnetic resonance imaging of human brain activity during primary sensory stimulation. *Proc Natl Acad Sci U S A* 1992;89:5675-5679
- McCarthy G, Blamire AM, Rothman DL, Gruetter R, Shulman RG. Echo planar magnetic resonance imaging studies of frontal cortex activation during word generation in humans. *Proc Natl Acad Sci U S A* 1993;90:4952-4956
- Baumgartner C, Doppelbauer A, Deecke L, et al. Neuromagnetic investigation of somatotopy of human hand somatosensory cortex. *Exp Brain Res* 1991;87:641-648
- Gallen CC, Sobel DF, Schwartz B, Copeland B, Waltz T, Aung M. Magnetic source imaging: present and future. *Invest Radiol* 1993;28(Suppl)3:S153-S157
- Gevens A, Cutillo B, DuRousseau D, et al. Imaging the spatiotemporal dynamics of cognition with high-resolution evoked potential methods. *Hum Brain Mapping* 1994;1:101-116
- Harding GF, Armstrong RA, Janday B. Visual evoked electrical and magnetic response to half-field stimulation using pattern reversal stimulation. *Ophthalmic Physiol Opt* 1992;12:171-174
- Hari R. On brain's magnetic responses to sensory stimuli. *J Clin Neurophysiol* 1991;8:157-169
- Hari R. Magnetic evoked fields of the human brain: basic principles and applications. *Electroencephalogr Clin Neurophysiol Suppl* 1990;41:3-12
- Nuwer MR. Electroencephalographic brain mapping. *West J Med* 1991;155:67
- Darcey TM, Ary JP, Fender DH. Methods for location of electrical sources in the human brain. *Prog Brain Res* 1980;54:128-134
- Rose DF. Magnetic evoked responses: comparison with electrical evoked responses. *Adv Neurol* 1990;54:89-94
- Williamson SJ, Kaufman L. Evolution of neuromagnetic topographic mapping. *Brain Topogr* 1990;3:113-127
- Wood C, Spencer DD, Allison T, McCarthy G, Williamson PD, Goff WR. Localization of human sensorimotor cortex during surgery by cortical surface recording of somatosensory evoked potentials. *J Neurosurg* 1988;68:99-111
- Roberts TPL, Rowley HA, Kucharczyk J. Applications of magnetic source imaging to presurgical brain mapping. In: Kucharczyk J, Roberts TPL, Moseley ME, Orrison W, eds. *Neuroimaging Clinics of North America "Functional Neuroimaging."* Philadelphia, Pa: Saunders; 1995;5:251-266
- Bandettini PA, Jesmanowicz A, Wong EC, Hyde JS. Processing strategies for timecourse data sets in functional MRI of the brain. *Magn Reson Med* 1993;30:161-173
- Forman SD, Cohen JD, Fitzgerald M, Eddy WF. Improved assessment of significant activation in functional magnetic resonance imaging (fMRI): use of a cluster-size threshold. *Magn Reson Med* 1995;33:636-647
- Weisskoff RM, Zuo CS, Boxerman JL, Rosen BR. Microscopic susceptibility variation and transverse relaxation: theory and experiment. *Magn Reson Med* 1994;31:601-610
- Kennan RP, Zhong J, Gore JC. Intravascular susceptibility contrast mechanisms in tissues. *Magn Reson Med* 1994;31:9-21
- Lai S, Hopkins AL, Haacke EM, et al. Identification of vascular structures as a major source of signal contrast in high resolution 2D and 3D functional activation imaging of the motor cortex at 1.5T: preliminary results. *Magn Reson Med* 1993;30:387-392
- Jack CR, Thompson RM, Butts RK, et al. Sensory motor cortex: correlation of presurgical mapping with functional MR imaging and invasive cortical mapping. *Radiology* 1994;190:85-92
- Ojemann G, Sutherling W, Lesser R, Dinner D, Jayakar P, Saint-Hilaire J-M. Cortical stimulation. In: Engel J, ed. *Surgical Treatment of the Epilepsies*. 2nd ed. New York, NY: Raven Press; 1993:399-414
- Sobel DF, Gallen CC, Schwartz BJ, et al. Locating the central sulcus: comparison of MR anatomic and magnetoencephalographic functional methods. *AJNR Am J Neuroradiol* 1993;14:915-925
- Roberts TPL, Zusman E, McDermott M, Barbaro N, Rowley HA. Correlation of functional magnetic source imaging with intraoperative cortical stimulation in neurosurgical patients. *J Imag Guided Surg* 1996;1:339-347
- Gallen CC, Sobel DF, Lewine JD, et al. Neuromagnetic mapping of brain function. *Radiology* 1993;187:863-867

36. Pantev C, Gallen C, Hampson S, Buchanan S, Sobel D. Reproducibility and validity of neuromagnetic source localization using a large array biomagnetometer. *Am J EEG Technol* 1991;31:83-101
37. Gallen CC, Sobel DF, Waltz T, et al. Noninvasive presurgical neuromagnetic mapping of somatosensory cortex. *Neurosurgery* 1993;33:260-268
38. Gallen CC, Schwartz B, Rieke K, et al. Intrасubject reliability and validity of somatosensory source localization using a large array biomagnetometer. *Electroencephalogr Clin Neurophysiol* 1994; 90:145-156
39. Gallen C, Schwartz BJ, Bucholz RD, et al. Presurgical localization of functional cortex using magnetic source imaging. *J Neurosurg* 1995;82:988-994
40. Ernst T, Hennig J. Observation of a fast response in functional MR. *Magn Reson Med* 1994;32:146-149
41. Robinson SE. *Magnetoencephalography by Lead Field Synthesis*. United States Air Force SBIR Report, 1991