

Are your MRI contrast agents cost-effective?

Learn more about generic Gadolinium-Based Contrast Agents.



**FRESENIUS
KABI**

caring for life

AJNR

The low sensitivity of fluid-attenuated inversion-recovery MR in the detection of multiple sclerosis of the spinal cord.

M D Keiper, R I Grossman, J C Brunson and M D Schnall

AJNR Am J Neuroradiol 1997, 18 (6) 1035-1039

<http://www.ajnr.org/content/18/6/1035>

This information is current as
of April 16, 2024.

The Low Sensitivity of Fluid-Attenuated Inversion-Recovery MR in the Detection of Multiple Sclerosis of the Spinal Cord

Mark D. Keiper, Robert I. Grossman, John C. Brunson, and Mitchell D. Schnall

PURPOSE: To confirm the expected superiority of fluid-attenuated inversion-recovery (FLAIR) over conventional fast spin-echo MR imaging in the detection of multiple sclerosis (MS) of the spinal cord. **METHODS:** Fifteen subjects with known MS involving the spinal cord and brain were studied prospectively. The entire cord was imaged with a phased-array coil on a 1.5-T MR system. Sagittal T1-weighted and fast spin-echo proton density- and T2-weighted images were followed by fast FLAIR images. FLAIR parameters were varied to optimize lesion conspicuity with optimal inversion times (TIs) ranging from 2400 to 2600. Lesion conspicuity and detection were compared between the fast spin-echo and FLAIR images by three radiologists who reached agreement by consensus. **RESULTS:** The FLAIR technique effectively suppressed cerebrospinal fluid (CSF) signal and reduced CSF pulsation and truncation artifacts in all cases. Shorter imaging parameters (repetition time of 4000 to 6000, TI of 1500 to 2000) uniformly decreased lesion conspicuity in all subjects. Of 11 cord lesions in five subjects imaged with the longer parameters (repetition time of 8000 to 11 000, TI of 2400 to 2600), three were not seen on FLAIR images, four were less conspicuous on FLAIR images, and four were seen equally or better on FLAIR images. **CONCLUSION:** Although successful in suppressing CSF signal and reducing imaging artifacts, fast FLAIR imaging appears unreliable in the detection of MS lesions in the spinal cord.

Index terms: Sclerosis, multiple; Spinal cord, magnetic resonance

AJNR Am J Neuroradiol 18:1035–1039, June 1997

Fluid-attenuated inversion-recovery (FLAIR) magnetic resonance (MR) imaging has proved to be a useful tool in the diagnosis of central nervous system (CNS) abnormalities. Successful uses of FLAIR imaging in the brain have been reported in cases of multiple sclerosis (MS), subarachnoid hemorrhage, encephalitis, cerebral infarction, surface tumors, and epilepsy (1–5). By selectively nulling cerebrospinal fluid (CSF) signal while maintaining a heavily T2-weighted image, FLAIR increases lesion conspicuity against a relatively gray parenchymal background and nulled CSF signal.

The FLAIR technique has particular theoretic

cal benefits in imaging of the spinal cord. By suppressing CSF signal, FLAIR sequences virtually eliminate pulsation and truncation artifacts that plague conventional fast spin-echo images. In addition, given the small size of the cord and surrounding bright CSF on conventional long-repetition-time (TR) images, FLAIR could theoretically provide an effective means for detecting parenchymal and surface lesions by increasing lesion conspicuity adjacent to nulled CSF signal. FLAIR also decreases partial volume effects between bright cord lesions and adjacent CSF on conventional long-TR images, potentially allowing better volumetric analysis of lesion burden and cord volume.

The purpose of this study was to evaluate the efficacy of fast FLAIR imaging of the spinal cord in a series of MS patients. By optimizing the FLAIR sequence and exploiting its theoretical advantages over conventional T2-weighted imaging, we hypothesized that FLAIR would be effective in the identification of MS lesions of the spinal cord.

Received July 31, 1996; accepted after revision January 7, 1997.

Funded in part by National Institutes of Health grants NS29029 and 5M01-RR00040–34.

From the Department of Radiology, Hospital of the University of Pennsylvania, 3400 Spruce St, Philadelphia, PA 19104. Address reprint requests to Robert I. Grossman, MD.

AJNR 18:1035–1039, Jun 1997 0195-6108/97/1806–1035

© American Society of Neuroradiology

Subjects and Methods

Fifteen patients (seven men and eight women) ranging in age from 25 to 64 years with known MS involving the spinal cord and brain by clinical parameters and previous conventional MR studies were imaged prospectively. None of the patients were on medical therapy or corticosteroids at the time of imaging. Two patients had clinical evidence of an acute MS exacerbation with clinical signs referable to a spinal cord lesion; the remaining 13 patients had quiescent disease.

Scanning was performed at 1.5 T with a phased-array coil. The spinal cord was imaged at a 3-mm section thickness in the sagittal plane with conventional T1-weighted spin-echo (500/17 [TR/echo time (TE)]), dual-echo fast spin-echo (3000/17,85 [TR/effective TE]; echo train length of 8), and fast FLAIR sequences.

The parameters of the FLAIR images varied as the study progressed and as the FLAIR sequence was optimized. To minimize CSF inflow effects, the width of the initial 180° inverting pulse was increased to 500% (15 mm) of the readout section thickness (3 mm). Since the thickness of the inversion pulse prevented interleaving section acquisitions through the small volume of the spinal canal, single-section acquisitions were used. This required four to five single-section acquisitions to cover the entire extent of the cord, except in patients with severe scoliosis.

The first 10 subjects were imaged with one of two TR/TI (repetition time/inversion time) combination sets (4000/1500 and 6000/2000). The final five patients were imaged with two TR/TI combination sets (8000–9000/2400–2600 and 11000/2600). All FLAIR sequences were obtained with TEs of 100 to 150, a 3-mm section thickness, a 512 × 512 matrix, and a 48-cm field of view. Images were obtained with two signal averages, an echo train length of eight, and a 32-kHz receiver bandwidth.

Consensus interpretations were reached by three radiologists with knowledge of the patients' clinical diagnoses. The fast spin-echo T2- and proton density-weighted images were considered reference images for the presence of abnormal cord signal indicating an MS lesion. The FLAIR sequences were evaluated for lesion detection, lesion conspicuity, and subjective measures of contrast-to-noise as compared with the conventional long-TR images. Lesions on FLAIR images were classified as follows: category 1, not visible or less conspicuous than on the fast spin-echo long-TR (conventional) images; category 2, seen equally well as on the conventional images; and category 3, more conspicuous than on the conventional images. A one-tailed sign test was used to assess whether the differences observed between the fast spin-echo and fast FLAIR sequences were statistically significant.

Results

In all patients, the fast FLAIR sequence was effective in nulling CSF signal in the central spinal canal, thereby substantially reducing pulsation and truncation artifacts. CSF nulling was

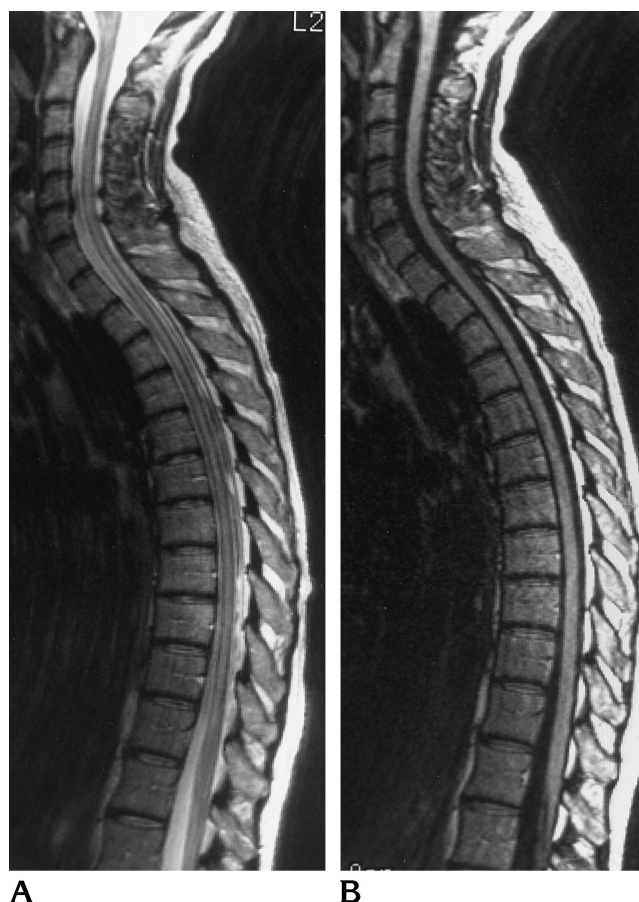

Fig 1. A 48-year-old woman with known MS lesion of the spinal cord.

Sagittal 3-mm fast spin-echo (3000/85/1 [TR/TE/excitations]) (A) and fast FLAIR (4000/102/1, TI of 1500) (B) images. Note the extensive pulsation and truncation artifacts limiting evaluation of the cord parenchyma for MS lesions on the fast spin-echo T2-weighted image. The FLAIR sequence largely eliminates confounding artifacts over the cord.

possible with all TR/TI imaging sets but was most reliable with the short TR/TI sets (4000/1500). CSF nulling in the basal cisterns was, however, variable, as has been the experience with FLAIR imaging in the brain. In all cases FLAIR images provided a subjectively improved anatomic evaluation of the cord as compared with fast spin-echo long-TR images, which were uniformly plagued with CSF pulsation and truncation artifacts (Fig 1).

Of the 30 lesions seen on fast spin-echo sequences, only five were seen equally or better on FLAIR images. This difference was statistically significant ($P = .0001$). Although the fast FLAIR sequence was technically successful in nulling CSF, initial imaging with short TR/TI (4000–6000/1500–2000) sequences had marked limitations for use in the identification of

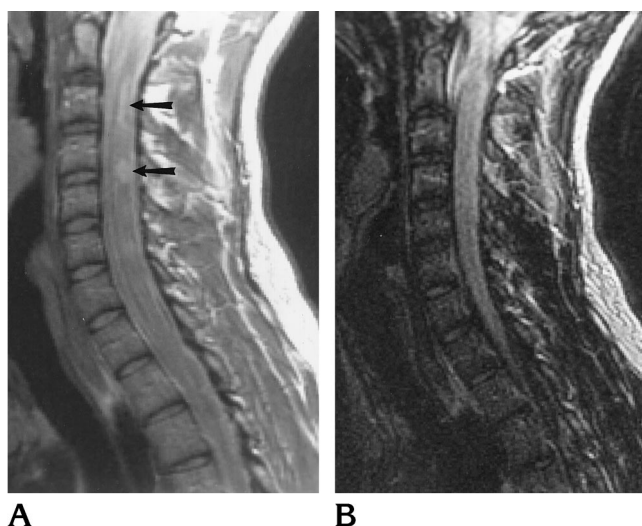


Fig 2. A 29-year old man with known cervical spinal cord MS lesions. Sagittal 3-mm fast spin-echo (2883/17/1) (A) and fast FLAIR (6000/150/1, TI of 2000) (B) images. Proton density-weighted image clearly shows two MS lesions of the cervical cord (arrows) that are not seen at all on the short-TR/TE FLAIR image.

MS lesions of the spinal cord. The fast FLAIR sequence was inferior to the long-TR fast spin-echo sequence in all 10 subjects imaged with the short TR/TI protocol. All three observers agreed that FLAIR images showed only one of 19 lesions with clarity equal to that on the fast spin-echo sequence ($P < .0001$). The remaining lesions were either not seen as well or not seen at all on FLAIR images (Fig 2).

To maximize T2 weighting of the FLAIR sequence and presumably improve visualization of MS lesions, the TR/TI sets were lengthened for the remaining five subjects in the study. CSF nulling was equally effective for TR/TI sets of 8000–9000/2400–2600 as for the longer TR/TI sets of 11 000/2600 without affecting lesion conspicuity. When scanning with single-section acquisitions, the longer TR/TI sets were slightly less reliable owing to longer imaging times and, therefore, increased degradation from motion artifacts.

Comparison was made between the optimized TR/TI (8000–9000/2400–2600) fast FLAIR sequence and the fast spin-echo sequences. Among the five subjects imaged, 11 lesions were seen on the fast spin-echo sequences. All three observers agreed that three of the 11 lesions were not seen on the FLAIR images and that four of the 11 were less conspicuous on the FLAIR images (Fig 3). Finally, four of the 11 lesions were seen either equally or

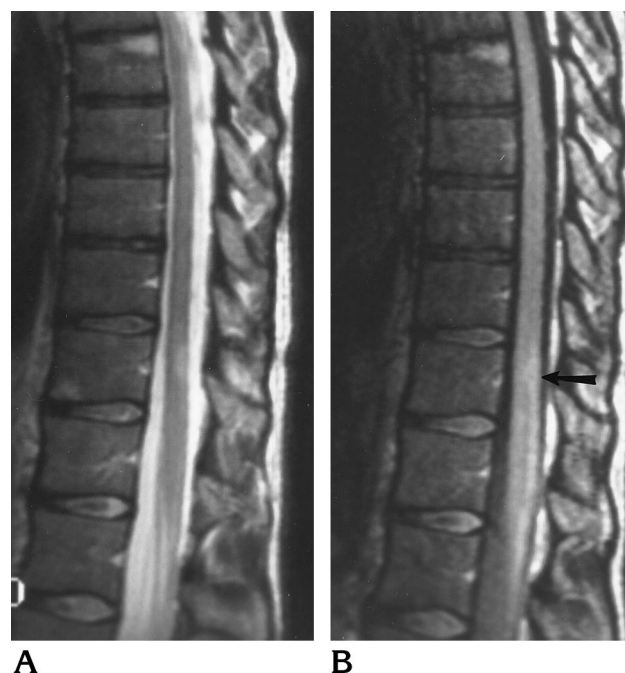

Fig 3. A 32-year-old woman with known MS lesions of the lower thoracic cord. Sagittal 3-mm fast spin-echo (2700/85/1) (A) and fast FLAIR (8000/102/1, TI of 2600) (B) images. The thoracic cord lesion is well seen on the conventional T2-weighted image, whereas only a suggestion of abnormal signal is seen on the FLAIR image in this location (arrow).

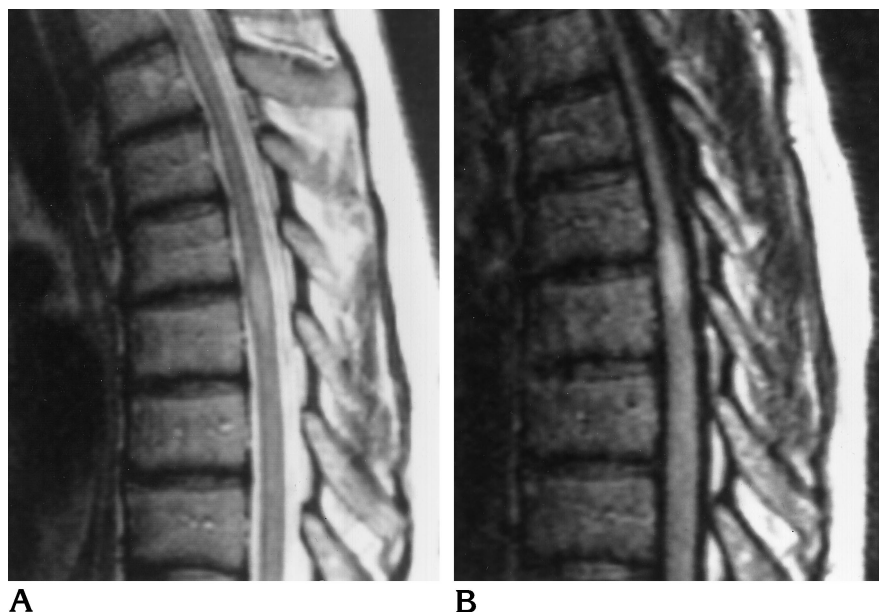
better on the FLAIR images (Fig 4). The differences observed between the fast spin-echo and the optimized fast FLAIR sequences were not statistically significant ($P = .02$).

Of those lesions seen equally or better on FLAIR images, two were in subjects who had acute clinical symptoms referable to the cord lesion. Both of these lesions enhanced on post-contrast images, confirming the clinical suspicion of acute disease. The remaining two seen equally or better on FLAIR images were sub-acute lesions that presented acutely several months before the MR examination and had been documented on previous MR studies. All seven lesions seen less conspicuously or not at all on FLAIR images were more than 1 year old, as documented on previous MR examinations and by clinical history.

Discussion

FLAIR imaging has been reported useful in the evaluation of a number of brain abnormalities (1–5). More recently, the use of FLAIR in spinal cord disease has been investigated with promising preliminary results in small series of

Fig 4. A 47-year-old woman with known MS and acute onset of Brown-Séquard syndrome. Sagittal 3-mm fast spin-echo (2700/85/1) (A) and fast FLAIR (8000/102/1, TI of 2600) (B) images. Both sequences show this acute lesion in the midthoracic cord equally well.



patients (6, 7). Specifically, the FLAIR technique has been shown to be superior to conventional spin-echo imaging in the evaluation of MS lesions within the brain and spinal cord (1, 6, 8). A single sequence that improves identification of lesions and reduces artifacts that interfere with volumetric analysis would be invaluable in the assessment of total lesion burden in patients with MS.

Despite the initial promising results of spinal cord imaging with FLAIR described in the literature, our study revealed significant limitations of the FLAIR sequence for use in identifying MS lesions within the cord.

The problems we encountered may represent a technical failure of our fast FLAIR sequence. The main benefit of FLAIR imaging in the spinal cord is its ability to produce a heavily T2-weighted image while simultaneously suppressing adjacent CSF signal, thereby increasing lesion contrast and detectability. To maximize T2-weighting in a FLAIR sequence, long TIs up to the theoretical maximum (2900 on 1.5-T units) are required to minimize T1 effects (8). Images with TIs close to the theoretical maximum benefit were obtained with our fast FLAIR sequence. CSF nulling and artifact reduction were maximized with single-section acquisitions and wide (500% section thickness) inversion pulses. Image quality was maximized with a high-resolution matrix (512×512) and intermediate echo train length (eight). Despite all these corrective measures, the imaging power

of FLAIR proved inferior to fast spin-echo sequences.

Contrast in FLAIR imaging is highly dependent on the TI selected. Longer TIs minimize T1 effects and maximize T2-weighted contrast. FLAIR imaging uses the relatively slow relaxation curve of CSF to produce selective nulling of CSF signal. In addition, with long TIs, differences in T1 relaxation between cord parenchyma and cord lesions should be minimized, thus optimizing T2 effects. The poor visibility of lesions on FLAIR images as compared with conventional T2-weighted images suggests that T1 effects predominated in our FLAIR sequence. The reason for this is uncertain, given our corrected and optimized FLAIR parameters.

This study clearly reveals the limitations of short TR/TI times in FLAIR imaging. In addition to the negative effects on T2-weighting, shorter relaxation times and TIs (4000/1500 [TR/TI]) prevent complete relaxation of spins before the initiation of the next 180° inversion pulse. In effect, this broadens the null point at the 90° radio-frequency pulse, which initiates the fast spin-echo portion of the sequence. Thus, tissues other than CSF may be at or near the null point during the 90° radio-frequency pulse. This may cause tissues such as the MS plaque to be nulled or to lose signal relative to adjacent parenchyma. The longer TR/TI combination sets allow more complete relaxation of spins before the next 180° inversion pulse, thereby produc-

ing a sharp null point at which only free fluid is selectively nulled.

The majority of cord lesions scanned in this series were chronic, and the FLAIR sequence was particularly unsuccessful in imaging these lesions. On the other hand, all acute and subacute MS lesions were seen well on FLAIR images. Although the number of acute and chronic lesions scanned with the optimal FLAIR protocol in this study was statistically insufficient to enable definitive conclusions to be drawn, our findings suggest that chronic MS lesions in the cord may have relaxation values similar to those of adjacent cord parenchyma and therefore lose conspicuity within the cord. This would also explain the superiority of fast spin-echo sequences, which may not be as heavily dependent on T1 relaxation effects.

Although this theory seems plausible, it does not explain the reported success of imaging of pathologically similar MS lesions in the brain. On the other hand, no truly controlled studies comparing FLAIR and conventional imaging in the brain in a variety of MS patients have been performed to document clear superiority of FLAIR imaging. Further investigations of the imaging power of FLAIR in MS lesions of the brain are needed. Moreover, additional evaluation of the relative T1 and T2 relaxation rates of CSF, spinal cord parenchyma, and MS lesions in the spinal cord is necessary to determine whether these differences can account for the observed loss of conspicuity of the lesions on the FLAIR images in this study.

If FLAIR imaging ultimately proves successful and reliable in imaging MS lesions in the spinal cord, lesion detectability in the spinal cord parenchyma should improve, as it has in the brain. Within the cord, there is particular benefit for identifying surface lesions, which are suboptimally seen on conventional fast spin-echo images because of the adjacent high-intensity CSF signal. In addition, if a sensitive FLAIR technique were developed for spinal cord

imaging, accurate quantitative analysis of spinal cord lesion burden by computer techniques would be facilitated.

In conclusion, fast FLAIR imaging in the spinal cord is successful in nulling CSF and reducing imaging artifacts while maintaining heavily T2-weighted imaging to evaluate the cord parenchyma; however, the fast FLAIR sequences used in this study proved unreliable for detecting MS lesions in the spinal cord, particularly in the chronic phase of the disease. Although further optimization of the fast FLAIR sequence for cord imaging could provide explanations for the limitations we encountered, the results from this study suggest a paradox. Despite its obvious sensitivity for MS lesions in the brain, FLAIR imaging of MS lesions in the spinal cord is less sensitive than fast spin-echo long-TR imaging. This problem merits further investigation.

References

1. Hashemi RH, Bradley WG Jr, Chen DY, et al. Suspected multiple sclerosis: MR imaging with a thin-section fast FLAIR pulse sequence. *Radiology* 1995;196:505-510
2. Noguchi K, Ogawa T, Inugami A, et al. Acute subarachnoid hemorrhage: MR imaging with fluid-attenuated inversion recovery pulse sequences. *Radiology* 1995;196:773-777
3. White ML, Edwards-Brown MK. Fluid attenuated inversion recovery (FLAIR) of herpes encephalitis. *J Comput Assist Tomogr* 1995;19:501-505
4. Hajnal JV, Bryant DJ, Kasuboski L. Use of fluid attenuated recovery (FLAIR) pulse sequences in MRI of the brain. *J Comput Assist Tomogr* 1992;16:841-844
5. Bergin PS, Fish DR, Shorvon SD, Oatridge A, deSouza NM, Bydder GM. Magnetic resonance imaging in partial epilepsy: additional abnormalities shown with fluid attenuated inversion recovery (FLAIR) pulse sequence. *J Neurol Neurosurg Psychiatry* 1995;58:439-443
6. Hajnal JV, Kasuboski L, deSouza NM, Bydder GM. Magnetic resonance imaging: spinal cord imaging with turbo-fluid attenuated inversion recovery (FLAIR) pulse sequence. *Clin Radiol* 1995;50:1-5
7. White SJ, Hajnal JV, Young IR, Bydder GM. Use of fluid-attenuated inversion-recovery pulse sequences for imaging the spinal cord. *Magn Reson Med* 1992;28:153-162
8. Rydberg JN, Hammond CA, Grimm RC. Initial clinical experience in MR imaging of the brain with a fast fluid-attenuated inversion-recovery pulse sequence. *Radiology* 1994;193:173-180