

Are your MRI contrast agents cost-effective?

Learn more about generic Gadolinium-Based Contrast Agents.



**FRESENIUS
KABI**

caring for life

AJNR

**MR of the spinal cord in multiple sclerosis:
relation to clinical subtype and disability.**

G J Lycklama à Nijeholt, F Barkhof, P Scheltens, J A
Castelijns, H Adèr, J H van Waesberghe, C Polman, S J
Jongen and J Valk

This information is current as
of April 10, 2024.

AJNR Am J Neuroradiol 1997, 18 (6) 1041-1048

<http://www.ajnr.org/content/18/6/1041>

MR of the Spinal Cord in Multiple Sclerosis: Relation to Clinical Subtype and Disability

Geert J. Lycklama à Nijeholt, Frederik Barkhof, Philip Scheltens, Jonas A. Castelijns, Herman Adèr, Jan Hein van Waesberghe, Chris Polman, Sjef J. H. Jongen, and Jaap Valk

PURPOSE: To determine whether the MR appearance of the spinal cord in patients with multiple sclerosis (MS) differs according to clinical subtype. **METHODS:** The spinal cords of 20 healthy control subjects and 60 patients with MS (22 with relapsing-remitting disease, 22 with secondary-progressive disease, and 16 with primary-progressive disease) were examined with sagittal dual-echo spin-echo MR imaging and with axial T2*-weighted gradient-echo MR imaging. Two interpreters scored the images for focal lesions and for diffuse abnormalities. Cross-sectional areas of the cords were measured at the C-2 level. **RESULTS:** No abnormalities were found in any of the control subjects nor in two of the patients. Fifty (83%) of 60 patients had focal lesions. Diffuse abnormality and focal lesions were found in 50% of patients with secondary-progressive MS, in 25% of patients with primary-progressive disease, and in 18% of patients with relapsing-remitting disease. Diffuse abnormality without focal lesions was found in seven patients with primary-progressive MS and in one patient with secondary-progressive MS. Patients with diffuse abnormalities had a smaller cross-sectional area of the spinal cord and they suffered from more disability than did patients without diffuse abnormalities. **CONCLUSION:** The MR appearance of the spinal cord differs among clinical subgroups of MS. Diffuse abnormality of the spinal cord is associated with a progressive clinical course and greater disability.

Index terms: Sclerosis, multiple; Spinal cord, magnetic resonance

AJNR Am J Neuroradiol 18:1041-1048, June 1997

Reports of magnetic resonance (MR) imaging studies of the spinal cord in patients with multiple sclerosis (MS) usually describe the presence of focal lesions (1-5), which are often associated with sensory or motor symptoms (6, 7). However, a correlation between focal spinal cord lesions and degree of disability has not been found (1). Furthermore, the number of

spinal cord lesions is not different between the relapsing-remitting and the progressive subgroups of MS (1, 8). Apart from focal lesions, previous MR studies have mentioned the presence of generalized spinal cord atrophy in patients with MS (2). On axial MR images, spinal cord atrophy appears as a smaller cross-sectional area of the cord (1, 9), and it correlates well with measures of disability. The presence of spinal cord atrophy helps in the identification of clinical subgroups of MS, because it is associated with the progressive subgroups (1, 8, 10). Since cord atrophy in MS probably represents generalized pathologic changes, such as axonal loss (9) or (secondary) gliosis, it may be expected that it is associated with diffuse signal changes on MR images. We investigated the occurrence of diffuse spinal cord abnormalities on MR images in patients with MS to determine whether the presence of diffuse abnormalities, apart from focal lesions, helps explain the clinical course and degree of disability.

Received September 13, 1996; accepted after revision December 19.

Supported by the Dutch MS Society, grant 92-131. The Dutch MR Center for MS Research is sponsored by the Vrije Universiteit, Vrije Universiteit Hospital, and the Dutch MS Society.

From the Departments of Radiology (G.J.L.N., F.B., J.A.C., J.H.V.W., J.V.) and Neurology (P.S., C.P.), Dutch MR Center for MS Research, Vrije Universiteit Hospital, Amsterdam; the Department of Epidemiology and Biostatistics, Vrije Universiteit, Amsterdam (H.A.); and the Institute for Neurology, University Hospital, Nijmegen (S.J.H.J.); the Netherlands.

Address reprint requests to G. J. Lycklama à Nijeholt, Department of Diagnostic Radiology, Vrije Universiteit Hospital, De Boelelaan 1117, 1081 HV Amsterdam, the Netherlands.

AJNR 18:1041-1048, Jun 1997 0195-6108/97/1806-1041

© American Society of Neuroradiology

Patients and Methods

Sixty consecutive patients who fulfilled the Poser criteria of clinically definite MS (11) were recruited from the outpatient clinic of our institution's department of neurology. Participating neurologists were asked to refer patients from both the relapsing-remitting and progressive-clinical subgroups. Each patient gave informed consent for the MR and neurologic examinations after the nature of the procedures was fully explained. In addition, we enlisted 20 healthy control subjects with a similar age and sex distribution as that of the patients.

Patients were examined by one neurologist who was unaware of the MR imaging findings, and they were divided into three clinical subgroups, as defined by Lublin and Reingold (12) on the basis of clinical history. According to this definition, relapsing-remitting MS is characterized by clearly defined acute attacks with full recovery or with sequelae and residual deficit upon recovery. Periods between relapses are characterized by lack of disease progression. Secondary-progressive MS begins with an initial relapsing-remitting course, followed by progression of variable rate, which may also include occasional relapses and minor remissions. Primary-progressive MS is characterized by progression of disability from onset, without plateaus or remissions, or with occasional plateaus and temporary minor improvement. Twenty-two patients had relapsing-remitting MS, 22 had secondary-progressive MS, and 16 had primary-progressive MS.

Disability was assessed according to the Expanded Disability Status Scale (EDSS) (13) and the Functional Systems Scale (14).

MR Imaging

MR imaging of the spinal cord was performed at 1.0 T using a spinal phased-array coil. Sagittal sections (3 mm thick with a 10% intersection gap) were acquired using a conventional cardiac-triggered conventional spin-echo sequence (2200/20,80/1 [repetition time/echo time/excitations]), including a 240×480 -mm field of view and a 256×512 matrix. Acquisition time was approximately 10 minutes. Also, one section perpendicular to the cervical spinal cord (5 mm thick) was acquired at the cervical C-2 level using a T2*-weighted fast low-angle shot sequence (620/20/4) with a 20° flip angle, a 200×120 -mm field of view, and a 256×130 -mm matrix. Acquisition time was approximately 6 minutes. On the resulting image, the cross-sectional area of the spinal cord was measured by one observer who was unaware of the clinical parameters and blinded to the findings on the sagittal MR images. The cross-sectional area was measured at the C-2 level because at that level the spinal cord is usually surrounded by cerebrospinal fluid (CSF). Area calculations were performed with home-developed software using a local thresholding technique.

Sagittal MR images of patients and control subjects were scored by two neuroradiologists separately, both of whom were unaware of clinical data. The proton density-

and T2-weighted images of each patient were scored simultaneously. Focal lesions were defined as sharply demarcated areas of high signal intensity visible on the proton density-weighted images and on the corresponding T2-weighted images. Focal lesion load was defined as the total longitudinal extent of lesions (number of vertebrae) on sagittal proton density- and T2-weighted images. Diffuse abnormality of the spinal cord was recorded if the proton density-weighted image showed the spinal cord (both cervical and thoracolumbar levels) to have higher signal intensity than surrounding CSF while the corresponding T2-weighted image showed a homogeneously increased signal intensity at the corresponding levels, without demarcated lesions. In cases of disagreement, the readers reviewed the MR images until they reached a consensus. Sagittal imaging findings were used to classify patients into three groups: I, patients with only focal lesions; II, patients with focal lesions and diffuse abnormalities of the spinal cord; and III, patients with diffuse abnormalities and no focal lesions. The repetition time of the dual-echo images did not differ among patients with type I, II, or III MR findings.

Contrast measurements were obtained on midsagittal proton density- and T2-weighted images of all patients and control subjects. With the use of software present on a computer workstation, regions of interest were drawn in the CSF (posterior to vertebral at the C-1 level) and in the spinal cord tissue (at vertebral level C-1), and the contrast ratio was calculated by dividing the signal intensity of spinal cord tissue by the signal intensity of CSF. Signal intensity measurements in the spinal cord and CSF were obtained at the C-1 level because the CSF space was largest there. At other vertebral levels, there was little visible CSF, introducing the possibility of partial volume averaging.

Statistics

Comparisons between subtypes of MS and different types of MR abnormalities were made by using Student's *t* test for normally distributed data; the Mann-Whitney *U* test was used for nonparametric data. The effect of diffuse abnormalities of the spinal cord on the EDSS score (dependent variable) was studied in a multiple regression model, with corrections made for focal lesion load and disease duration (independent variables). Correlations were calculated with Spearman's rank correlation coefficient.

Results

The readers disagreed in seven of 80 MR studies before reaching a consensus. These seven studies consisted of the following: one in which one reader found no abnormalities and the other recorded one focal lesion; four in which one reader recorded focal lesions only

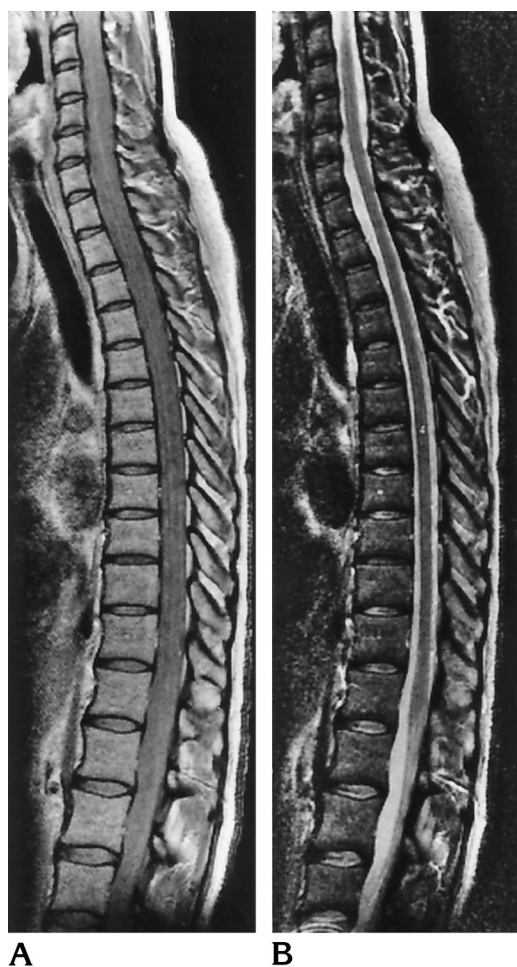

Fig 1. No abnormalities. Sagittal proton density-weighted (A) and T2-weighted (B) MR images (2200/20,80/1) of a healthy control subject show no lesions in the spinal cord. The spinal cord and the CSF have equal signal intensity on the proton density-weighted image.

(type I MR findings) and the other also found diffuse abnormalities (type II findings), and two in which one reader recorded both diffuse abnormalities and focal lesions (type II findings) and the other recorded only diffuse abnormalities (type III findings).

Presence of Focal Lesions and/or Diffuse Abnormalities

No abnormalities were found in the spinal cords of any of the 20 volunteers or in two (3%) of the 60 patients (Fig 1). Type I MR findings were seen in 32 (53%) of the patients (Fig 2), type II findings in 18 (30%) of the patients (Fig 3), and type III findings in eight (13%) of the patients (Fig 4). In total, 50 (83%) of 60 MS

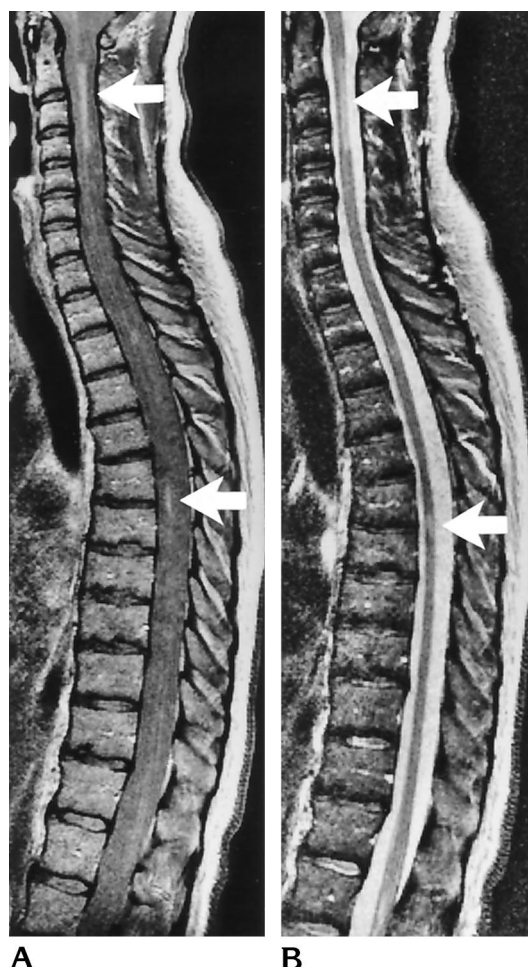


Fig 2. Type I MR finding. Sagittal proton density-weighted (A) and T2-weighted (B) MR images (2200/20,80/1) of a patient with relapsing-remitting MS show only focal lesions (arrows) in the spinal cord. Apart from the focal lesions, the spinal cord and CSF have the same signal intensity on the proton density-weighted image.

patients had focal lesions (Table 1). Patients with type II MR findings had more focal lesions than patients with type I findings ($P < .05$, Table 2).

Presence of diffuse abnormalities was associated with primary or secondary progressive disease (Table 1). While diffuse abnormalities occurred in only four (18%) of 22 patients with relapsing-remitting disease, it was recorded in 11 (50%) of 22 patients with secondary-progressive MS and in 11 (69%) of 16 patients with primary-progressive MS. The eight patients with type III MR findings (only diffuse abnormalities) included seven with primary-progressive MS and only one with secondary-progressive MS. The association of diffuse abnormalities with primary or secondary progressive type dis-

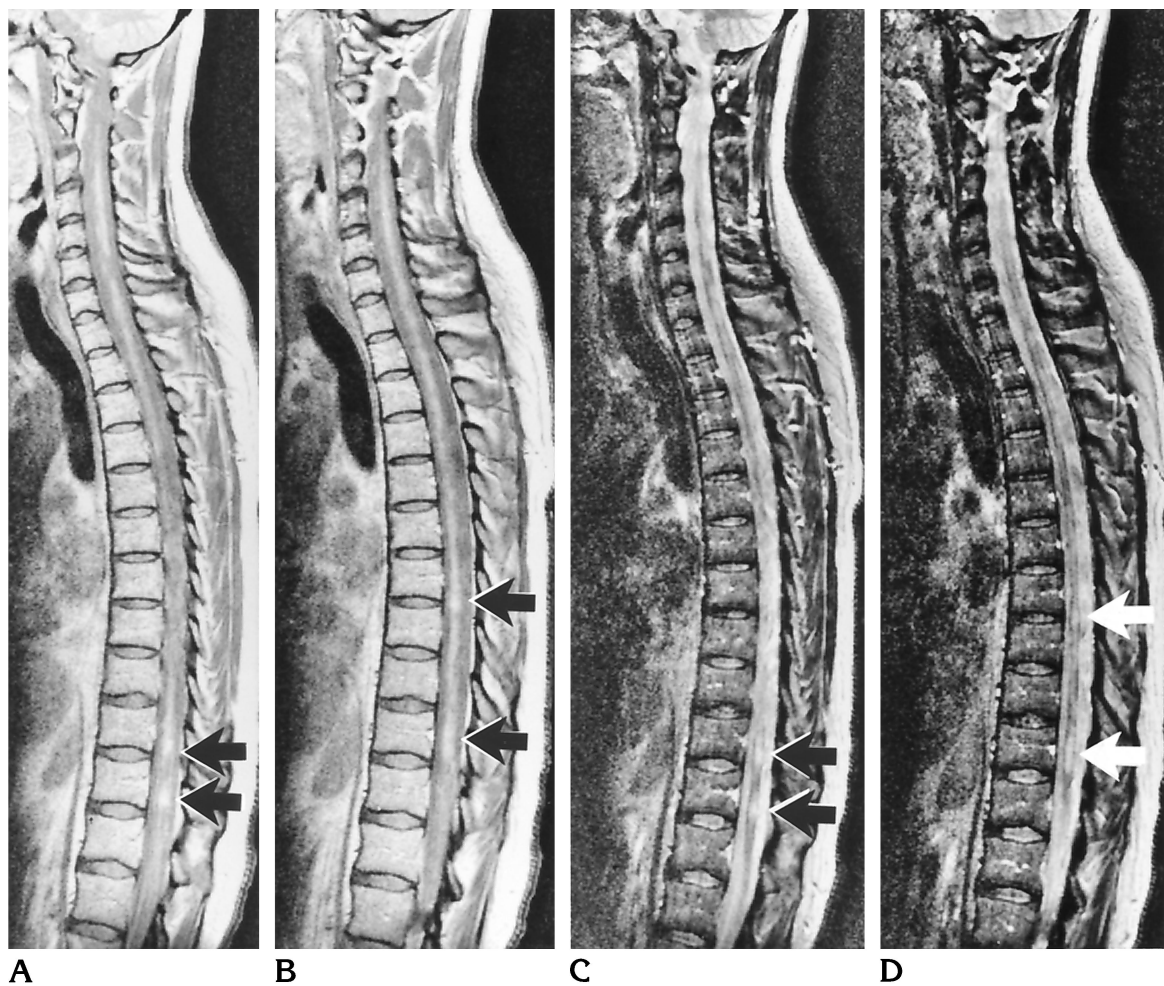


Fig 3. Type II MR finding. Sagittal proton density-weighted (A, B) and T2-weighted (C, D) MR images (2200/20,80/1) of a patient with secondary progressive MS show multiple focal lesions (arrows), especially on the T2-weighted images. On the proton density-weighted images, the spinal cord appears diffusely involved, including areas in which there are no focal lesions on the corresponding T2-weighted image.

ease was statistically significant ($P < .001$, Table 1).

Correlation between MR Appearance and Clinical Measures

Duration of disease was approximately equal among patients with types I, II, or III MR findings (Table 2). Correlation between focal lesion load and EDSS score did not reach statistical significance (Spearman's coefficient = .25, $P = .06$).

The cross-sectional area of the spinal cord at the C-2 level was smaller in patients with type II and III MR findings than in patients with type I findings ($P < .01$, Table 2). Correlation between the cross-sectional area of the spinal cord and EDSS score was statistically significant (Spearman's coefficient = $-.28$, $P = .046$).

Irrespective of clinical subgroup, the median EDSS score of patients with diffuse abnormalities of the spinal cord (type II or III MR findings) was higher ($P < .05$) than that of patients who had only focal lesions (type I findings, Table 2). Of the 22 patients with secondary-progressive MS, those 11 who had diffuse abnormalities (type II or III findings) had higher EDSS scores (median, 6.0; range, 1.5 to 6.5) than did the 11 patients with secondary-progressive MS who had only focal lesions (median EDSS score, 4.5; range, 2 to 7). Median scores for patients with pyramidal tract, bowel and bladder, and sensory symptoms (as measured on the Functional Systems Scale) were significantly higher among those with type II or III MR findings than for those with type I MR findings ($P < .01$, Table 2).

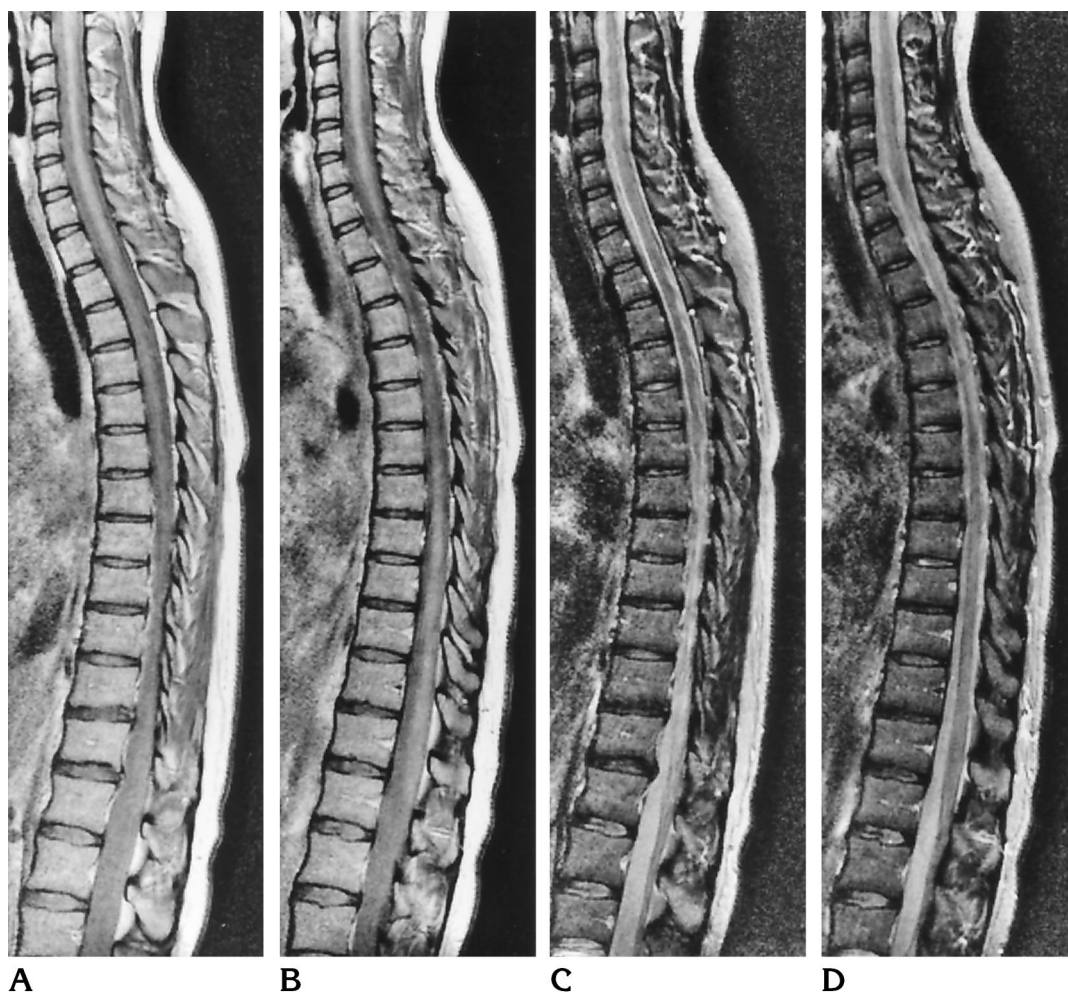


Fig 4. Type III MR finding. Sagittal proton density-weighted (A, B) and T2-weighted (C, D) MR images (2200/20,80/1) of a patient with primary progressive MS: the spinal cord shows diffuse involvement on the proton density-weighted images, whereas no focal lesions are visible on the corresponding T2-weighted images.

To correct for focal lesion load and disease duration as confounding factors associated with a higher EDSS score, a multiple regression analysis was performed (Table 3). First, in a bivariate model, results showed that diffuse abnormalities of the spinal cord (type II or III MR findings) are significantly associated with higher EDSS scores. Then, in a multivariate model, after correcting for disease duration and focal lesion load, the association of diffuse abnormalities with higher EDSS score remained statistically significant.

Contrast Measurements

Mean contrast between spinal cord tissue and CSF was significantly higher in patients with type II or III MR findings than in patients with type I findings ($P < .05$, Table 4). This differ-

ence was found on both the proton density- and T2-weighted images (Table 4). Signal intensity of CSF was not statistically different among patients with MR types I, II, or III (Table 4).

Discussion

Apart from focal lesions, we found diffuse abnormalities of the spinal cord in 43% of our patients. Clinical relevance of this finding is evidenced by the associated clinical impairment, the progressive MS subgroups, and the cervical cord atrophy. Previous MR studies have shown that abnormalities in the cord may be found in 75% of MS patients (1–4) and that this percentage may be even higher in patients with spinal cord symptoms (5). The abnormalities described in those studies consisted mainly of focal lesions, less than one vertebral body in

TABLE 1: Distribution of clinical subtypes of MS over three types of finding on MR images of the spinal cord

MS Type	Type of MR Finding*			Total
	I	II	III	
Relapsing-remitting	17	4	...	21
Secondary-progressive	10	10	1	21
Primary-progressive	5	4	7	16
Total	32	18	8	58

Note.—Two of 60 patients (one with relapsing-remitting MS and one with secondary-progressive MS) had a normal appearance of the spinal cord and are not represented in this table. $\chi^2 = 220$, $df = 4$, $P = .0002$.

* MR type I: focal lesions, no diffuse abnormality on sagittal images; MR type II: focal lesions plus diffuse abnormality of the spinal cord on sagittal images; MR type III: diffuse abnormality of the spinal cord, no focal lesions.

TABLE 2: Comparison between clinical parameters and type of MR finding

Clinical Parameter	Type of MR Finding*		
	I (n = 32)	II (n = 18)	III (n = 8)
Disease duration, y	7 (0–30)	7 (2–25)	6 (1–13)
Focal lesion load, segments	2.5 (0.5–7.5)	6 (0–11) [†]	... [‡]
Cross-sectional area at level of C-2, mm ²	82 (55–99) [§]	72 (59–90)	70 (52–86)
EDSS	2.0 (0–7) [§]	5 (1–6.5)	5 (2–7)
FSS symptoms			
Pyramidal tract	1 (0–5)	3 (0–4)	3 (1–5)
Bowel and bladder	1 (0–2)	2 (0–4)	2 (0–4)
Sensory	0 (0–4)	1 (0–3)	2 (0–3)

Note.—All values are expressed as medians with the range in parentheses. Test statistic: Mann-Whitney U test. EDSS indicates Extended Disability Status Scale; FSS, Functional Systems Scale.

* MR type I: focal lesions, no diffuse abnormality on sagittal images; MR type II: focal lesions plus diffuse abnormality of the spinal cord on sagittal images; MR type III: diffuse abnormality of the spinal cord, no focal lesions.

[†] $P < .01$ MR type II versus MR type I.

[‡] By definition, type III MR finding does not show focal lesions.

[§] $P < .05$ MR types II and III versus MR type I.

^{||} $P < .01$ MR types II and III versus MR type I.

length and commonly located in the cervical cord. In our study, we found focal lesions in 83% and diffuse abnormalities in 43% of patients with MS. When both focal lesions and diffuse abnormalities were considered, we found abnormalities in all but two (97%) of 60 patients. The high prevalence of spinal cord abnormalities in our patients may partly be due to patient selection, since we attempted to select patients from all

TABLE 3: Multiple regression analysis: influence of presence of diffuse abnormalities on Extended Disability Status Scale (EDSS) score

Variable	Dependent: EDSS Score			
	Coefficient	SE	Partial Correlation	P
Bivariate ($r^2 = .11$)				
Diffuse abnormality*	1.51	.60	.33	.01
Multivariate ($r^2 = .23$)				
Diffuse abnormality [†]	1.26	.58	.33	.03
Disease duration, y [‡]	0.08	.04	.28	.04
Focal lesion load	0.18	.10	.31	.08

Note.—SE indicates standard error of coefficient.

* The presence of diffuse abnormality (MR type II or III finding) is associated with a higher EDSS score.

[†] After correcting for disease duration and focal lesion load, this effect becomes somewhat weaker, but remains statistically significant.

[‡] Longer disease duration is associated with an increase in EDSS score.

three clinical subgroups. Although the patients were not selected for spinal cord symptoms, this may have led to overrepresentation of the progressive subtypes of MS, which are associated with more disabilities.

The discrepancy between previous reports and our findings can be explained as follows: First, the spinal phased-array coil has enabled us to evaluate the whole spinal cord on one MR image, which enables better detection of abnormalities that extend throughout the cord. Second, in contrast to previous studies, our study used both proton density- and T2-weighted imaging sequences. Owing to low signal intensity of CSF on proton density-weighted images, diffuse signal intensity changes in the spinal cord parenchyma are easier to interpret. On T2-weighted images, diffuse signal increase may be more difficult to appreciate because of the possibility of partial volume averaging of CSF (15). Third, in recent studies, fast spin-echo sequences were applied (1, 16). With fast spin-echo, CSF signal is often not homogeneous because of flow artifacts. Furthermore, contrast on fast spin-echo MR images may be modulated by many factors, such as echo train length and echo spacing (17). Indeed, it has been suggested that subtle changes in the spinal cord may be missed when applying fast spin-echo sequences (18, 19).

The clear association of diffuse abnormalities with progressive MS, and the fact that diffuse abnormalities were not found in healthy control subjects, suggests that our findings are not attributable to MR artifacts. Theoretically, the ap-

TABLE 4: Contrast measurements on sagittal dual-echo spin-echo MR images of the spinal cord in patients with MS and control subjects

	Proton Density-Weighted Images			T2-Weighted Images		
	SI/Cord	SI/CSF	Ratio	SI/Cord	SI/CSF	Ratio
Control group (n = 20)	834 (325)	818 (331)	1.03 (0.08)	309 (82)	560 (146)	.55 (.05)
MR type I (n = 32)	896 (287)	856 (288)	1.03 (0.12)	327 (80)	590 (105)	.56 (.01)
MR type II (n = 18)	1000 (326)*	854 (283)	1.18 (0.15) [†]	375 (94) [†]	592 (125)	.63 (.02)*
MR type III (n = 8)	1058 (297) [†]	832 (329)	1.33 (0.22)*	376 (107)	611 (183)	.62 (.02) [†]

Note.—All values are expressed as means with the standard deviation in parentheses. Test statistic: Student's *t* test. SI indicates signal intensity; CSF, cerebrospinal fluid; ratio, SI of cord tissue divided by SI of CSF; MR type I, focal lesions, no diffuse abnormality on sagittal images; MR type II, focal lesions plus diffuse abnormality of spinal cord on sagittal images; MR type III, diffuse abnormality of the spinal cord, no focal lesions.

* *P* < .01, as compared with MR type I group and control group.

[†] *P* < .05, as compared with MR type I group and control group.

plication of cardiac triggering may have introduced differences in repetition time, possibly influencing spinal cord-CSF contrast; however, repetition time was not different between the groups of patients with and without diffuse abnormalities. Again, cord atrophy could theoretically have caused signal difference between spinal cord and CSF owing to a change in signal intensity of the CSF, but this is unlikely, since signal intensity of CSF was almost equal among the groups, and contrast between spinal cord and CSF was determined by the signal intensity of the spinal cord.

Since we did not study these spinal cord abnormalities over time, we can only speculate on the exact mechanism of development of diffuse abnormalities. Multiple focal lesions may combine and eventually develop into diffuse abnormalities; however, this is unlikely, since in this study diffuse abnormalities had a different MR appearance than focal lesions, and these two types of abnormality could be differentiated on the MR images. Alternatively, diffuse changes may develop apart from focal lesions. This could be either as a result of focal lesions, as in wallerian degeneration after cord injury, or due to diffuse MS involvement of the spinal cord. The latter possibility is suggested by the eight patients (of whom seven had primary-progressive MS) who had no focal lesions even while the spinal cord was diffusely involved.

What is the histopathologic abnormality underlying diffuse abnormalities of the spinal cord in MS? Histopathologic studies of MS in the spinal cord have emphasized the occurrence of focal areas of demyelination that correspond to focal lesions on MR images (20–23). Diffuse cord tissue changes have also been described in these studies: in one investigation, the presence of generalized atrophy, caused by “axonal de-

struction” or “secondary degeneration of the long tracts” was mentioned (21). In another study (22), gliotic changes were present throughout the spinal cord. Therefore, diffuse abnormalities may be explained by pathologic abnormalities other than focal demyelination; and this could include axonal loss and/or gliosis, which results in cord atrophy. In relapsing-remitting MS, diffuse abnormalities seem to be rare, and most patients with relapsing-remitting MS have only focal lesions. However, the finding of diffuse abnormalities on spinal MR images may have consequences for diagnosing primary-progressive MS, because the brain MR images in these patients show relatively few lesions (24).

In summary, our study shows that diffuse abnormalities of the spinal cord are a common finding in the progressive types of MS. The presence of diffuse abnormalities on MR images has clinical relevance and, in addition, suggests the histopathologic findings of axonal loss and secondary gliosis, both of which are associated with disease progression. Further studies should focus on the relationship between brain abnormalities and the development of diffuse abnormalities of the spinal cord over time.

Acknowledgments

We thank B. M. J. Uitdehaag and O. R. Hommes for allowing us to study their patients, and Karin Barbiers for her help with scanning.

References

1. Kidd D, Thorpe JW, Thompson AJ, et al. Spinal cord MRI using multi-array coils and fast spin echo, II: findings in multiple sclerosis. *Neurology* 1993;43:2632–2637
2. Honig LS, Sheremata WA. Magnetic resonance imaging of spinal cord lesions in multiple sclerosis. *J Neurol Neurosurg Psychiatry* 1989;52:459–466

3. Tartaglino LM, Friedman DP, Flanders AE, Lublin FD, Knobler RL, Liem M. Multiple sclerosis in the spinal cord: MR appearance and correlation with clinical parameters. *Radiology* 1995;195:725-732
4. Thielen KR, Miller GM. Multiple sclerosis of the spinal cord: magnetic resonance appearance. *J Comput Assist Tomogr* 1996;20:434-438
5. Schneider U, Wullenweber M, Hrastrnik K, Hatje G, Hagenah R. Kernspintomographische untersuchung bei multipler sklerose. *Nervenarzt* 1995;66:129-132
6. Wiebe S, Lee DH, Karlik SJ, et al. Serial cranial and spinal cord magnetic resonance imaging in multiple sclerosis. *Ann Neurol* 1992;32:643-650
7. Turano G, Jones SJ, Miller DH, DuBoulay GH, Kakigi R, McDonald WI. Correlation of SEP abnormalities with brain and cervical cord MRI in multiple sclerosis. *Brain* 1991;114:663-681
8. Kidd D, Thorpe JW, Kendall BE, et al. MRI dynamics of brain and spinal cord in progressive multiple sclerosis. *J Neurol Neurosurg Psychiatry* 1996;60:15-19
9. Losseff NA, Webb SL, O'Riordan JI, et al. Spinal cord atrophy and disability in multiple sclerosis: a new reproducible and sensitive MRI method with potential to monitor disease progression. *Brain* 1996;119:701-708
10. Filippi M, Campi A, Colombo B, et al. A spinal cord MRI study of benign and secondary progressive multiple sclerosis. *J Neurol* 1996;243:502-505
11. Poser CM, Paty DW, Scheinberg L, McDonald WI, Davis FA, Ebers GC. New diagnostic criteria for multiple sclerosis: guidelines for research protocols. *Ann Neurol* 1983;13:227-231
12. Lublin FD, Reingold SC. Defining the clinical course of multiple sclerosis: results of an international survey. *Neurology* 1996;46:907-911
13. Kurtzke JF. Rating neurologic impairment in multiple sclerosis: an expanded disability status scale (EDSS). *Neurology* 1983;33:1444-1452
14. Kurtzke JF. On the evaluation of disability in multiple sclerosis. *Neurology* 1961;11:686-694
15. Lycklama à Nijeholt GJ, Barkhof F, Castelijns JC, et al. Comparison of two MR sequences in the detection of multiple sclerosis lesions of the spine. *AJNR Am J Neuroradiol* 17:1533-1538
16. Thorpe JW, Kidd D, Moseley IF, et al. Serial gadolinium-enhanced MRI of the brain and spinal cord in early relapsing-remitting multiple sclerosis. *Neurology* 1996;46:373-378
17. Sze G, Kawamura Y, Negishi C, et al. Fast spin-echo MR imaging of the cervical spine: influence of echo train length and echo spacing on image contrast and quality. *AJNR Am J Neuroradiol* 1993;14:1203-1213
18. Hittmair K, Mallek R, Prayer D, Schindler EG, Kollegger H. Spinal cord lesions in patients with multiple sclerosis: comparison of MR pulse sequences. *AJNR Am J Neuroradiol* 1996;17:1555-1565
19. Bianco F. Is fast spin-echo superior to gradient-echo imaging in detecting spinal cord lesions...or not? *AJNR Am J Neuroradiol* 1996;17:194
20. Nagao M, Ogawa M, Yamauchi H. Postmortem MRI of the spinal cord in multiple sclerosis. *Neuroradiology* 1994;36:625-626
21. Ikuta F, Zimmerman HM. Distribution of plaques in seventy autopsy cases of multiple sclerosis in the United States. *Neurology* 1976;2:26-28
22. Fog T. Topographic distribution of plaques in the spinal cord in multiple sclerosis. *Arch Neurol Psychiatry* 1950;63:382-414
23. Oppenheimer DR. The cervical cord in multiple sclerosis. *Neuropathol Appl Neurobiol* 1978;4:151-162
24. Thompson AJ, Kermode AG, MacManus DG, et al. Patterns of disease activity in multiple sclerosis: clinical and magnetic resonance imaging study. *BMJ* 1990;300:631-634